PLATE I

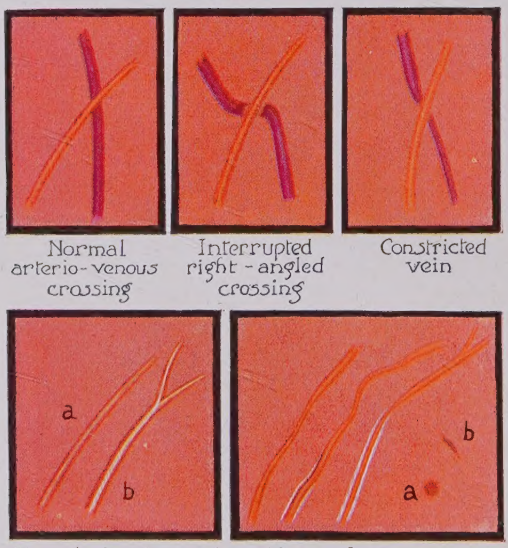

Showing typical changes in the retinal blood vessels in arteriosclerosis and hypertension. — F. E. Burch.

The

Practical Medicine Series

COMPRISING EIGHT VOLUMES ON THE YEAR'S PROGRESS IN MEDICINE AND SURGERY

Under the General Editorial Charge of

CHARLES L. MIX, A.M., M.D.

The Eye, Ear, Nose and Throat

EDITED BY

CHARLES P. SMALL, M.D.
ALBERT H. ANDREWS, M.D.
GEORGE E. SHAMBAUGH, M.D.

SERIES 1927

CHICAGO
THE YEAR BOOK PUBLISHERS
304 South Dearborn Street

COPYRIGHT 1927
BY
THE YEAR BOOK PUBLISHERS

616.21
Y39
1927

DEPARTMENTS

The Eye

CHARLES P. SMALL, M.D.

Professor in Ophthalmology, Chicago Policlinic; Collaborator, American Encyclopedia of Ophthalmology; Ex-President, Chicago Ophthalmological Society

The Ear

ALBERT H. ANDREWS, M.D.

Professor of Otology, Rhinology and Laryngology in the Chicago Policlinic Oculist and Aurist to the Chicago, Rock Island & Pacific Railway, etc.

The Nose and Throat

GEORGE E. SHAMBAUGH, M.D.

Professor of Otology, Rhinology and Laryngology, Rush Medical College of the University of Chicago; Otologist of the Presbyterian Hospital

WITH THE COLLABORATION OF

ELMER W. HAGENS, M.D.

Instructor in Otology, Rhinology and Laryngology, and Friedberg Fellow in Otolaryngology, Rush Medical College of the University of Chicago

196799

TABLE OF CONTENTS

THE EYE

Hereditary Abnormalities of the Eye 7
Diagnosis 16
Examination of the Eye 25
The Refraction of the Eye 40
The Field of Vision 57
The External Ocular Muscles 59
The Eyelids 86
The Conjunctiva and Cornea 91
Trachoma 98
The Lacrimal Apparatus 109
The Cornea 111
The Iris 118
The Crystalline Lens 121
The Retina 133
The Optic Nerve 140
The Orbit 145
The Uveal Tract 149
Glaucoma 159
Injuries and Foreign Bodies 174
Ocular Therapeutics 180
New Instruments 198

THE EAR

Hearing Tests 207
The External Ear 216
The Middle Ear 223
Mastoiditis and Intracranial Complications 244
Pathology of the Ear 268
The Internal Ear 273
Miscellaneous Conditions 285

THE NOSE AND THROAT

General Considerations 311
Diseases of the Nose 349
Nasal Accessory Sinuses 349
Atrophic Rhinitis 386
Miscellaneous Nasal Conditions 388
Diseases of the Mouth 398
Diseases of the Throat 412
The Tonsils 412
The Pharynx 444
Diseases of the Larynx and Trachea 455
Voice and Speech Disorders 472
Bronchoscopy and Esophagoscopy 486

THE EYE

Hereditary Abnormalities of the Eye

There are well recognized laws, first enunciated by Mendel a half century ago and further elaborated by workers in the last twenty years, which govern the inheritance of many characters, such as the color of hair, eyes or skin, the number of the digits, etc. These laws explain, in the majority of instances, the inheritance of diseases or defects of the eye which Madge Thurlow Macklin,[1] in a series of papers, describes. They will be summarized here, and may be most easily illustrated by a consideration of the inheritance of eye-color in the human subject.

All qualities or characters which an individual possesses, for example the color of the eyes, are due to the inheritance from *both* parents of some factor relating to that character.

Many of these characters may be classified under two headings, dominant and recessive. By dominant characters we mean those which *must be expressed* in the individual as evident traits if he or she has inherited them. Such a trait in man is the brown eye color. If a person has inherited the factor responsible for brown eye color from either parent, then that person must have brown eyes.

By recessive characters we mean those which *may or may not* be expressed as evident traits in the person who has inherited them. An example in man is blue eye color. If such recessive characters remain latent, due to their being overshadowed by the presence of a dominant character, it is impossible to tell from appearances that they have been inherited. On the other hand, they may be expressed, if they are present in

(1) Canad. M. A. J., Nov., 1926 and Jan., Mar., Apr., 1927.

double quantity, since then no dominant factor can conceal them. This condition is possible only when two recessive factors have been inherited—one from each parent.

With respect to eye color there are three types of persons: (1) those who have inherited the factor for brown eyes from both parents; (2) those who have inherited the factor for blue eyes from both parents; and (3) those who have received the factor for brown eyes from one parent and for blue eyes from the other. In the last case, blue being overshadowed by, or recessive to, brown, does not become evident, and the color of the eyes is brown.

An individual may transmit to his children either factor for eye color which he has received from his parents, but he can pass on only one of them to any one child. If both factors for eye color are identical it makes no difference which of the two is lost in the maturation of the germ cell, since the end result will be the same. If the factors are different, that is, if there are present both brown and blue producing elements, then the parent may pass on *either* the factor for brown or for blue, but *not both*, to any one child. He may transmit brown to one child and, later on, blue to another.

When the germ cells contain two factors that are identical for the production of a character, the person is spoken of as "pure" for that character, and all his children must possess that character no matter with whom he is mated. If the character in question is a dominant one, all the children will exhibit it; if it be recessive, they may possess it as a latent character, or may exhibit it. For example, the African negro is pure for brown eyes, and no pure-blooded negro, and indeed no mulatto (that is, the offspring of a pure black and a pure white person), can ever have blue eyes. On the other hand, certain races of northern Europe, as those of Scandinavia, are pure for blue eyes, and never show

brown unless there has been an intermixture with individuals having brown eyes.

When the germ cells contain two differing factors, the person is known as a "hybrid" for that character. A person may be pure for one character and hybrid for another.

Inasmuch as there are three types of persons with respect to the brown and blue eye-color, it follows that any one type might be mated with any other type, thus producing six possible varieties of mating. It must be remembered that only one factor can be transmitted by a parent at a time, and it depends upon chance which of the two factors will be transmitted. A hybrid, containing factors for brown and blue eye-color, will pass on brown as frequently as blue.

Marriage of first cousins has usually been held to be inadvisable, lest it produce defects in the children. Marriage of relatives of any degree is not in itself productive of abnormalities in the offspring unless there are recessive factors for defects in both families.

Hereditary Ptosis. Hereditary ptosis appears to be the most common of the inherited abnormalities of the eyelids—at least there are far more records of this defect than of any of the others. It is due to the absence or impairment of the muscle which normally elevates the upper lid, the levator palpebræ superioris.

From a careful consideration of a great many pedigrees, it is safe to conclude that this condition affects both sexes with the same frequency; that fathers and mothers are equally liable to pass on this defect to their offspring; and that either parent may pass it on to children of either sex.

From available statistics it is evident that ptosis does not tend to become eliminated in families, either by a lessening of severity in succeeding generations, or by fewer people becoming affected. In a family investigated by Briggs, in which the defect had lasted through

six generations over a period of 125 years, affecting sixty-four out of 128 persons, the ptosis was more severe in the sixth generation than in the fourth and fifth. That more and more are being affected according to the fecundity of the affected parents, is evident.

Lagophthalmus. Lagophthalmus, the opposite condition to ptosis, may be defined as the accentuated retraction of the upper lid, with inability completely to cover the eye, when the lids are closed. This condition is not always of the hereditary type. It may be due to loss of skin on the lids through burns, ulcers, etc., to ectropion, and exophthalmos. In the only record of hereditary lagophthalmus which is available, Peters states that the defect was caused by a congenital deficiency of the orbicularis oculi muscles, which left the levators of the lids without their normal antagonists.

Less common than ptosis, lagophthalmus is like ptosis in being inherited, and in being a dominant character. It apparently is not passed on by those who do not possess it, and it is inherited by the offspring of those who do.

Cryptophthalmus. Cryptophthalmus is the most serious of the inheritable defects of the lids. The integumentary folds forming the eyelids, arise at the end of the seventh week of intra-uterine life and fuse at the ninth week. They remain so fused until the seventh month, when they normally separate. In cryptophthalmus this separation fails to occur and the lids retain in the adult the fetal condition of closure. The line of fusion may be seen by the dimpling of the skin along the horizontal axis of the eye. The skin passes in an uninterrupted manner from the brow over the eyeball to the cheek. Lashes may or may not be present.

There is a folding of the skin at the point where the lower lid joins the cheek, which conveys the impression that the lids are merely closed. The line of dimpled skin across the middle of the eye, however,

shows the zone where upper and lower lids are fused. This woman, married to a man blinded through accident, gave birth to a child normal in every respect save that it duplicated its mother's deformity. Although an operation was performed on both mother and child the abnormal eyeball prevented even a subnormal vision. The lids were reunited and the patients continued to be blind.*

Parents who are normal and have produced one cryptophthalmic child, should have no more offspring. Cousins who are each members of families where this defect has shown itself should not marry.

Minor Defects of the Lids. Epicanthus, or the presence of a fold uniting the upper and lower lids at the inner angle of the eye, is inherited. It may be associated with other eye defects. It is the normal condition found in the Mongolian race and is responsible for the peculiar aspect of the lid slit in this people. Since it is a dominant character for which the Mongols are pure, it is inevitably present in all of their race.

Distichiasis or the presence of two rows of lashes on otherwise normal lids is inherited and is probably due to a dominant factor. *Lack of eyelashes in father* and son was reported by Traquair. *Relaxation of the lids* due to atrophy of the underlying connective tissue ran through four generations of a family, acting as a dominant character, Lafonde et Villemonde. *Fat hernia* of lids has been recorded in a mother and daughter by Schmidt-Rimpler.

Of the above defects only cryptophthalmus causes outspoken blindness, which is irremediable, plastic surgery being of no avail. Persons affected with this condition should of course refrain from having children. Ptosis and lagophthalmus may be so severe as to cause

*Since that report, two other children have been born in this family. The second, a male, showed the same condition of cryptophthalmus that was present in the mother and older sister. The third child, a male, was normal.

partial or total blindness. Operation is always needed to correct the severe cases, and it may not prove wholly satisfactory. It is impossible to predict the degree of severity of these conditions in the offspring on the basis of the amount of deformity in the parent. Hence persons suffering from the hereditary types of these defects should not reproduce. The other conditions mentioned are of importance mainly from the cosmetic point of view, and the patient may be advised regarding their hereditary character. From the standpoint of the public, however, the transmission of these minor conditions is of no importance.

Microphthalmus is the defect in which the eyeball is so small that vision is subnormal or absent. There are probably many varying degrees of this defect, ranging from an eye, slightly reduced in size, down to mere microscopic remnants of eye tissue. To this latter class belong the so-called cases of anophthalmus, or total absence of the optic globe; it having been stated that in all cases of anophthalmus, microscopic examination of the orbital contents will reveal some trace of eye tissues. Only those cases of microphthalmus, which are sufficiently extreme to cause very defective vision or blindness are brought to the attention of the ophthalmologist. Most of the milder cases probably go undiagnosed.

This defect is congenital, and probably inherited in all cases. Due, however, to its being a recessive character in some families at least, the hereditary aspect may be overlooked.

McMillan gives the history of a family, in which from healthy parents, four children affected with microphthalmus were born. Other records show the occurrence of microphthalmus in more than one child of healthy parents. On the other hand there have been some families reported in which the affliction was not transmitted by those who were free from it and in which

the affected members passed it on to some of their offspring.

We now come upon a new type of transmission, the so-called sex-linked transmission. Only the males are affected, and the parent who belongs to the affected family is in each instance the mother. Here then we have healthy mothers transmitting to their sons a defect which their own brothers showed. How can such a mode of transmission be explained, and can any formula be evolved that will show which individuals are apt to be affected?

If we understand that sex is inherited like any other quality, such as eye color, and that the female has two sex chromosomes, while the male has only one, we can, by tabulating the various matings, show how such sex-linked characters can occur.

In summing up the inheritance in microphthalmus, it may be said that a condition which is diagnosed under that name may apparently be inherited either as a recessive, a dominant, or a sex-linked recessive condition. In any case the person so afflicted should not reproduce, but it would depend upon an investigation of the family history as to the advice to be given to the brothers and sisters of the afflicted individual. Parents who have produced one microphthalmic child should of course have no more offspring.

Hydrophthalmus. A number of cases encountered are the result of injury or infection. We are considering here the congenital cases or those appearing in early childhood. It is inherited, although there are probably many cases in which the inheritance is not evident. When we attempt to analyze the mode of transmission, we find that the number of pedigrees is small and that the number of persons involved in any one pedigree is limited, so it is difficult to state with any certainty just what the mode of transmission is.

Persons afflicted with buphthalmus should not have

children and the parents of one buphthalmic child should have no more offspring. It would be well for cousins, in both of whose families this defect runs, not to marry.

Operative measures designed to relieve the condition, which is akin to glaucoma, are unfortunately not at all satisfactory. The deformity existing in the eyes, which makes the patient conspicuous, is sufficient to produce some mental perturbation, and the disease itself which means the loss of sight in one or both eyes beginning in very young children, is so tragic in its physical effects that there can be no question in the minds of the profession, at least, that reproduction should be refrained from by patients suffering from hydrophthalmus.

Glaucoma. Glaucoma in the adult, which closely simulates the condition of hydrophthalmus in the child, is also due to increased intra-ocular tension, which, if unrelieved, results in diminution of visual acuity and finally blindness. The anatomical condition which has been looked upon as responsible for glaucoma is the blocking of the outlet for the lymph drainage of the eye through the canal of Schlemm, occasioned by either an infectious process which causes the anterior part of the iris to adhere to the posterior portion of the cornea, or to an initial defect in the structure of the eyeball in which the cornea as well as the rest of the optic globe is smaller than normal. It is for the most part a disease of middle life, although there are not wanting instances in which vision began to fail from this cause at eleven years of age.

Although it is evident that some cases of glaucoma may not be inherited, there is strong support for the idea that most of the chronic and some of the acute cases of glaucoma are hereditary. Nettleship concluded that glaucoma was for the most part inherited, that it showed continuity of descent, that it was not transmitted by those who did not possess the disease, and that it showed "anticipation." By the latter is meant that the

disease tends to appear at an earlier stage in the children than it developed in the parents.

The occurrence of the inflammatory type of glaucoma is recorded by many observers, through three to five generations. Harlan published the pedigree of a family, in which the disease had descended through five generations, affecting males and females, and had been passed on by both sexes to their offspring irrespective of their sex. It was not transmitted by individuals who were free from the disease. This family began to be affected at quite an early age, so that when the affected members had reached the age of twenty they were blind.

Analysis of this pedigree shows that in this family (and same is true for practically all pedigrees of glaucoma), the disease was comparable to brown eye color in its mode of transmission, that is, the factor for the disease was dominant over the factor for normal eyes.

It is at once obvious that such a disabling condition as glaucoma should not be increased in the community. Persons in whom the glaucomatous condition arises should refrain from producing offspring if they have not yet done so, and from producing any more children, should they have offspring at the time the disease manifests itself. Smith holds that the main cause for glaucoma is too small a cornea and eyeball, and that it might be possible to determine by corneal measurements in the children of a glaucomatous parent, those members of the family who are apt to develop the disease. Should this procedure prove of prognostic value, operative measures, such as iridectomy, could be performed before the disease manifested itself. These potential glaucomatous individuals could then be warned against the producing of offspring, before they reached a marriageable age, for of course, even should the preventive measures just outlined prove efficacious, they would in no way interfere with the individual's capacity to transmit the factor for glaucoma to his offspring.

Diagnosis

Ophthalmoscopic Evidence of General Circulatory Disease. The ophthalmoscopic evidence of circulatory and renal disease is appreciated only as we learn to properly interpret the significance of the various changes found. The ophthalmoscopist associates certain fundus changes with definite general diseases—hyperpiesis, arteriosclerosis, nephritis, diabetes, hemic conditions, syphilis, or some general or focal toxic infection. They indicate to him the necessity of exhaustive physical examination of the circulatory system and eliminative organs, or search for possible sources of toxemia. The changes, according to Frank E. Burch*, fall into two main groups: (1) those which have to do almost entirely with the circulatory system, and (2) those which are manifestations of toxemia. Often one produces the other, or the same causes produce both, but the predominance of the toxic or the circulatory factor, or the order of sequence in their development, may be of the utmost clinical significance. The changes found may be too complex, of themselves, to permit exact analysis of their origin, and only occasionally may an arbitrary diagnosis be made from fundus changes alone. Practically all visible retinal pathology results from causes which manifest themselves through vascular changes. The evidence available to the internist with the retinal vessels visible under magnification of about fifteen diameters makes the ophthalmoscopic findings of especial value in patients with cardiovascular renal syndrome. Choroidal vessels share in vascular changes and may undergo even greater degree of angiosclerosis than the retinal vessels but, obviously, the evidence of choroidovascular disease is less frequently visible. The most frequent changes met with in fundus examinations have to do with hyperpiesis and arteriosclerosis.

The study of retinal evidence of hypertension has fol-

(*) Minnesota Medicine, August, 1927.

lowed the routine measurement of blood pressure as a part of physical examination but the first published case showing ophthalmoscopic evidence of hypertension was in 1892 by Marcus Gunn, before the use of instruments for recording blood pressure. Although thirty-three years have added much to his observations, in the main we must adhere to his description, which was as follows: "The arteries have an exceptionally bright reflex. The central light streak is very distinct and sharp, producing a metallic appearance like bright copper wire. This condition has been observed in chronic albuminuria and in several cases where no albumin is found, or where high tension suggested the probability of changes in the arteries, usually associated with those of chronic renal disease. The ophthalmoscopic appearance is presumably due to hyalin degeneration of the arterial wall. Attention is directed to the effect produced on the veins by arteries overlying them. Where an artery, even a small twig, passes over a retinal vein, the circulation in the latter is much impaired. In some cases the vein is indistinguishable just at the spot where it is crossed and is evidently distended for some distance peripherally from this point. The appearance is interpreted as evidence of high arterial tension." In addition to the foregoing, the picture may show evidences of toxemia, namely, cotton-wool exudates or edema of the nerve-head and neighboring retina.

In simple high blood pressure independent of other retinal evidences of toxemia or angiosclerosis, there are certain cardinal signs. The first of these is a marked increase in prominence and breadth of the arterial light reflexes, with elongation and tortuosity of the retinal vessels, especially the smallest terminals and macular twigs. Later the vessel wall becomes thickened from endoarterial proliferation and increase in the medial coat, and the arteries appear uniformly contracted, of lessened caliber, the reflex arterial light stripe is narrowed, the veins are congested, and about double the

normal size. The outstanding phenomenon is the apparent interruption in the venous circulation where the veins are overlaid by arteries at points of crossing, in the manner described by Gunn. It is now generally accepted that the hyperpiesia is arteriolar in its origin.

If, with high blood pressure, there is marked arteriosclerosis, certain further changes are evident which have very decided diagnostic and prognostic value. When high blood pressure is followed by, or follows, marked angiosclerosis, the type of the arterio-venous crossings differs from the type found in hyperpiesis. Where an artery crosses a vein, it does so by the shortest possible route and one sees a so-called right-angle crossing, with an appearance of actual interruption in its course. The vein, though meeting the artery normally at about an angle of, say, 30 degrees, and leaving it at a similar angle, passes under it at right angles to its course. A similar phenomenon may be seen when a vein crosses over a sclerosed artery. This phenomenon is attributed not only to the tightness of the vessel and its translucency, from hyaline or fibrous thickening in its wall, but also to direct mechanical effect of pressure of the sclerosed artery upon the thinner walled vein. It constitutes the most constant evidence of arteriosclerosis with hypertension. In addition one commonly observes the smaller terminal vessels surrounding the macula and near the disc having a decidedly corkscrew appearance indicative of hypertension and venous stasis.

One frequently sees marked evidence of arteriosclerosis without hypertension. The outstanding characteristic of advanced arteriosclerosis is the irregularity in caliber of the arteries. Not only is the caliber of all arteries often apparently uniformly decreased, giving rise to the appearance of contraction, but in places one frequently sees them very uneven and patchy and presenting a beaded appearance; or more commonly the narrowing of the lumen is gradual, again becomes normal, and further along the course of the vessel shows the

same phenomenon repeated. In extreme cases the lumen may become completely obliterated in places as a result of subendothelial proliferation. Such changes are indicative of quite advanced arterial change. At other times, especially in syphilis, a perivasculitis occurs, with marked evidence of thickening of the adventitia. In such cases, there is a sheath of connective tissue enveloping the arteries for some distance from the disc, after which the arteries appear to be narrowed. At other times, the vessel shows a type of "pipestem sheathing." Personal observations of arteriosclerosis in senile patients confirms the statement of Wagener and others that irregularities in caliber are sometimes less prominent in the aged. The explanation for this is probably due to the fact that senile vascular sclerosis occurs principally in the elastic coat and that changes in the middle coat are more uniform in senile atheromatous or sclerosing types; also the light reflex phenomenon is rarely so prominent unless accompanied by hypertension.

Mr. Foster Moore first described the type of angiosclerotic retinitis which is distinct from that seen in connection with renal disease. When present it is to be accepted as evidence of vascular changes of long standing. He emphasizes the distinction between this type of retinitis and that which characterizes renal disease. It is much more frequent when hypertension accompanies angiosclerosis, and is characterized by bright white spots or dots in the retina, seldom of greater diameter than the veins, with no exudate around them. Their favorite site is along the main vessels near the nerve-head, in and around the macula, or between the macula and the nerve. These spots are sharp-edged, round or oval, seldom distinct, and probably represent degenerative or nutritional changes in or near the lamina vitrea, very small patches of localized exudate, or hemorrhage in the superficial choroid or deep retinal layers. These spots may entirely disappear and new ones form. The presence of marked arteriosclerotic

retinitis is of prognostic value both as to the association with cerebral vascular lesions and duration of life. Occasionally, stellate formations around the macula or a fan-shaped figure between the disc and macula may be observed. These spots are distinctly different from the toxic changes, white wool patches or so-called snow-bank exudates, noted in renal retinitis. Stellate figures represent a sequence of macular edema and are considered by most ophthalmoscopists as evidence of interstitial nephritis, but they occur with syphilis and not infrequently with venous thrombosis and even choked disc. Undoubtedly, so-called albuminuric retinitis is, in large part, a local edema of mechanical origin. Uremia produces increased intracranial pressure and pressure in the nerve sheath. Indirectly, mechanical stasis contributes to the blood toxin factor in producing the retinal manifestations of toxemia, and it must ever be borne in mind that urea nitrogen is not the only factor, and not necessarily the principal blood toxin producing the changes we find. Other toxins, many hemic conditions, and products of perverted metabolism, may be very important causes. Nevertheless, when seen with hypertension and arteriosclerosis, with scant albumin or a few casts, we may assume we are dealing with a process in the kidney essentially of the sclerosing type, the so-called arteriosclerotic kidney, although these patients may survive many years after retinal changes are found, and die quite frequently of cardiac or cerebral complications and not with uremia.

"Malignant hypertension" is now receiving special consideration as a clinical entity in which characteristic retinal changes are fairly uniform. The disease is characterized by high diastolic pressure, without very definite renal insufficiency; there is cardiac hypertrophy with peripheral sclerosis; anemia is not marked and the kidney changes are not accompanied by albuminuria until late. One does not get laboratory reports of marked urea nitrogen retention in the blood.

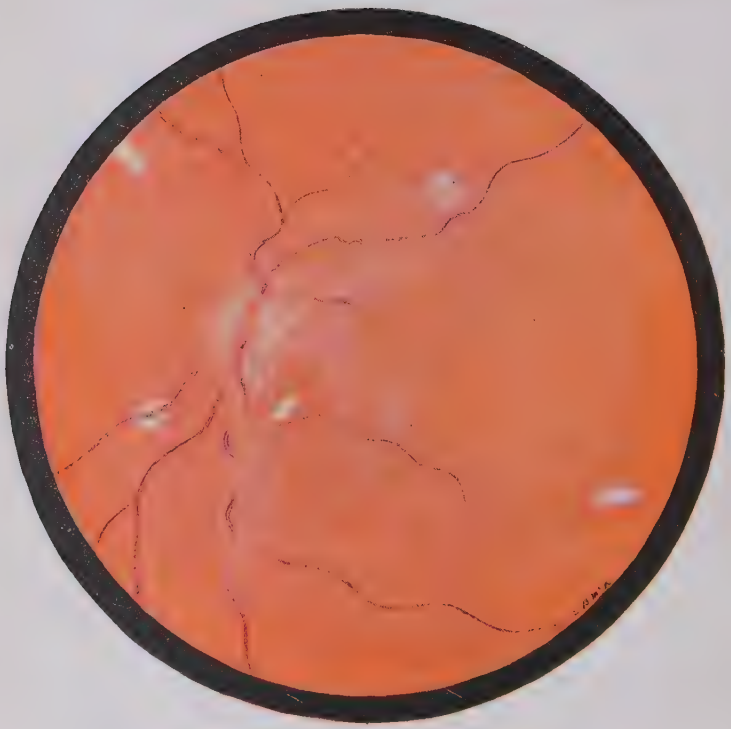

Fundus appearance in malignant hypertension.—F. E. Burch. *(Minn. Med.)*

The disease usually terminates with cerebral or cardiac complications rather than in uremic coma. According to the author's observations the retinitis of malignant hyper... ion quite uniformly presents the appearance of advanced arteriosclerosis and hypertension, combined with toxic neuroretinitis resembling that seen with toxemia of pregnancy, although the edema exudates, hemorrhages and stellate macular changes are less pronounced during early stages. The retinitis always accompanying malignant hypertension is an important part of the clinical picture, and, in conjunction with the clinical and laboratory evidences manifest, forms an important link in diagnosis. It is well illustrated in the Frontispiece from a patient who complained of slight visual impairment. The retinal evidences as shown by variation in arterial caliber, interrupted arteriovenous crossings, with areas of increased arterial light reflex, localized edema of the retina, a few exudates and hemorrhages, with optic neuritis, may be accepted as evidences of malignant hypertension, when considered with laboratory reports and physical evidences mentioned above. At the time this drawing was made the patient's blood pressure was 215/130. Neither albuminuria nor urea nitrogen retention were prominent symptoms. The ophthalmoscopic evidences of toxemia predominate although moderate hypertension and arteriosclerotic changes are present. This case was diagnosed malignant hypertension by several very good internists. (Plate I.)

Retinal hemorrhage in purely sclerotic changes represents evidence of stasis and hypertension plus degenerative changes in the vessel walls, permitting diapedesis. One does not frequently see hemorrhage in essential hypertension, without evidence of arterial degeneration. Likewise, in senile angiosclerosis without hypertension, hemorrhage is comparatively rare. Most frequently the combination of arteriosclerosis with increased intravascular tension or venous stasis results in

hemorrhages. These are commonly small, flame-shaped, and limited to the nerve fiber layer of the retina. Less frequently they are circular, petechial in type, pale in appearance, usually near the large vessels, representing extravasation into the granular layers. They may be absorbed and leave no trace, or be followed by patches of atrophy, when absorbed, or occasionally, some pigment disturbance follows. Occasionally a slight trauma may be the immediate cause of extensive hemorrhage. Subhyaloid extravasations over a very extensive area frequently follow comparatively insignificant injuries, usually have their site at the macula, often becoming absorbed without leaving a trace, or with very little pigment disturbance.

One occasionally finds an unusual condition of marked tortuosity of the retinal veins, extending even to the smaller branches. In contrast to the tortuosity of the veins is the exceeding straightness of the arteries. The condition indicates venous stasis, either from local causes in the orbit or from general causes, or the condition may be purely mechanical from anatomical or orbital pressure, the physical findings revealing no general systemic or organic disease. In patients with patent foramen ovale or pulmonary stenosis, one frequently sees a cyanotic fundus with markedly dilated and tortuous retinal vessels, especially the veins. The retinal arteries are much darker than normal and somewhat resemble the veins in color. A similar condition occurs in erythremia, although in this condition the arteries are not much affected. In severe cases the veins are extremely cyanotic and tortuous, the cyanosis probably due to insufficient oxidation as well as stasis. In marked aortic regurgitation distinct pulsation of arteries is commonly observed.

All evidences of circulatory disease are not manifested by hyperplastic or degenerative changes in the vessels. Not uncommonly a patient in middle life presents himself for examination with a history of sud-

den blindness caused by embolism of the central retinal artery. Ophthalmoscopically, one finds a complete obstruction of the central retinal artery, or one of its branches, evidenced by great reduction in the size of the vessels, usually a localized edema of the macula and a marked retinal anemia. The arteries may appear reduced to mere threads and the smaller ones invisible. Usually, the nerve atrophies and blindness is permanent unless immediate restoration of the circulation is established. The case may be one of mitral disease, the blindness caused by separation of detached valvular vegetation finding lodgment in the retinal artery. Most cases diagnosed as embolism of the retinal artery are really due to thrombus formation in which the lumen of the vessel, already narrowed from proliferation of its endothelium, has become suddenly occluded. It should be borne in mind that a single branch artery may frequently show ophthalmoscopic evidence of obliterating endarteritis.

Thrombosis of the central retinal vein or of one of its branches is not very infrequent and almost invariably caused by pressure of a sclerosed and thickened artery upon the vein. This may occur either where the vein enters the optic disc or where a branch vein is crossed by an artery. The thrombus produces venous stasis resulting in extensive homorrhage which may completely obscure the nerve-head, leading to confusion with monolateral choked disc, when the central vein is compressed. In the case of involvement of a venous branch, most frequently the right superior temporal, the resulting hemorrhagic extravasation is localized around the particular branch involved. Newly formed blood vessels may re-establish circulation around venous obstruction of a branch vessel and vision may not be too seriously damaged, but acute glaucoma is a possible complication of every thrombus of the central vein, disastrous in its damage to vision if not to the eyeball itself.

From the prognostic standpoint the ophthalmoscope reveals distinct evidence bearing upon the type and stage of circulatory disease. In connection with retinal angiosclerosis as an index of the condition of the cerebral vessels, Knapp states that marked changes in the retinal vessels indicate a similar state in the cerebral vessels, but not the reverse. Moore, in a series of sixty-six patients, found that 44 per cent developed cerebral hemorrhage or thrombosis, hemiplegia or monoplegia, within seven years of the period when marked evidence of retinal sclerosis and hypertension was first noted. Likewise, in a series of cases with cerebral lesions of vascular origin, retinal evidence of angiosclerosis was present in 70 per cent of them. In the absence of albuminuria especially, the retinal vessels present a fairly good index of the state of the cerebral vessels in patients past middle life.

It is necessary to emphasize the essentially different type of changes seen in arteriosclerosis and hypertension from those which distinctly characterize renal retinitis. In albuminuric or renal retinitis, the characteristic evidences of break in renal function are edema of the nervehead, or edema in the retina around the disc or macula, with soft woolly patches and hemorrhages which are often diffuse, or border the patches of exudate. When albumin and casts are present, it usually represents parenchymatous nephritis.

The ophthalmoscopic picture is very frequently a most complicated one with all the signs of toxemia superadded to those of angiosclerosis plus hypertension. No single feature or change found with the ophthalmoscope has great diagnostic value considered *alone*. When several signs are present, and considered with the other physical findings, they contribute information of value, both in diagnosis and prognosis. When evidence of beginning retinal angiosclerosis is present in a person in middle life, especially also if the evidence of increased intravascular tension is marked, we may be able to seek

for causative factors and remove them at a time when preventive measures may do some good. It is not always possible to diagnose types of cardiac or renal disease, syphilis, or intracranial lesions by fundus examination alone, without the aid of the internist, the neurologist and the laboratory, but the ophthalmoscope very frequently affords information of value in estimating the extent to which the disease has progressed. For this reason, it is of utmost importance that we be able to recognize, properly interpret and evaluate the vascular changes visible with the ophthalmoscope.

Examination of the Eye

Periodical Eye Examinations.— Twenty-five years ago there were no life extension institutes, although at that time physicians, as always, were trying wholeheartedly to prevent illness and infirmities. The life extension institutes make a special point of periodical examinations including the special features, but they reach only a small portion of the population.

The layman hardly realizes the changes which may occur in the eyes due to disease in other parts of the body. The general practitioner is beginning to appreciate the aid of the periodical eye examination, but as yet does not take advantage, to the full extent, of the readings of this marvelous barometer. He perhaps does not appreciate the fact that with the assistance of the trained oculist, his knowledge of the case in hand might be clarified and the confidence of the patient increased.

The dentist advises examination every six months because he has found that changes occur in the teeth so rapidly. The eyes are less likely to have such rapid changes and unless something definite, as progressive myopia, dimming vision or pain is noted, W. Holbrook Lowell[2] thinks two years a safe period between examina-

(2) M. J. and Rec., Apr. 6, 1927.

tions. This observer goes on to say, that the average person is apt to look upon the oculist as merely a fitter of glasses and does not know that a careful internal and external examination of the eye is included. He does not appreciate the fact that many diseases attacking the body are often early seen in the eyes and amelioration of the trouble or even cure can be effected if early discovery is made. The index of refraction often changes in two years thus necessitating change of glasses.

It is not unusual to have refraction errors change even in a year's time. Alterations in the diameter of the eyeball due to excessive near work in a young person or even an older person in depleted condition may bring on nearsightedness. Changes in the curvature of the cornea and even in the convexity of the lenses may cause a change in astigmatism either in strength or axis.

Changes in the density of the refractive media may also require a definite change in the strength of the lenses due to the result of disease, changed conditions of the body, local or general. These changes take place in the lens, aqueous or vitreous, and alter the density and therefore the index of refraction. The socalled "second sight" in elderly people, which allows them to read without glasses, simply means beginning cataract, later followed by opacities of the lens and blurring vision.

We get increased density of the aqueous in inflammations of the iris and symptoms of myopia when glaucoma is beginning.

In diabetes, Wescott and Ellis found the refraction either increases or diminishes, usually the latter. The cause is not known but the change will disappear as the sugar disappears from the urine.

E. C. Ellett reports a case of myopia after the use of quinine internally. The quinine was found present in the aqueous, not enough to change the index of refraction but enough to stimulate the ciliary muscle and

thus produce the apparent myopia by spasm of the muscle.

We get increased density of the aqueous in muscular action as in spasm of accommodation which often occurs in children and always requires the use of a cycloplegic such as atropin or homatropin before an accurate measure of the refraction can be made.

Changes in refraction may occur assignable to no known cause. Changes occur even when the proper glasses have been given. Inflammation of the conjunctiva has often been found due to eyestrain from the lack of glasses to correct it, and disappears very shortly after putting on the proper glasses. Again and again, nausea and vertigo have been cured by proper glasses. Such patients have learned that when these symptoms reoccur it means they need a change of glasses and they promptly attend to it.

In considering these symptoms of eye troubles, the patient's general condition must not be lost sight of, and for this reason it is most important that their own doctor, in referring them, should give a careful report of his findings in the case. Unfortunately, he does not always do this and expects the specialist to know, by intuition, about the patient's blood pressure, blood count, hemoglobin, uranalysis, etc. Only by a wholehearted cooperation can the patient be best served. Very often an ocular finding and suggestion will materially aid the general practitioner in his treatment of the body infirmity.

Ocular palsies have many different causes, the most frequent being lues and cerebral hemorrhage. Only lately, encephalitis lethargica has been recognized as a cause. Sinus and ear diseases are another frequent cause, also disseminated sclerosis, cerebral tumors, trauma and postdiphtheritic neuritis.

Argyll Robertson pupil is most often found in tabes. It is also found in disseminated sclerosis, syringomyelia, endemic encephalitis and cerebral tumors (of the third

ventrical, aqueduct of Sylvius or anterior part of the corpora quadrigemina). Patients with chronic alcoholism and trauma also sometimes show an Argyll Robertson pupil.

During the routine examination of the eyes, arteriosclerosis is often first discovered. This condition is most often seen between the ages of forty and sixty years, when a patient consults an oculist because of failing sight which usually comes with age.

Of subjective symptoms in arteriosclerosis there is not much to be said for they are few in number and not often present. Sometimes, however, the patient complains of a transitory dimming of vision in one or both eyes. Letters seem out of line and the middle letter of a word is blurred or absent. This is due to partial central scotoma which is probably caused by the toxins in the blood and spasm of the diseased vessels.

A very early sign of arteriosclerosis is manifested by a slight filmy appearance of the macular and possibly tiny tortuous or corkscrew vessels near it with a few macular dots. Another early sign is a definite bulging of the vein at the distal end beyond where the artery crosses it and lack of transparency of the artery so that the vein cannot be seen through it. These conditions are almost invariably accompanied by raised blood pressure shown by the sphygmomanometer. Early recognition of this condition with immediate treatment often results in a lessening of the signs and the patient may be kept from cerebral apoplexy.

It can easily be deduced from the foregoing data that periodical examinations may be of the greatest value and aid in keeping the patient in good health.

Bulson, who based his observations on an analysis of one hundred consecutive cases, finds that "approximately eighty-seven per cent of all cases of endogenous iritis are due to three causes, namely, syphilis, about thirty-three and one third per cent; dental infections,

approximately thirty-three and one third per cent; and tonsillar infections, about twenty per cent. Of the cases of endogenous iritis not due to syphilis, dental infections, and tonsillar infections, numbering less than thirteen per cent, the causative factor is gonorrhea, focal infections in the accessory sinuses, or less commonly in some other portion of the body, and toxemia that often may not be traced definitely.'' The author would add tuberculosis, which should not be overlooked, as another cause of endogenous iritis.

Another reason for periodical examination of the eyes, especially after forty years of age, is because of that frequent and insidious blinding eye disease, chronic glaucoma. It is most often the cause of blindness in middle life. If taken in time, medical or operative measures may stop the progress of the disease and the patient keep useful sight for the rest of his life.

Nephritis and diabetes are often first discovered during routine examination by the trained ophthalmologist. Sometimes before any evidence is found in the urine, a beginning nephritis will manifest itself by blurring of the disc, small hemorrhages and exudate around the macular, and the patient complaining of diminished vision.

We must not forget the subject of fields, the taking of which is a most important part of an examination and often gives us data which can be arrived at in no other way. Bitemporal hemionopsia is found where pituitary tumor is present at the chiasm. We find homonomous hemianopsia in cases in which the right or left field in both eyes is lost due to hemorrhage, tumor, abscess or some other form of pressure exerted on the optic tract posterior to the chiasm.

Emphasis is laid upon the necessity of closer co-operation between consulter and consultant.

Upon this same subject of routine examination of the eyes, some very helpful suggestions are offered by Miss

Ida Mann[3], who implies that such investigation could easily be made by the general practitioner.

The tests suggested are: examination of the position and condition of the eyes and lids with the patient looking straight forward; examination of the movements of the eyes and upper lids when the patient followed a moving finger, the head being kept still; examination of the pupil reactions; rough test of the fields of vision with the hand; examination of the media of the eye and the fundus with an electrical ophthalmoscope, which would reveal the presence of opacities of the media and disease of the fundus without a mydriatic in most cases, though fuller examination might be necessary in order to establish the diagnosis. The electrical ophthalmoscope, being easier to use than the non-luminous instrument, should be in the possession of every general practitioner. The patient's visual acuity with each eye should be tested separately without glasses for distance and near vision; Snellen's and Jaeger's test types were the best for this purpose.

Such a routine examination would in a large number of cases be found to afford most valuable assistance to diagnosis. In some instances it might even establish the diagnosis, as when it revealed, in a patient complaining of shooting pains in the legs, the presence of an Argyll Robertson pupil; in other cases it would often indicate a fruitful line of investigation and treatment. Some patients complained of ocular symptoms only, others with symptoms elsewhere made no mention of their eyes. In some of the latter cases a direct question would elicit an admission of ocular symptoms, but in others, and these usually the more serious, the patient was quite unaware of the presence of any eye disease. In both groups an ophthalmic examination was equally imperative. In a certain number of cases, as for example, in errors of refraction, the ocular condition sufficiently accounted for the symptoms. Headache, not necessarily frontal,

(3) Brit. M. J., Dec. 4, 1926.

and often worse in the morning than at night, was a frequent accompaniment of error of refraction; it might be associated with depression, lack of concentration, fatigue, anxiety, and even, in some cases, nausea and dyspepsia.

Suitable glasses would benefit a hypermetropic clerical worker more than a month's holiday, and might often avert a definite breakdown; this was especially true in women between 45 and 50, at which age, unless she was myopic, the average woman would begin to suffer from eyestrain after close work. This onset of presbyopia was physiological, and, if corrected by glasses, not painful. If neglected, it could give rise to a very severe headache, which, coming at a time of life when most women had been taught to expect a certain amount of discomfort, was often put down by them and their doctor to the climacteric, though inquiry would reveal that their periods were regular. Proper glasses for work would entirely remove the symptoms. It was much too common a practice to refer every pain in a woman of 46 to menstrual disorder, though evidence was accumulating to show that the menopause occurred on the average nearer 50 than 46. Men were, in the author's experience, much less tolerant of this presbyopic headache than women, and usually sought relief for it earlier.

Much more important, however, than the detection of errors of refraction was the early diagnosis of glaucoma. Though not actually a matter for the general practitioner, since it demanded experience and a certain amount of elaborate apparatus, the disease could at least be suspected. It was accompanied by attacks of headache, transient blurring of vision, and, occasionally, nausea; the central visual acuity might remain good almost up to the onset of blindness. The acute form of glaucoma was most often overlooked by practitioners who did not perform routine examinations of the eyes.

The author mentioned the danger of injecting atropin before operation in a subject of chronic glaucoma, and

quoted six cases treated for gastric influenza, intestinal colic, food poisoning and other troubles, before advice was sought for the ocular condition. In two cases the congestion of the eye was noticed by the doctor, who proposed to treat it when the patient was better, not realizing that the vomiting and collapse for which advice was sought could have been relieved immediately by a posterior sclerotomy, and the sight of the eye (which was in each case lost) probably saved.

In other cases, the headache or other symptom for which advice was sought was a manifestation of a general disease having ocular signs; in these cases examination of the fundus was of much assistance in diagnosis. All cases of headache and vomiting required a fundus examination; a papillo-edema would be found in same, and the diagnosis of cerebral tumour could be made before the onset of optic atrophy. In other cases the presence of disease of the retinal vessels, exudates, hemorrhages, patches of choroiditis, and other abnormalities would supply a diagnosis, or at any rate indicate a line of investigation, at an early stage. It was surprising how often the initial diagnosis of diabetes, albuminuria, arterio-sclerosis, and syphilis was made in the eye department of a general hospital. In disease of the central nervous system an ocular examination was preeminently of help, but a very large number of systemic and general diseases had ocular signs, and diseases so far removed from the eyes as apical phthisis and carcinoma of the pancreas might be suspected from an ophthalmic examination alone.

Slit-Lamp Ophthalmoscopy[4]. The introduction of the direct examination of the eye by means of an efficient microscope and the slit-lamp has given the ophthalmic surgeon a most refined and beautiful additional mode of extending the field of his investigations. For those to whom the method is known by name, but to whom its basis is mysterious, a reference to an observation which

(4) Brit. M. J., May 14, 1927. (Review.)

most children make, with wonder, will provide a sufficient explanation. Who has not seen a narrow ray of sunlight coming through the shutters of a closed window, and seen that the air was full of moving particles brilliant in the sun-ray? That in essence is slit-lamp examination of the eye. By means of an appropriate projection apparatus, the device of Gullstrand, a thin ray of light can be focused upon and made to cut into the eye; and the illuminated section which this ray makes against the rest of the dark and unilluminated eyeball can be examined with a binocular microscope almost as though that section were on the stage of the microscope. This mode of investigating pathological processes of the living eye, particlarly in the cornea, iris, and lens, has been much exploited in the last few years.

There has just been issued a work by Harrison Butler of Birmingham, a valuable and most complete *Illustrated Guide to the Slit-Lamp* as applied to disease conditions in the eye.

The use of the slit-lamp has brought no revolution to the methods or theories of ophthalmology; it has done nothing for medicine so amazing as did the introduction of the ophthalmoscope; nor has it changed the work of the ophthalmologist as did the discovery of the objective method of investigating the refraction of the eye by retinoscopy. It is a refinement upon existing methods. Focal illumination has been employed as long as the eye has been subject to examination; magnifying lenses were used so soon as they were made available; and the use of the condensing lens and the hand loupe will never be superseded. But the fine ray of light of the slit-lamp and the binocular microscope give an image of such detail and of such size that the new combination is as superior to the hand lens and glass as is a good oil-immersion objective with a well focused substage condenser better than an old-fashioned triplet objective.

In certain conditions the slit-lamp is of great value in diagnosis. To determine the existence of interstitial

keratitis is not always easy by the usual methods; but with the slit-lamp there is a picture so typical that it cannot be mistaken for anything else. The infiltration of the cornea is seen to be fundamentally associated with the posterior layers of the corneal stroma; and though, when the inflammation is at its height, the more anterior zones may participate in the process, yet this is secondary to the main focus in front of Descemet's membrane. The great thickening of the cornea is also notable. The appearance presents a marked difference from keratitis of the phlyctenular type.

But the slit-lamp's value is even greater in the diagnosis of sympathetic ophthalmitis, which causes the greatest anxiety to the ophthalmic surgeon. A characteristic sign, shared with other forms of severe cyclitis, is the presence of cells in the vitreous, the retrolental space, and the aqueous. Later, keratitis punctata and nodular iritis appear. If in an injured eye there be some inflammation but no signs of cells in these parts, it is improbable that there is sympathetic disease. If, with other clinical signs, a cellular infiltration be evident, the eye is likely to be dangerous. Finally, if there be similar cells in the other eye, then the eye is sympathizing, and treatment is urgent.

Photography Of the Fundus. The fundus of the human eye has been successfully photographed for many years. To do this with ease and a certainty of success, is a very recent advancement. Because of this, ophthalmology is entering a new era, in which photographing the fundus may be put to practical daily usefulness and clinical application.

In 1922, Nordenson exhibited photographs he had taken of the fundus. Since then the camera has been simplified until we now have available a practically fool-proof apparatus. With it, one can photograph the fundus almost as easily as the taking of a snap-shot. The magnification is about 3½ x linear, depending on

the refraction. The time of exposure averages one-half second.

Von der Heydt[5] presents the accompanying photographs (Fig. 1), the first fundus pictures taken in this country. The two central spots seen in the picture are the unavoidable reflections of the micro-arc carbons.

Fig. 1.—Photograph of ocular fundus, showing reflexes due to retinal folds. The white figure-of-eight, near the center, is the double reflex of the light source, from the surfaces of the lens of the camera.

The detail of interest can be so placed as to avoid this central area. Dilatation of the pupil and clear media are necessary. Very transparent anterior retinal layers, as we have them in youth, favor the distinctiveness of retinal detail. The author has made exposures successfully in the presence of nystagmus.

(5) Trs. Amer. Acad. Ophth. and Oto-Laryn., 1926.

Stereophotography Of the Anterior Eyeball. The value of stereophotography as a means of permanent clinical record and teaching ophthalmology is well recognized. Especially valuable is the ability to photo-

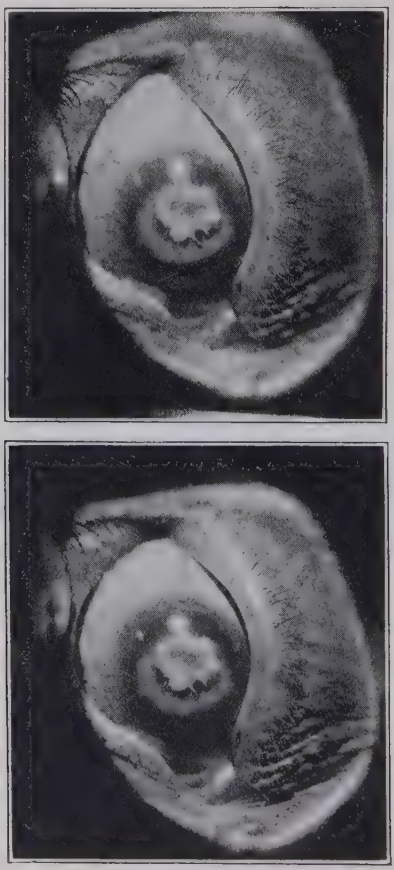

Fig. 2.—Stereophotography of the anterior eyeball.

graph minute pathologic conditions of the anterior eyeball under magnification. Stereopictures have been available for many years. They were, however, produced

under great difficulty. To obtain them was a matter of not a little expense as well as painstaking effort on the part of the pioneers in this field. The addition of an independent focusing miscroscope tube to the stereo-camera has greatly simplified this art. With this device, Von der Heydt[6] now makes perfect exposures. (Fig. 2.)

For illumination, he employs the 5 ampere micro-arc lamp such as is used for fundus examination with red-free light. After focusing with this filter, it is removed during the period of exposure. The large aspheric aplanatic ophthalmoscope lens which is part of the simplified Gullstrand binocular ophthalmoscope is used for focusing the beam. The latter is adjusted so that the focal diameter of the beam is about 35 mm. This illuminates the eye with sufficient evenness. The accompanying photographs were taken in this manner.

Diagnosis. The eye holds within its small compass more possible diagnostic information than can be obtained from any other region of the body. Every diagnostician should equip himself with a binocular loupe and an ophthalmoscope, and perfect himself in their uses. The following morbid conditions seen in the eyes, are pointed out by W. A. Boyce[7] as serving to illustrate how the eye may be an indicator of the general health.

A blepharitis, stys, chalazions, or a chronic catarrhal conjunctivitis frequently denote eye strain, which may be responsible for many nervous and reflex symptoms as well as headaches.

Unusually soft eyeballs occur in diabetic coma. Puffiness of the lids suggests nephritis, trichinosis, or arsenic poisoning. Bilateral exophthalmos is a cardinal symptom of Graves' disease. A protrusion of one eye suggests a cavernous sinus thrombosis or a breaking through of an ethmoid or a frontal sinus. Jaundice of the sclera suggests a common duct obstruction.

(6) Trs. Sect. Opth., A. M. A., 1927 Session.
(7) California and West. Med., March, 1927.

Diplopia, except in rare instances, is due to a paresis or a paralysis of one of the muscles that rotate the eye: this paresis or paralysis may involve a single muscle or a group. The sixth nerve supplying the external rectus is the most frequently involved, but the third is frequently involved also, producing a ptosis or a ptosis and a paralysis of all muscles supplied by it. The most frequent cause of these nerve involvements is syphilis or an intercranial hemorrhage. A toxemia will sometimes produce a temporary paresis of one of these muscles.

Scars of the cornea, aside from those produced by traumatism, should be investigated. Scarring from an old interstitial keratitis is due to congenital syphilis. Those due to phlyctenulosis were probably caused by an active tuberculosis in childhood.

The pupil gives us a lot of information. Contraction is brought about by the sphincter iridis; dilatation by the sympathetic. Morphin causes a contraction, while cocain poisoning, shock, fainting, causes a dilatation. Inequality of the pupils is a sign to be seriously considered. While the pupils may be congenitally unequal, it is not safe to assume this to be the explanation. Many causes of neurosyphilis produce an anisocoria as the only evidence of abnormality. The well-known Argyll-Robertson pupil needs no comment.

In the use of the ophthalmoscope, always use one drop of a 2 per cent homatropin solution to dilate the pupil. There is no use in trying to look into a room through a keyhole when you can open the door. When the examination is finished, counteract the effects of the homatropin with a ¼ per cent eserin.

In examining the fundus, first learn the appearance of the normal fundus. The physician will be most interested in determining a choked disc, arteriosclerosis, hemorrhages of the retina, embolism of the vessels and optic atrophy as well as cupping of the disc such as occurs in glaucoma.

Any modern textbook of ophthalmology contains cuts of the different diseases of the fundus, and by getting a mental picture of any given condition it is comparatively easy to make a diagnosis in the well pronounced lesions, leaving the finer points in the diagnosis to the oculist.

[A 1% solution of euphthalmin is preferred by many for fundus examination instead of homatropin, because of the very slight cycloplegic effect of the former preparation, as well as its more transient mydriatic action.—Ed.]

Loewi's Mydriatic Test for Acute Pancreatitis. In discussing the clinical aspects of acute pancreatitis Bailey[8] directs attention to the employment of adrenalin 1:1000 solution as a diagnostic test for this condition. The pupils of both eyes are first examined to eliminate the possibility of irregularities. Four drops of fresh adrenalin solution 1:1000 are then dropped into the conjunctival sac of one eye, the other eye serving as a control. After five minutes four more drops are instilled into the same eye, and in half an hour the relative size of the two pupils is compared. If the patient has acute pancreatitis, there will often be a marked and sometimes oval or eccentric mydriasis in the eye treated with adrenalin. If, on the other hand, the individual is normal, no such reaction occurs.

Hypothetically, the association of this phenomenon with acute pancreatitis is thought to arise from a hypersensitization of the autonomic nervous system due to the pancreatic involvement and the consequent increase of tone in the pupilary musculature which results indirectly from increased irritability in the sympathetic supply to the eye.

[If further experimentation proves this to be a reliable diagnostic test for acute pancreatitis, its value will be appreciated by clinicians.—Ed.]

(8) Brit. M. J., Feb. 26, 1927.

The Refraction of the Eye

The Psychology of Refraction. The psychologic aspect of refraction brings us into a very intimate relationship with our patient, since our findings profoundly affect his mental and physical being, prolonged through all his waking hours, constantly reminding him of us, favorably or otherwise. There is little in ophthalmology, according to J. F. Edwards[9], which has a more penetrating attack upon the mind of our patient than whether or not we furnish him a satisfactory, agreeable pair of glasses.

Our patients appear before us in all sorts of mental conditions—anxious, morbid, worried, neurotic, exalted, hurried, overworked, tired, doubting, timid, confident and always expectant. We have to meet all of these situations without hesistancy, without failure of tact and always with skill. Surely this is no mean task; and the demand upon us is very great. It is doubtful if many of us give this aspect of our daily medical work in optics any particular consideration; we accept it as a matter of course, routinely, consequently we often blunder in our handling of patients through lack of clear appreciation of the delicacy of our position.

Unless we shall have acquired, or are so fortunate as to have naturally an attitude of impressiveness of our ability to cope with the problems of our patients, we shall be greatly handicapped and limited in the effectiveness of our labors. Much of our work consists in being able to enforce obedience upon our patient when out of our presence, and unless we thoroughly impress such patient with the thought that he is expected to give us unquestioning belief and obedience, we shall surely fail to obtain his full co-operation. Irritable and morbid persons, in particular, will be deeply impressed with our personal radiation of atmosphere, and this may be favorable or the reverse. If unfavorable, the patient

(9) California and West. Med., January, 1927.

immediately builds up a defensive and antagonistic mental attitude which is difficult to change. This influence may reach into the subjective mind, and serve as an incentive for future acts. It is very unwise to ignore such a state, and we should be keenly alert to perceive its existence. If we fail to note this our results may be rendered negative, even erroneous, despite all our skill supplemented by modern aids to objective refraction. Patients who accept our optical prescription with a doubt of its value are demonstrations of such a mental condition. This attitude is seen now and then among elderly people whose life experiences may have been of such nature as to curdle the milk of human kindness to some degree. The frequent and natural outcome of this complex is that the unconvinced, doubting patient is quite likely to pass out of our purview and to become even actively antagonistic to us. Certainly it is highly improbable that there will ever come a time when we shall be able to eliminate entirely the co-operation of the patient in fitting optical aids to human vision.

It is credent that much of the impressiveness of well-established and famous oculists is imparted by their fine offices, trim assistants, the air of complete capability, reinforced by the circumambient atmosphere of ability to correct perfectly their patients' ailments.

That all oculists do not believe that elaborate and perhaps intentionally showy equipment is indispensable is evidenced by the fact that Jackson, in discussing the necessity for ophthalmologists to equip themselves with the very expensive slit lamp corneal microscope, alleges that simple equipment is entirely adequate if well supplemented by skilled use, akin to the famous painter who mixed his pigments with brains.

The lack of a personality pleasing to patients is a liability calculated to jeopardize their confidence and co-operation. This is especially important for oculists, who often must require patients to remain under ob-

servation and treatment for months or years. And while the attitude of dominant positiveness may, like anything else, be overdone, it produces less undesirable effects upon patients than manifest indecision in statements to them.

Obviously, we should formulate our diagnoses with all care and study, taking sufficient time in which to do this, employing every modern aid to accuracy of findings, and when our work shall have been completed it becomes incumbent upon us to furnish the patient a definite statement of conclusions. The old habit of some physicians of being mysterious—sometimes, alas, a cloak for ignorance—has largely fallen into disuse. It probably is ill-advised always to furnish *all* the information obtained, but our patient deserves a reasonable amount of information as to his condition. We often hear the remark, "Well, what did your doctor say is the matter with you?" "Why, he didn't say anything," with an air of disappointment. There is no excuse for overlooking this if we will but assume the position of the patient. Furthermore, while our statements should be given with due weight and convincement, they also should be made with due regard to the possible consequences of inflicting a mental shock upon sensitive patients. It is usually better to disclose delicate information to relatives or friends who may be able to transmit all that is advisable, without unjustified concealment of conditions requiring attention.

Many times our best efforts to obtain accurate ocular measurements are nullified by lack of attention on the part of the patient. This is particularly so in the young. It requires much patience and tact to serve an active small boy, and particularly so when accompanied by the loving mother who has made such a complete job of spoiling him. At such times it will often be found expedient to send the parent out of the room, then in a darkened refraction room, with extraneous sights and sounds eliminated, the vacillating attention of the child

may be secured by interesting him in the various small lights and mirrors in common use, and thereby promote his essential co-operation. And occasionally such a course of procedure may be advisable with adults, especially with those of low sensory threshold.

Anxiety or a strong element of subconscious doubt, even in intelligent persons, may induce a state of negation which operates greatly to impair and retard the best of efforts for the patient's benefit. An essential factor in handling this class of patients is a steadfast and insistent endeavor to remove the impelling cause of such doubts and fears. Often a lack of manual dexterity militates against a good impression, as does any undue roughness in handling the patient.

Apathy of greater or less degree is annoying at times. This may be due to mental preoccupation or impaired intelligence. This condition gives rise to erroneous replies to our questions, and may result in serious errors on our part. This remark particularly applies to refraction without a cycloplegic, due to the forward projection at such times of the objective mind in dominance of the subjective. Patients often apply for help with their minds surcharged with business worries or weighty home cares, which make them poor subjects for refraction unless their full co-operation and interest are secured. Fuchs makes the following pertinent statement:

"Patients who are mentally depressed or mentally backward and patients who are nervous and supersensitive require special care in examination and special attention in treatment. The relief of their eye conditions may be an essential element in their improvement, and we must give our best efforts to secure good results in this regard. At the same time in our zeal to correct the eyes we must not forget the individual and his idiosyncrasies nor the fact that the correction of his other physical and nervous elements claim equal attention with his ocular treatment."

Lenses should undergo our own inspection and veri-

fication prior to delivery. Even a slight displacement of the axis of a cylindrical lens, especially easy in these days of round lenses, will often render glasses highly irritant and result in a dissatisfied patient, for which the oculist may be blamed.

It is a mistake to attempt refraction on patients muddled by alcohol or drugs.

A part of the author's refraction outfit consists of a black background white letter standard chart, devised by James Thorington of Philadelphia which is lighted by a 200-watt daylight lamp contained in a large silvered reflector located about seven feet above the floor and the same distance toward the patient, who sits at twenty feet from the chart. Most eye charts are much overlighted, irritating the eyes of the patient, producing considerable retinal fatigue, and causing the maintenance of attention to be a difficult matter.

[The importance of a correct test chart cannot be too greatly emphasized. The majority of oculists prefer black letters on a dull white background. It is especially important that the entire chart be equally and uniformly illuminated, and that no light reflexes are thrown upon the surface.—Ed.]

Refractive Changes. It is well known to every one interested in the subject that changes occur in the refraction of the eye under a variety of circumstances. Some of these changes are well known and readily explained; some are rare and of a nature that is not easily understood and for which an explanation is not so readily found. At any rate it should not be a matter of surprise when we find, on examining eyes at an interval of a year or more, that a considerable change has occurred in the refraction, with the appearance of new symptoms of eyestrain or the reappearance of old symptoms, with or without an impairment of vision, all of which are remedied by suitable changes in the glasses, as pointed out by E. C. Ellett[1].

(1) J. A. M. A., Oct. 30, 1926.

The conditions that may bring about a change in the refraction of an eye arrange themselves quite definitely in one of several groups.

(*a*) Alterations in the diameter of the eyeball, especially the anteroposterior diameter, the so-called axial changes, which have the effect of altering the focus of the dioptric system in its relation to the position of the retina, and changing the amount of hyperopia or myopia.

(*b*) Changes in the curvature of the surface of the refractive media, especially the anterior surface of the crystalline lens, producing changes in the astigmatism.

(*c*) Changes in the density (index of refraction) of the refractive media, especially the aqueous humor and crystalline lens. These changes occur under a great variety of circumstances as the result of disease, local or general, and possibly from the absorption of certain drugs or other substances by the media.

(*d*) Changes in the refraction which may occur as the result of muscular action, the commonest example of which is the increased refraction under the influence of accommodation. This change may be voluntary or involuntary, and the latter is often of reflex origin.

(*e*) Cases which are not included in the foregoing groups or which represent a combined type.

The method of estimating the refraction in the cases reported has usually been by the use of an efficient cycloplegic, atropin, scopolamin or homatropin, unless the age of the patient made it appear that the accommodation was no longer to be taken into account. In some instances, for various reasons, a cycloplegic was not employed, but in such cases the circumstances did not appear to demand it. Suffice it to say that the results which were recorded seemed to be a trustworthy measurement of the refraction of the eye.

In no case did any abnormal or pathologic condition exist except as mentioned in the records.

Changes in the anteroposterior diameter of the eye-

ball (axial changes) are almost always in the direction of increasing the refraction (shortening the focal distance) of the dioptric system, to the effect that myopia becomes increased or hyperopia lessened, even to the point of passing into myopia. It is generally believed that this change is simply a question of elongation of the eye. All babies are said to be hyperopic. The eye of a baby is very short and would be very hyperopic, considered from the point of view of the length of the eyeball, were it not for the highly curved and therefore more refractive lens, which counteracts the axial hyperopia. Nevertheless, a hyperopia of about 4 diopters remains at birth, and this tends to grow less until about the sixteenth year, or the time the child has attained its full growth. From that age on refractive changes, especially an increase in myopia, cannot be regarded as an innocent or physiologic process, particularly when we consider the well known fact that continued stretching of the ocular tissues as the result of enlargement of the eyeball, and other factors of a not so purely mechanical nature, result in degenerative changes in the choroid and retina that have a very disastrous effect on the sight.

The lessening of hyperopia in a young person is illustrated in the following case:

Case 1.—Age, 12.

1900: R. + 1.75 + 1.00 ax. 90; L. + 2.25 + 1.00 ax. 90. Scopolamin.

1901: R. + 3.00 + 1.00 ax. 90; L. + 3.00 + 1.00 ax. 90.

1921: R. + .75 ax. 90; L. + .75 ax. 90.

[The author describes several cases here, as in the remainder of the article, but for lack of space, only one case is reported, which serves to illustrate the point he makes.—Ed.]

In cases such as these, the question of treatment is usually a matter of wearing proper glasses, if there are asthenopic symptoms or dimness of vision sufficient to justify their use. Since the lessening of the refrac-

tive error in hyperopia is usually a matter for congratulation, these cases do not give rise to much concern unless they pass over into myopia, especially when it is of the progressive type.

Moderate increase of myopia in children of school age, the so-called "school myopia," is rather to be expected, and the wearing of glasses has not had any effect on this change, though this is not the generally expressed opinion. The myopia usually ceases to progress about the eighteenth year (from 16 to 20) and when it is about 4 or 5 diopters.

Case 2.—Age, 12.
1914: R. — 3.50; L. — 3.50. Scopolamin.
1915: R. — 4.50; L. — 3.50. Scopolamin.
1925: R. — 5.50; L. — 5.00.

Sometimes the change continues to occur well into adult life, without reaching a high degree, so that, even if the patient is older, we still need feel no great concern if the myopia remains moderate in amount; i. e., less than 5 diopters, as shown in the following cases:

Case 3.—Age 15.
1898: R. — .25 + .50 ax. 15; L. + .25. Homatropin.
1900: R. — .25 + .75 ax. 30; L. + .25. Atropin.
1917: R. — 1.25 + 1.50 ax. 15; L. — .25 — .25 ax. 90. Homatropin.

It will be seen that this is a very different thing from the congenital form of myopia, which is of high degree when the conduct of the child first arouses a suspicion of some impairment of vision. Beginning with an error of from 8 to 10 diopters, there are the cases that progress to twice that amount or more and which show choroidal changes near the disk and elsewhere, and which ultimately furnish a respectable number of the cases of retinal detachment.

Attention will be called later to the well known influence of lens changes in increasing myopia or lessening hyperopia, and this possibility must be kept in mind in patients of 35 or older.

Occasionally a case will be seen in which an apparent increase in hyperopia occurs. The most obvious explanation is that the first test was made with incomplete cycloplegia, and this is usually the correct interpretation of the findings; but in case the observations were made often and by more than one observer, the probability of this being the explanation seems not to be correct.

CASE 4.—Age, 29.

1899: R. — .50 — 1.00 ax. 15; L. — 1.75 ax. 165. Homatropin.
1903: R. Same ax. 20; L. Same.
1907: R. — .75 ax. 15; L. — 1.50 ax. 1.80; Homatropin.
1909: R. + .25 + .25 ax. 180; L. + .37 ax. 90. (Dr. Robert Sattler.) Cycloplegic.
1911: R. + .75 ax. 135; L. + .50 ax. 85.
1913: R. — .50 + 1.00 ax. 135; L. — .50 + 1.00 ax. 85.
1915: R. + .75 ax. 135; L. + .75 ax. 85. Presbyopia.
1917 to 1920: R. Same; L. Same, ax. 90.
1923: R. + .75 ax. 150; L. Same.
1925: R. + .50 + .50 ax. 150; L. + .50 + .75 ax. 75.

Another case presented sudden and radical changes in the refraction, especially in one eye, in the direction of an increase in hyperopia, and the age of this patient and consequent suspension of accommodation from that cause makes this case an inexplicable one to me.

CASE 5.—Age, 57.

1917: R. + 2.50 + .50 ax. 180; L. + 1.25 + 1.25 ax. 180. Presbyopia.
1925:
Sept. 16, R. + 6.00 + .50 ax. 90; L. + 1.50 + 1.50 ax. 180.
Sept. 22, R. + 1.25 + 3.25 ax. 90; L. + 2.50 + 2.00 ax. 180.
Sept. 23, R. + 1.25 + 3.25 ax. 90; L. + 1.50 + 1.50 ax. 135.
Sept. 24, R. + 2.50 + 2.50 ax. 45; L. + 1.50 + 2.00 ax. 150.
Sept. 25, R. + 2.00 + 3.00 ax. 90; L. Same.
Sept. 26, R. + 2.50 + 3.00 ax. 30; L. Same.
Oct. 8, R. + 3.00 + 1.50 ax. 30; L. Same.
Dec. 3, R. + 2.00 + 3.50 ax. 60; L. Same.

The Wassermann reaction was negative; the urine and blood sugar were normal.

The largest group showing changes in the refraction are those in which the changes are almost entirely in the cornea, i. e., the corneal astigmatism. There seem to be conditions encountered from time to time that can-

not be readily explained on any other hypothesis; but, whatever the seat of the irregularity or the cause of the change, the total astigmatism does change, and often to a very considerable extent.

It is well to refer to the question of the anatomic changes in the eye that result in astigmatism. The lack of agreement between the keratometer reading and the estimation of the refraction, either by retinoscopy or by subjective methods, has led most observers to the view that the astigmatism may be either corneal or lenticular. Though corneal astigmatism is a constant thing, or in which, at least, there are no daily variations, it may change in time, either from alterations incidental to growth or quicker ones, the result of a wound or a disease, such as an ulceration, that can alter the curvature.

Lenticular astigmatism is thought by many to change more rapidly, because of a tilting of the lens, producing the well known astigmatic effect that follows when light passes through a lens obliquely. Irregular alteration in lens curvature, and therefore in the total astigmatism, is thought to be induced by irregular or sectional contraction of the ciliary muscle. We know that if a drop of any mydriatic drug is injected under the conjunctiva at a point near the limbus, the pupil will dilate irregularly, and more at the point where the drug was injected. It is easy to believe, therefore, that under certain circumstances a similar irregular contraction of the ciliary muscle may occur and produce lenticular astigmatism.

Attention has been frequently called to a change that takes place in the corneal astigmatism in middle life with such regularity that it can be considered as an almost physiologic change. Jackson studied the changes in 1,294 eyes after 5 to 71 years with reference to regular astigmatism. He found it liable to change at any period of life, the change usually being in the direction of an increase in the curvature in the vertical

meridian; hence astigmatism with the rule becomes the exception in the latter part of life, the opposite being the common type. The following case illustrates this occurrence:

Case 6.—Age, 31.
1922: R. — 4.75 — .75 ax. 180.
1925: R. — 4.75.

Another group, which may be dismissed as not coming within the scope of this article, are the cases of keratoconus. Nothing produces such tremendous changes in the corneal curvature as this condition, which usually is progressive and associated with dimness of vision. The curvature cannot be accurately measured with any keratometer, or more than approximately corrected by glasses, and a discussion of this condition (we might say, this disease) is not contemplated here.

The changes referred to are either temporary or permanent. The former are caused by pressure on the eye, as by a tumor of the lid or orbit, causing an irregularity of the surface, which usually disappears when the cause is removed. Any small tumor of the lid, such as a chalazion or cysts, can cause the change, which cannot be demonstrated after the cause has been removed. The following case is an illustration of this group:

Case 7.—Age, 45.
Cyst of upper lid.
L. — 2.00 — 1.50 ax. 15.
L. Cyst removed. — 1.50 — .75 ax. 160.

Closely related to this form of refractive change is that which occurs as the result of pterygium. This is probably brought about by two causes, the traction on the cornea, tending to bring about a change in the curvature just as pressure does, and the fact that the invasion of the cornea by the head of the pterygium may raise a minute fold on the corneal surface sufficient to make an appreciable change in the refraction. The point is that every patient who has a pterygium removed should have his refraction reviewed before he is dis-

missed. Not that the refraction always changes, but it often does under these circumstances, as illustrated in the following case:

CASE 8.—Age, 25.

1919: — .50 — .50 ax. 90; L. — .50 — .50 ax. 90.
1922: Same; L. Same. Homatropin.
Pterygium removed, O. U.
1923: — .75 ax. 120; L. Same.
1924: — 1.25 ax. 120; L. Same.

In other cases in which the subjective tests do not show so much change, the study of the cornea with the ophthalmometer before and after the removal of a pterygium shows the changes that occur very plainly.

Any operation on the cornea, such as the incision for the removal of a cataract, will cause, as we all know, a marked degree of astigmatism with the axis roughly parallel to the direction of the incision. Injuries or ulceration of the cornea can also produce such a result, though often of a highly irregular character. The operations of iridectomy, iridotasis and others do not produce nearly so high a degree of astigmatism, as a rule, as that which follows the cataract operation. The effect of iridotasis on the corneal astigmatism was observed in the following case, well adapted to study since the vision was not impaired:

CASE 9.—Age, 28.

1921. March: R. — 1.25 — 1.00 ax. 90. Homatropin. Glaucoma. Physostigmin.
April: R. — 1.25 — 1.50 ax. 75.
May: R. — .75 — 2.50 ax. 75.
June: R. — 1.25 — 2.50 ax. 75.
July: R. — .75 — 2.00 ax. 75. Iridotasis.
1925: R. — 1.25 — 2.00 ax. 75.

The irregular astigmatism that is produced by ulceration sometimes can be corrected by crossed cylinders whose axes are not at right angles to each other.

CASE 10.—Age, 21.

Dendritic ulceration of cornea, O. D.
1904: R. + 3.50 ax. 95 — 1.00 ax. 15 = 20/40.
1925: R. + 2.00 ax. 65 — 3.00 ax. 35 = 20/25 p.

The change produced by corneal disease may be of an entirely different and more regular character.

Case 11.—Age, 26.
1902: L. — .50 ax. 80°.
1923: L. Deep keratitis.
May: L. — 2.00.
August: L. — 1.00 — 1.25 ax. 135.
September: L. — 1.00.
1924: L. — .50 + 2.50 ax. 120.
1925: L. — .25 + 3.50 ax. 105.

Aside from these irregular changes, usually due to a definite and recognizable cause, there remains the large number of cases with which this paragraph has mainly to do; namely, those which show a change in the astigmatism, with or without a variation in the spherical error. These changes cannot be classified, but are very common. Jackson found that, in a period of several years, two-thirds of the cases he studied showed a change in the astigmia. Alterations in the index of the refraction of the cornea, aqueous or vitreous, may occur, but would not account for the general change in refraction that is observed. Changes in astigmatism may come from alterations in the curvature of the cornea or lens, or change in the index of refraction or in the position of the lens, but we know very little of changes in the curvature of the lens. The effect of changes in the position of the lens must not be disregarded.

It is of interest to consider how much of a change of curvature is necessary to produce an appreciable change in the astigmatism. Tscherning gives 7.8 as the average radius of corneal curvature. According to him a change of 0.18 mm. in the radius of corneal curvature is sufficient to produce 1 diopter of astigmatism in an eye with a normal radius of curvature. It is necessary to speak of this in terms of corneal curvature, since the corneal curvature is most easily studied.

These changes are so uncertain in character and degree that it is hard to classify them. Some idea of their nature may be seen from the records of a few cases.

CASE 12.—Age, 8.

1902: R. + .50 + 2.00 ax. 90; L. + 1.50 + 3.50 ax. 90. Atropin.

1920: R. + .50 + .50 ax. 90; L. — 1.75. Homatropin.

CASE 13.—Age, 30.

1912: R. — .50 ax. 180; L. — 1.00 ax. 180. Homatropin.

1916: R. — .50 + 1.25 ax. 90; L. — 1.00 — 1.25 ax. 90. Homatropin.

1925: R. Same; L. Same.

It seems that practically all the changes in the refractive media, lens, aqueous, vitreous, and to a much less extent the cornea, that we encounter result in an increase in their density and therefore an increase in the index of the refraction. The result is shown in the refraction becoming myopic or less hyperopic. There are many changes of which this is the result, the most commonly observed one being in cases of beginning cataract.

The so-called "second sight," as we all know, which enables elderly people to read without the glasses on which they have been dependent for years and which elicits the congratulations of their friends on their youth and vitality, is only the symptom of beginning cataract, and the development of lens opacities and consequent blurring of vision is only a further step in the history of the case. Jackson says that absorption of the cortex seems to be the physical change producing "senile myopia." "In the normal adult eye the refraction of the highly curved nucleus is partly neutralized by the convexoconcave layers of the cortex. As the latter are lost by absorption the nuclear refraction predominates, and rays entering through the nucleus are focused more in front of the retina. It is only necessary to suppose that such layers of the cortex shall be absorbed more in certain meridians than in others to conceive a sufficient

cause for changes in astigmatism with age." It is hardly necessary to quote cases to illustrate a thing that we all see daily in our offices, but one case will be mentioned to make the point clear.

CASE 14.—Age, 40.

1902: R. + 1.00 + .25 ax. 60; L. + 1.25 + .25 ax. 75. Homatropin.
1914: R. Slight change in axis.
1921: R. — .25 — .25 ax. 135; L. Same.
Peripheral lens striae O. U.
1922: R. — 1.50 — .50 ax. 90.
1923. March: R. — 2.75 — 1.25 ax. 90. November: R. — 4.25 — 1.50 ax. 90.

The increased density of the aqueous in inflammatory conditions of the iris and ciliary body always produces an increase in the refraction of the eye, often unnoticed, because the resulting dimness of vision is attributed to the clouding of the media by inflammatory exudates. The myopia under these circumstances is usually moderate, of 1 or 2 diopters, and decreases rapidly, *pari passu* with the return of the media to normal. This should be borne in mind in the correction of the refraction after cataract and other intra-ocular operations attended with inflammatory reaction, and full time allowed for the return of the eye to normal before fitting the glasses.

CASE 15.—Age, 65. Iritis.

June 25: R. — 1.00.
June 26: R. — 2.00.
July 22: R. — 3.00.
August 3: R. — 3.00.
September 1: R. — 1.25.
November 9: Recurrence.
November 21: R. — 2.50.

In diabetes, the refraction media, in common with so many other body tissues and fluids, show certain changes, or perhaps it would be better to say uncertain changes. Wescott and Ellis found that the refraction may either increase or diminish, usually the latter. The cause of this is not known, but the change will disappear as the sugar disappears from the urine.

In this connection the author reports two observations which are unusual and unique. One of the cases has been referred to in a discussion on quinine amblyopia. They are both cases of quinine amblyopia in little children who showed a high degree of myopia at the height of the ocular involvement.

CASE 16.—Age, 17 months.

October, 1910: Quinine amblyopia; blind. Ophthalmoscope: O. D. — 8; O. S. — 12.00.
November, 1910: Emmetropic.
November, 1914: Emmetropic.

CASE 17.—Age, 5.

1923: Quinine amblyopia; blind. Ophthalmoscope: O. D. — 3.00; O. S. — 3.00. Two months later, O. U. + 2.00.
1924: Same.

In dealing with any case of apparent change of the refraction, especially the increase or development of myopia, the possiblity of ciliary spasm should be kept in mind. Spasm of accommodation, as it is commonly called, is so common that only mention is given here lest it should be thought to have been disregarded. This condition is the principal stumbling block to the refracting optician, and judging from the number of hyperopic patients that these men fit with concave glasses, it would seem to be a condition that they have not learned to suspect, much less recognize. While usually small in amount, it is sometimes found to exist to a remarkable degree, a condition at once disclosed by the use of an efficient cycloplegic drug. Whatever may be one's views on the question of the necessity of using a cycloplegic in measuring the refraction, it is frequently essential that in certain of these cases they be used, not only for the purpose of diagnosis, but as a means of treatment as well. Accommodative spasm usually affects the two eyes equally, but sometimes it is very unequal, and under these circumstances very difficult to relieve.

CASE 18.—Age, 12.

1925: R. — .50; L. — 1.00 — 1.00 ax. 90.
R. + .25 + .25 ax. 180; L. + .50. Homatropin.

By far the largest number of cases that present changes in the refraction do not fall under any of these groupings, nor are they assignable to any known cause. They are, morever, very irregular as to their nature and the rate of progress of the change, and especially is it to be noted that the changes in the two eyes have no relation to each other. In this group are included all the cases that cannot be placed in one of the other groups, and for which no satisfactory cause can be assigned. They represent every sort of change and cannot be worked out by any rule but by the usual painstaking and patient method always followed in estimating the refraction. Such are the conclusions that can be drawn from the cases on which this paper is based, as indicated by the following synopsis of case histories:

CASE 19.—Age, 23.

1916: R. + .25 L. Emmetropic. Homatropin.
1923: R. + 1.00 ax. 180; L. + .75 ax. 180. Cyclopegic by another ophthalmologist.
1924: .25 + .75 ax. 180; L. — .25 ax. 90. Homatropin.
1925: R. Same; L. Same.

CASE 20.—Age, 28.

1908: R. — .75 + 1.25 ax. 60; L. — .50. + 1.50 ax. 90. Homatropin.
1913: R. Same; L. Same. Homatropin.
1918: R. Same; L. Same.
1919: R. — 2.00 — 1.25 ax. 165; L. — 2.00 — 1.50 ax. 180.
1921: R. Same; L. — 1.50 — 2.00 ax. 180. Presbyopia.
1926: R. — 1.00 — 1.25 ax. 165. L. — 2.00 ax. 180. Lenses clear.

CASE 21.—Age, 48.

1905: R. + 2.00 + .75 ax. 180; L. + 1.75 + .75 ax. 180.
1925: R. + 2.00 ax. 180; L. — .25 + 2.00 ax. 180.

CASE 22.—Age, 28.

1898: R. — 1.50 + 2.25 ax. 100; L. — .75 + 1.75 ax. 80. Homatropin.
1902: R. — 1.50 + 2.25 ax. 105; L. — .75 + 1.75 ax. 75. Scopolamin.
1910: R. ax. 120.
1921: R. ax. 135; L. — 2.25 + 2.75 ax. 60. Presbyopia.
1924: R. — 1.50 + 2.00 ax. 135; L. — 2.50 + 3.25 ax. 60.

The Field of Vision

The Recording of Perimetric Tracings. Until comparatively recently, perimetric tracings have usually been taken with a circular arc of 180 or even more degrees, the eye of the patient being adjusted so as to occupy as nearly as possible the center of curvature of the arc. The tangent method seems to have gone almost entirely out of use till it was revived some years ago by Bjerrum in his screen. More recently attention has been called to the advantages of tangent perimeters by several other authors.

The chief disadvantage of the tangent perimeter is that in the extreme periphery the tangent increases very rapidly, for the limiting value of the tangent of 90° is infinity, while that for 45° is unity. In the circular perimeter this difficulty, as shown by Freeland Fergus[2], is avoided, the graph being one in polar co-ordinates.

One of the advantages of the screen perimeter lies in the fact that as the eye which is being examined is not placed at the center of a curve but at any point the examiner chooses to select, by increasing the distance between the screen and the eye the field corresponding to the retinal image may be conveniently magnified. This magnification tends to much greater accuracy of work, and tangent perimeters seem to be admirably adapted for the delimitation of scotomata.

Many years ago Mackay, of Edinburgh, exhibited a large circular perimeter, which perhaps fulfilled to some extent the purposes of a large tangent screen. The ordinary circular perimeters often fail to reveal important defects in the field of vision, which at once become apparent when the more reliable tangent screen method is used. Those who have used screens for the investigation of the center of the field, say from zero up to 50°, have no doubt of their superiority for that purpose.

In using tangent perimeters, for the reasons above

(2) Brit. M. J., Jan. 8, 1927.

stated, it is desirable to have the patient at a considerable distance from the center of the screen. At the distance of only half a meter the tangent perimeter does not possess much advantage over a circular perimeter with a radius of curvature of half a meter. If the distance of the patient's eye be a meter from the fixation point on the screen, then for 45°, as the tangent of 45° is unity, the screen must in all directions extend to one meter from the central fixation point. For a distance of two meters a screen would require to measure, for an angular opening of 45° in all directions, at least 200 cm. from the fixation point.

That, of course, at once shows the limited use which can be made of tangent screens, because, even with a spacious room, it is impossible to get 70 inches between the fixation point and the floor; moreover, the patient's eye should be as nearly as possible on a level with the fixation spot. For the thorough examination of the center of the field of vision the tangent perimeter will be found to be most serviceable. In the usual forms supplied for recording perimetric examinations there is the same distance between zero and the circle representing 45° as there is between the circle representing 45° and that representing 90°, also the same distance between zero and 30° as there is between 30° and 60° and as there is between 60° and 90°. So long as the examiner recognizes the fact that he is dealing with polar co-ordinates and can translate their meaning then no great harm will accrue. But one advantage of tangent perimeters, where applicable, is that they give the field of vision without any need of interpretation.

Sinclair of Edinburgh, and probably other workers, have availed themselves of tangent scales. A tangent scale can be easily prepared for any radius, such as that of a meter or of two meters, or any other measurement that may be required; but nothing more is necessary than to take a note of the field given by a tangent perimeter in ordinary rectangular co-ordinates. The screen

perimeter used by Fergus, is black, and on it are traced in black tape the ordinary x and y co-ordinates. There is nothing to prevent the whole screen being divided up by such pieces of tape into little squares, the length of the side of each little square being two inches or even less, according to the breadth of the tape.

In the first quadrant both the abscissa and the ordinate are positive; in the second the abscissa is negative and the ordinate is positive; in the third quadrant both the abscissa and the ordinate are negative, and in the fourth the abscissa is positive and the ordinate is negative. Now with such a perimeter all that has to be done is to note accurately the values for x and y of every point taken in the boundary of a scotoma. There is no need whatever to transfer it to polar co-ordinates. Of course, should any such need arise, the calculation is of the most simple kind provided the distance at which the patient was placed from the fixation point has been accurately noted.

This simple method seems to avoid a considerable amount of trouble, and has the advantage that it requires no special diagram for the recording of the results; ordinary ruled paper, such as is commonly used for graphs, is all that is necessary.

The External Ocular Muscles

Some Misconceptions In the Diagnosis of Motor Anomalies. In any branch of diagnosis it is important to start with a clear conception of the nature of the conditions that are being investigated. Otherwise the significance of the tests that we supply for the detection of the conditions escapes us.

This statement is particularly true with regard to motor anomalies of the eye. Alexander Duane[3] in a contribution written but a short time before his death, expressed the belief that two fundamental misconcep-

(3) New York State J. Med., May 15, 1927.

tions have prevailed among many, and have militated against accurate diagnosis and effective treatment.

The first error consists in regarding a motor anomaly simply as a departure from orthophoria without inquiring into the conditions that produce this departure. In other words, many observers simply record the fact that the patient shows this or that amount of esophoria, exophoria, or hyperphoria in distant vision, without determining how these relations change at near points and how they change in different directions of the gaze, and also without determining the ability of the eyes to perform parallel movements in the six principal directions, or to converge or diverge. The importance of determining all these points if we wish to arrive at anything like a correct diagnosis has been repeatedly signalized. This careful observer had for thirty years been urging the fundamental importance of regarding and handling motor anomalies in this way. Yet he states that he had repeatedly received letters asking for a diagnosis and suggestions for treatment when the only data given were measurements, made repeatedly and with great care, of some exophoria or hyperphoria present. Such data, however accurate, are altogether insufficient for a proper understanding of the nature of the case or for the application of suitable treatment. This should be obvious when we consider that the eyes are in constant action, performing all sorts of combinations of conjugate, convergent, and divergent movements; that, in general, some interference with these movements is the thing that causes the motor anomaly and the patient's symptoms; and that the deviation that we find in the primary position is but one result, and that perhaps the least important, of the condition we are seeking to correct. The deviation found is but a symptom, and to treat it as a substantive affection without determining the conditions that underlie it would seem as strange a thing as for a physician these days to treat a case of dropsy simply as dropsy without seeking for its cause.

In many of these reported cases it is not even stated whether the deviation found is regularly or sometimes a squint or whether it is at all times a heterophoria. Yet this distinction is important—more important, indeed, than the actual measure of the deviation itself—since it shows how readily the eyes can be made to submit to fusion control. On this very point often hinges the question of treatment and especially of operation.

The second error seems to lie in the conceptions that some hold regarding the essential nature of orthophoria, heterophoria, and squint. To understand this let us consider what these conditions show as to the actual state of the eyes.

The great majority of persons when viewing an object with both eyes exhibit what we call binocular fixation and binocular single vision, i.e., both eyes are directed sharply at the object and both simultaneously see it. In a few cases when their attention is directed at an object, and they are looking at it with both eyes, one eye obviously deviates. We thus divide mankind into two classes, squinters and non-squinters, the former being evidently abnormal. But some of the non-squinters prove on examination to be abnormal too, for whenever we interpose a sufficient obstacle to clear binocular vision, we find that one eye deviates, to return to the fixing position when the obstacle is removed. These cases we group under the head of heterophoria. Furthermore, if we examine these cases in different ways and at different times, we find that the amount and persistency of the deviation vary with the means employed to elicit it and with the time during which the conditions of normal binocular vision are suspended. We find, in fact, that, according as we change the conditions of the examination, a deviation may be made to vibrate between an orthophoria and a heterophoria of varying amount or between a heterophoria and a squint.

It is often argued that a person who exhibits such

variations has a muscular error equal to at least the largest amount that he admits by the tests and that when he shows less he is concealing part of the error by effort. He is thus compared to a hyperope who at times reveals part, at other times none of his refractive error, and who reveals all of it only when put under atropin. From this viewpoint true orthophoria would correspond to emetropia, heterophoria to a latent hyperopia, and a squint to an absolute hyperopia.

This analogy, with its implications as regards the significance of the tests, is based on a fundamental misconception. The hyperopia in the one case represents an absolute static condition, i.e., the refractive state which appertains to the eye when making no accommodative effort whatever and which is conditioned solely on the shape and constitution of the refractive surfaces. This state is thus a perfectly determinate and stable affair. It is proper then to say that the accommodative effort masks or conceals the true refractive condition. But the muscular state of the eye (orthophoria or heterophoria) is quite a different thing. When without imposing any constraint on the eyes we look straight ahead at a distant object, each eye is held in place not by mechanical, unchanging conditions, but by the simultaneous contraction of all six of its muscles, each acting as a counterpoise to its opponent. These muscles in turn are made to contract to just the right extent by reflex stimuli set up by visual and muscular impulses acting through the coordinating nerve centers. The position of the eyes thus represents the balance of opposing varying forces, which are coordinated and regulated by the demands of fixation. These demands themselves are sometimes more, sometimes less imperious, so that this controlling power necessarily varies from time to time. With all this interplay of compelling forces and muscular tensions it is no wonder that in many cases the findings as to the position of the eyes vary. Such a variation will be particularly likely to occur if we in-

troduce factors that tend in varying degree to break up fusion control, and this we do in many of our tests (screen, phorometer, Madox rod). Nor when such variation occurs are we in position to say which finding represents the absolute state of the muscle balance. For, indeed, there is no such absolute state. When a man one day rejects a glass and the next day accepts a +1D, we do know that his static refraction is a hyperopia of at least 1D and we also know that by instilling atropin we can arrive at a true measure of what his refractive state is. But if a person shows orthophoria one day and on another day when his efforts are more relaxed an exophoria of $6\bar{\text{v}}$, we cannot by any means necessarily infer that the true state of his muscle balance is represented by a divergence of the visual axes of $6\bar{\text{v}}$ or over. All that we can say is that he has a tendency to divergence which at times when the fusion control is good is reduced to nothing, at other times when the fusion control is less strong amounts to at least $6\bar{\text{v}}$. But note that when he does show the $6\bar{\text{v}}$ of deviation this is generally due to the introduction of some non-natural and unusual condition, e.g., the application of some test that reduces the fusion control. If such tests are pushed further, so that fusion control is largely lost, then the moderate exophoria in such a case is turned into a large and temporarily incorrigible squint. We see instances of this when the patient has been subjected to prolonged monocular occlusion or has in other ways shunted off one eye, e.g., by prolonged use of the monocular microscope. And if the suspension of fusion control were pushed to its extreme, i.e., to the point of absolute and permanent abolition, then every person, even though originally orthophoric, would show not simply a deviation of the eyes but a complete dissociation. Such a condition could not by any possibility be regarded as representing the real state of the eye balance, nor could we say that any of the intermediate

conditions caused by partial suspension of the fusion control represented it precisely either.

One further consideration. When we abolish the accommodation with atropin, we have, as has been said, a perfectly fixed and determinate condition to deal with, namely, the refractive state conditioned by two unvarying factors—the curvature of the media and their optical density. But if we should succeed in absolutely abolishing fusion control, we would have no like stable condition to measure, i.e., no mechanically fixed position of the eyes, but an anarchy of opposing and continually varying, entirely unregulated muscular tensions, causing the eyes to wander aimlessly and more or less independently first in this direction, then in that.

A motor anomaly is thus fundamentally different in character from an error of refraction. A refractive error, being due to structural defects is unchangeable except as the result of comparatively slow alterations taking place in the shape of the eye itself. It is thus a substantive, unchanging entity. Its amount is definite and determinable, being represented by the highest measurements obtained on the use of the most thoroughgoing and prolonged tests (atropin). A motor anomaly, being due to the balancing of forces, is something essentially variable in its nature. It may remain approximately constant, provided the conditions under which the balancing forces are applied remain the same; but it changes as soon as these conditions are radically altered. It has no definite assignable amount, and the maximum values of it obtained by the most thoroughgoing methods of examination (prolonged occlusion) cannot be regarded as its true measurement but simply indicate the greater or less stability of the controlling forces and the tendencies that the eyes develop when these controlling forces are relaxed.

The most we can do is to determine whether the controls that keep the eyes from deviating are performed easily, habitually, and without nervous wear and tear,

or, on the other hand, whether the eyes frequently or usually escape from them and hence deviate. When they do deviate we can measure the amount of the deviation, yet even then cannot say that in so doing we measure the motor anomaly in anything like the sense that in determining the refraction we measure a refractive error.

All this has a direct bearing on the significance of the tests used in measuring motor anomalies. As above stated, many of these tests act by breaking up fusion control, and some do this in a more thorough-going way than others and sometimes therefore afford different findings. These differences are of considerable clinical significance. We may say that a person whose fusion control is readily broken up by even a momentary application of the screen test has an unstable, and one in whom the control is more stoutly maintained so that he has orthophoria by all tests, has a stable equilibrium. In some the equilibrium is so unstable that they readily drift from a heterophoria into a squint. Such indications as these are of much more significance than the actual amount of deviation elicited. So far as symptoms go, those who have prompt and easy fusion control have much less disturbances than those with much less manifest deviation in whom the control is difficult or uncertain.

How far we should go in releasing the eyes from fusion control when making our tests is a matter of controversy. Marlow and others believe that we should in very many instances use occlusion of one eye for a week or so. The idea underlying this practice seems to be that such occlusion freeing the eyes from fusion control will reveal their true motor condition, in much the same way that cycloplegia under atropin reveals the true refractive state. When we thus employ occlusion for a week we do not reach the limit of release from fusion control as we do reach the limit of accommodative relaxation when we use atropin in a thorough-going way. The ultimate limit would be reached only by

occlusion for many months, which if it had its full effect should produce dissociation of movements or a return to the early infantile state, in which it is said the eyes wander more or less aimlessly without reference to each other. This certainly would not represent the natural condition of the eyes, nor would the half-way emancipation produced by a week's occlusion represent it either. What such occlusion does effect and what may make it serve as a valuable indication in some cases is that it demonstrates how readily the eyes tend to escape from fusion control, and, when they escape, what special tendencies to deviation they exhibit. In this way the test may furnish a guide to operation. But even here caution is necessary. Prolonged occlusion is pretty sure to develop a convergence insufficiency which can be only regarded as artificial and which produces an exophoria marked for near and sometimes fairly considerable for distance as well. Such an insufficiency will disappear when fusion reasserts its control and is by no means necessarily an indication for operation.

On the other hand, such an artificial insufficiency may take some time to disappear and produce troublesome symptoms in the meantime.

For this reason the occlusion test for determining deviations should be used with circumspection and only in selected cases, and the findings from it should be regarded only as a general guide. It would seem of much more value in vertical than in lateral deviations. In the former, however, with the exact methods of analysis that we have—determination of the extent of the excursions of each eye in binocular movement and the determination of the deviation and diplopia in different directions of the gaze—it would not seem often required.

For a like reason the practice at one time much employed of "developing" the full amount of a deviation by prisms is in general unsound. The idea underlying this procedure was that if a patient showed a moderate error — particularly a hyperphoria — we

should correct this with a prism, and after he has worn this awhile, should test him again to ascertain if more error had developed. If it had, the prismatic correction was progressively increased until no more error was manifest. In some cases this procedure seemed helpful; but there is always the risk that the patient will develop a condition quite artificial, particularly if he has good fusion power. In no case should this method be tried for a lateral deviation and but rarely for a vertical. This statement does not mean that a trial prism should not be used to ascertain if it relieves symptoms. The use of such a prism may give valuable indications for the subsequent treatment. But this is quite different from using a prism to "develop" a supposititious latent muscular error—a thing the very existence of which is problematical.

As opposed to the methods above considered, the most valuable tests of imbalance are those which produce only a moderate relaxation of fusion control and which thus indicate not only the tendencies of the eyes but also the relative ease with which the power that regulates and restrains these tendencies can be put out of gear. Thus a deviation which is made manifest at once by putting on a red glass is of more significance and is more directly in need of relief than one which shows no diplopia by this means and is rendered apparent only by the screen test or Maddox rod. Again, a deviation shown by the screen, which is of large amount but is instantly and easily redressed when the screen is removed, is of less moment than one of much smaller amount which is overcome with difficulty, or at times, not at all.

In any case, the tests for imbalance, however made, must, as already said, be supplemented by tests which show how well the eyes are possessed of the means that enable them to effect fusion in all directions and ranges of the gaze. They must be supplemented by tests which indicate the ability of the eyes to keep pace with each other in each of the six primary directions of the gaze

and the tests for convergent and divergent movement. These tests, indeed, are more important than the tests for imbalance per se. For the diagnosis and for the determination of the means that should be used to remedy the motor disturbances they are in fact essential.

Causes of Concomitant Strabismus. A. M. Morgan[4] believes that the theories of Donders and Worth did not explain why hyperopes sometimes had divergent squints and myopes sometimes had perverted squints, nor why vertical squints occurred. These theories also did not explain why all squints were not cured by a full correction of the refractive errors as, theoretically, they should be, nor why the patients might have a squint in any direction without any error or refraction at all. In his opinion the three causes of concomitant squint, in the order of their importance, were weakness of the fusion sense, heterophoria, and hypermetropia. The first only was essential, but must be accompanied by one of the others. The determining factor in the development of a squint was the relation between the desire for fusion and the effort needed to align the eyes correctly. If the desire for binocular vision was greater than the effort there would be no squint. If the effort was greater than the desire a squint would result. Hypermetropia played a very minor part in the causation of convergent squint. Myopia as an error of refraction had no part in the causation of divergent squint, though it might tend indirectly to exophoria in myopic eyes.

It has been said that no baby is born with a squint, and this is roughly true, inasmuch as in the absence of either a deformity of the skull or an anatomical malformation of the eye-muscles—both very rare conditions—the visual axes of the two eyes are always approximately parallel at birth. The cerebral center for the coördination of movement of the two eyes are sufficiently developed to keep them approximately parallel, as a rule, but during the first few weeks or months of

(4) Brit. M. J., Apr. 23, 1927.

life this approximation is by no means exact, and young infants are frequently noticed to squint occasionally, a circumstance that need cause no anxiety unless it persists. During this period the infant is literally learning to see. If the visual axes of the two eyes are not directed towards the same point of any object—say a rattle—it appears double, but the infant soon learns by the sense of touch that he has only one rattle, not two, and by instinct brings the muscles of his eyes to confirm what his hands have told him.

The power of binocular vision, however, is as yet far from being fully acquired. The images of any object towards which the two eyes are directed are slightly different because they are formed at different angles. The power of combining these two images into a perception of the object is known as the fusion-sense and it takes years to acquire. Some children, and particularly members of some families, never acquire it, and in its absence various factors sometimes combine to cause a squint. The close association between convergence and accommodation is the best known of these factors, so that hypermetropic children whose fusion-sense is defective are peculiarly liable to it. Not all squinters are hypermetropic, however, and another frequent factor in the causation of squint, of at any rate equal importance, is an unusual call on the nervous system such as a sudden fright or an attack of measles. If the fusion-sense is already well developed the unconscious effort to see binocularly is sufficient to prevent the child from squinting; but if the fusion-sense is absent or badly developed, the mechanism which coördinates the lateral eye-muscles may easily be thrown out of gear.

As most children are hypermetropic the squint is generally convergent, but it may be divergent. In either case, when a squint is well established the attention of the child is so concentrated on the image in the better eye that the one formed in the retina of the worse eye

is not attended to at all. It is "suppressed," and if this suppression is allowed to continue the eye often becomes incapable of any useful vision. It is this fact that renders it so essential that all squints in children which are constant should be treated without delay—not by operation, in the first place at any rate, but by glasses, and, if necessary, by forcibly suppressing the image not of the squinting eye but of its fellow.

If one eye is blind from infancy it may or may not squint. If it does, the squint is generally convergent at first, but in later life may become divergent. Similarly, if both eyes are blind from infancy they may or may not squint, but in this case the reflex stimulus to the coördinating mechanism have never been in action, the latter is so far put out of gear that there is almost always nystagmus. If, on the other hand, as in those who become blind after early childhood, the coördinating mechanism has once been firmly established, it almost always continues to function, even in the absence of the sight of either eye.

Cases of optic atrophy seldom either squint or have nystagmus. In myopia a squint is usually divergent but as myopia is almost never present in infancy this is only seen in adults as a rule. A single blind eye, whether myopic or not, often diverges in adult life, but in children will as often be found to converge.

Mechanical Exactness in Operating for Strabismus. The great feature that has militated against the operative treatment of strabismus from the time of its inception has been the element of uncertainty; uncertainty as to the etiology of the case in hand; if muscular, as to the location, character and amount of the muscle defect; uncertainty as to the character and the amount of the operative measures necessary to correct the defect present in the case in hand.

In the light of medical science of today, the first requisite in the operative treatment of strabismus as

stated by W. E. Boynton[5] is a correct differential diagnosis—an accurate determining of the existence of a muscular defect, of the muscle or muscles at fault, of the character and the amount of the defect in each muscle involved.

The second requisite is a definite and reliable rule as to the amount of alteration necessary to be made in each affected muscle to correct the existing defect.

The third requisite is the possession of instruments of precision by means of which the operative measures may be definitely and accurately gauged.

The fourth requisite is the selection of the operative measures that can be readily gauged, that incur the least danger and that insure the greatest degree of success.

Such exactness is not only the sine qua non of the scientific treatment of strabismus, but is now the heritage of every well-trained ophthalmic surgeon.

Differential Diagnosis.—By means of the Stevens Tropometer the existence of a muscular defect in the case in hand can be positively established; the muscle or muscles at fault can be definitely located and the character and the amount of the defect existing in each muscle involved can be positively and accurately measured. (Fig. 3.)

With the long axis of the tangent scale in the ocular of the instrument placed horizontal and the instrument adjusted so that the patient's cornea is accurately included within the major vertical lines of the scale, adduction and abduction are carefully tested and the excursions of the corneal limbus in both directions carefully noted and recorded. The test is repeated at different sittings until the surgeon is assured that his measurements correctly indicate the patient's adduction and abduction. This frequently is possible as early as the seventh or eighth year.

The tropometer findings having been established for

(5) Eye, Ear, Nose and Throat Month., July, 1927.

the individual case, the surgeon compares them with the accepted normal.

Example.—The arbitrary ratio 50:50 representing the normal ratio between adduction and abduction:

Miss A. B.

Tropometer findings:

R. E., adduction 50, abduction 50.

L. E., adduction 60, abduction 30.

Deductions from findings:

R. E., normal balance.

L. E., (a) adduction excessive 10.

(b) abduction deficient 20.

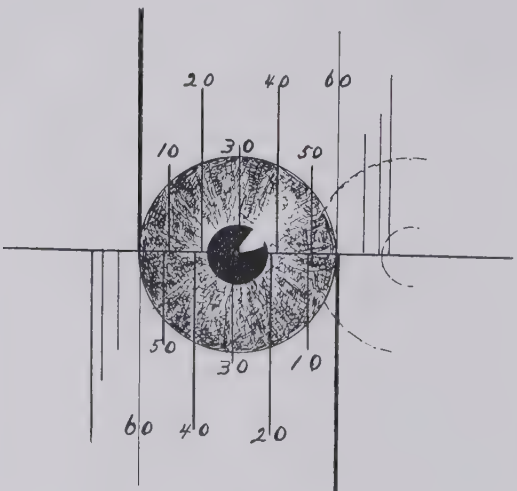

Fig. 3—Scale and Use of the Stevens Tropometer.

Causal factors and amounts:

(a) action of medial rectus in excess equal to 10.

(b) action of lateral rectus insufficient equal to 20.

The first requisite has been met. The case is one of muscular imbalance, the defect being confined to the left eye. Both of the horizontal muscles of that eye are at fault, there being an adduction excess of 10 degrees

and an abduction deficiency of 20 degrees. The action of the medial rectus must be lessened and that of the lateral rectus increased. The amount of the alteration must be sufficient to produce a change of 10 degrees in the action of the one and of 20 degrees in the action of the other.

The value of such a differential diagnosis can hardly be overestimated.

Rule for Operation.—By means of the operative rule proposed by Howe, modified to accord with the correct location of the center of movement of the eyeball, the surgeon may correctly and accurately determine the amount of change necessary to be made in the length or leverage of the muscle to produce the demanded change in its action.

Rule.—A change of 1.5 *mm. in the length or leverage of the muscle for the first two units of* 5 *each, and of* 1.0 *mm. for each additional unit of* 5.

Example.—Case of Miss A. B. continued:

Deductions from tropometer findings:

(a) medial rectus left eye excess 10.
(b) lateral rectus left eye deficient 20.

Alterations according to rule:

(a) shorten lateral rectus 5.0 mm.
(b) lengthen or retroduce medial rectus 3.00 mm.

The second requisite has been met. The surgeon knows exactly the amount of change necessary to be made and its character.

This rule, like the findings of the differential diagnosis, is of inestimable value. It removes the uncertainty which heretofore has ever attended the operative treatment of strabismus. It obviates the necessity of confirmatory tests made during the progress of the operation. It admits of the use of general anesthesia.

Instruments of Precision.—The third requisite calls for operative instruments of precision by means of which the surgeon may definitely and accurately gauge the

amount of alteration being produced in the length or leverage of the muscle while the operation is in progress and without interrupting the operative measures.

By means of the double blades of this instrument both ends of the incised tendon are firmly held throughout the operation by tenotomy and their parallelism maintained. By separating the two blades by means of the actuating screw and in accordance with the millimeter scale on the handle of the fixed blade, the recession of the severed muscle is accurately gauged and perfectly controlled. By means of "stay sutures" of equal tension uniting the margins of the severed muscle with the respective margin of the tendon-stump at its scleral insertion, the severed muscle is anchored at the desired point of recession and assurance afforded that its line of reattachment to the sclera will be parallel

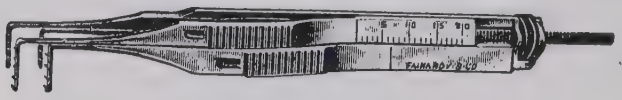

Fig. 4.—The George Strabismus Forceps.

to its original insertion and equal in width to the basic width of the muscle. (Fig. 4.)

This instrument may also be used for tucking but not as satisfactorily or as readily as the following instrument.

By means of this instrument a loop of tendon and muscle of definite proportions is presented, free from obstruction, for conversion into a tuck by means of sutures. The loop formed is of equal dimensions of both margins of the muscle and is placed at right angles to the long axis of the muscle. The amount of the loop that will be formed is indicated by a millimeter scale on the fixed blade of the instrument. The maximum amount of the loop that can be formed in the case in hand can be regulated and fixed by means of a lock-nut, the adjustment being made prior to beginning the operation. The loop is formed after the instrument has been placed

upon the muscle by means of the actuating screw. The sutures converting the loop into a tuck are placed and tied while the loop is still being held formed by the instrument, and no obstruction is offered either to observation or the manipulation of the needle. (Fig. 5.)

The basic principle of this tucker is not new, but the instrument possesses several important features not found in any other single instrument; the tuck formed



Fig. 5.—The Boynton Tucking Forceps.

is definitely gauged and indicated and is of equal dimensions on both margins of the muscle and is gently and positively controlled; the loop is at right angles to the muscle and perfectly accessible; while the instrument is "set" before being placed upon the muscle, the tuck is formed and completed while the loop is still held as formed by the instrument.

Choice of Operation.—The fourth requisite is the selection of an operation that can *readily be gauged* and will be productive of the requisite increase or decrease in the action of the muscle and, withal, one that entails the minimum number of adverse possibilities and presents the least technical difficulty.

As the prime requisite at the inception of the operative treatment of strabismus is a differential diagnosis, so the individualization of the case must be carried on to the selection of the operative measures. In the great majority of uncomplicated cases, however, the gauged tenotomy and the gauged tuck will be found

most satisfactory as to reliability of results and as to simplicity of technique.

The Gauged Tenotomy.—The muscle having been exposed and presented on the tenotomy hooks, the George forceps, with the jaws of both blades open and the blades separated sufficiently to admit of the tendon being incised between them, is placed upon the muscle, the nether jaw of each blade passing between the muscle and the eyeball. The proximal or fixed blade of the forceps is then drawn snugly against the scleral insertion of the tendon and both blades are closed and locked. The sutures are then placed in the proximal portion of the muscle, on, at and including each margin, and the loose ends are put well back out of the way. The tendon is then incised between the blades of the forceps, care being taken to include all of its fibers. The blades of the forceps are then separated by means of the acuating screw, allowing the severed muscle to recede the desired amount as indicated by the millimeter scale on the handle of the fixed blade of the forceps. In gaging this amount allowance must be made for the initial separation of the blades provided for the incising of the tendon. The sutures are then carried between the blades of the forceps and the eyeball and through the tendon-stump between the proximal blade and the sclera, drawn equally taut and securely tied. The jaws of the forceps are then opened and the instrument removed. The incision in the conjunctiva and orbito-bulbar fascia is then loosely closed by interrupted sutures. The free ends of the sutures are then excised, leaving "tails" of about 10 mm. in length. The conjunctival sutures are to be removed in one week and the muscle sutures in two weeks. The eyes are not bandaged. Dressings saturated with a cold boric acid solution are placed upon the closed eyes for the first 24 hours intermittently. The patient remains quietly in bed for three days. Sterile vaseline is applied to the lid margins at night to prevent agglutination.

The Gauged Tuck.—Before beginning the operation the surgeon "sets" the tucking forceps, opening the instrument to the maximum degree necessary to produce a tuck of the required dimensions and adjusting the lock-nut to prevent the instrument's being opened beyond that point. He then closes the blades of the forceps, passing the single prong of the minor or movable blade through and beyond the double prong of the fixed blade to a distance sufficient to allow the forceps to be placed easily upon the muscle with the prong of the movable blade passing between the muscle and the eyeball. The forceps is then laid aside ready for use.

When the muscle has been exposed and presented, the tucking forceps is so placed upon it that the long axis of the instrument will coincide with the long axis of the muscle and that the loop of tendon and muscle when formed will be "presented" toward the cornea. With the forceps held rigidly in this position, the nether blade and the superincumbent muscle are slowly drawn through the prongs of the fixed blade by means of the actuating screw until further progress is prevented by the lock-nut. A loop of tendon and muscle of the desired dimensions has then been formed, lying at right angles to the long axis of the muscle and of equal dimensions on both margins of the muscle. The loop is then converted into a tuck by sutures, one embracing each margin of the muscle and one centrally placed. The incision in the conjunctiva and orbito-bulbar fascia is then closed by interrupted sutures. The conjunctival sutures are to be removed in one week and the muscle sutures in two weeks. As in the tenotomy, "tails" of about 10 mm. are left in both series of sutures. No bandage is used. Dressings saturated with a cold boric acid solution are intermittently placed upon the eyes during the first 24 hours, and sterile vaseline applied to the lid margins at night. The patient is kept quiet in bed for three days.

The Early and Most Practical Assistance in Correcting the Commonest Type of Strabismus or Squint. In the experience of Frederick Kingsley,[6] the most common type of strabismus is the monolateral (one-sided convergent squint). In correcting this condition, he has found the method described here of value. The directions are arranged in the order in which they are to be followed from birth.

1. Beginning at birth, or as soon after as the squint appears, the mother or nurse is instructed, when holding the child in her arms, to hold it in such a position that at the sound of her voice or a touch of her hand the child rotates the affected eye in an outward direction (that is, in the opposite direction to which the eye is turned in the convergent squint).

2. The crib or cot in the nursery should be in such a position that when the nurse or mother enters, the child, at the sound of the voice, or at the touch, will turn the involved eye in the proper direction, which should again be opposite to the squint.

3. When bathing the infant, the same arrangement should be followed.

4. When the child is old enough to eat at the table, if his left eye is involved, he should always be placed at the attendant's right hand; if his right eye, at the attendant's left. This routine procedure should be thoroughly and carefully carried out to obtain the maximum results.

5. Careful refraction and the wearing of glasses should be instituted as early as possible. The age at which it is reasonably safe to order glasses depends on the temperament and early training of the child. Most children can be trusted to wear them at 4 years of age, while in some cases he has been able to order glasses for them at 3 years of age, with best results. But one must be guarded in ordering glasses for the very young child.

6. In all cases of squint, an examination should be made as early as possible for adenoids; if found, they

(6) J. A. M. A., May 7, 1927.

should be removed. Independent of whether the child has reached the age to wear glasses or not, when he is at play, walking, driving or at school, these instructions regarding the placing of the child at the right or at the left hand should be followed.

Parents will follow these instructions much more readily than they will carry out the bandaging, covering or atropin methods. If these instructions have been carefully followed, when the children arrive at the age of 12, or thereabout, a very small percentage require operation.

The General Practitioner and the Child With Squint. This subject is presented by V. K. Hart[7] from the standpoint of the general practitioner; not that of the specialist. With this idea in mind unnecessary technicalities will be avoided.

It is the fundamentals in which the doctors outside the specialty are interested.

Very often the family physician is the first one to whose attention the squint is called. It is he in such instances who must advise the family. Proper advice at this time means much to the future of the child.

The baby with strabismus is first considered, the condition commonly being first noted about the end of the first year. Very few children are born with a squint. If truly congenital, it is usually the result of paralysis of one or more of the ocular muscles and the prognosis is poor.

Why should a squint manifest itself in early childhood? This brings up the basic etiology.

The majority of squints are of the convergent type. Whether convergent or divergent squint may be monocular; i. e., the child constantly fixes with one eye, letting the other deviate. The other variety is the alternating in which either eye fixes. When the visual axis of one eye turns, the other eye fixes on the visual object. Both never fix at the same time.

(7) South. M. and S., November, 1926.

The common cause of squint of the convergent type in a baby is a high degree of far-sightedness with or without a complicating astigmatism. Such an error brings all the strain on near work. Babies soon become curious concerning objects about them. They focus on close objects by using the ciliary muscle which flattens or bulges the lens, so to speak. The third nerve supplies this ciliary muscle and also supplies the internal recti. Consequently when the child over-accommodates for near objects, and this is done to bring the object from behind the retina onto it, the internal recti are unnecessarily innervated at the same time. However, if both eyes over-converge concomitantly, imperfect binocular vision results because the rays of light are thrown off the sensitive part of the retina. Tersely expressed: the amount of accommodation necessary to give clear vision causes too much convergence. Consequently only one eye is used at a time and the other is allowed to turn in order to suppress the image in this eye. Evidently it is not so easy to over-accommodate when fixing with just one eye. At any rate, due to the error, imperfect muscle balance results and a squint ensues.

There are other causes of squint. There may be a difference in the vision of the two eyes, but this really comes under refractive errors. A third and most important reason is a lack of development of the fusion faculty. The trouble in such a case is central, with disturbance of innervation.

This latter reason probably explains why some children with only a small refractive error will develop squint, while children with larger errors have little obvious trouble. The neuropathic constitution of the child is a factor.

What advice then is the family doctor to give the parents of such a child? By all means the consultation of an eye man should be sought. The only therapy of any value in the first two or two and one-half years is atropin. Its judicious use is sometimes helpful for

paralyzing the nerve endings of the third nerve and preventing the child from over-accommodating. By occluding the good eye intermittently with a pad the patient may be forced to use the non-fixing eye, if the strabismus is of the monocular type. It is to be remembered that visual acuity develops only with correct use.

The proper glasses are not fitted until two and one-half or three years of age. At this time this is done by means of a retinoscopy; i. e., light reflected by a small mirror into a dilated pupil. The refractive error can be very accurately determined in this manner. This estimated, the proper glasses are fitted. These in no way affect the muscles. They merely relieve the overwork and the condition may thus gradually right itself.

If at the end of a year the strabismus shows no marked improvement operative work may be considered. This is of two types. Either the external rectus is advanced or a partial tenotomy is done on the internal muscle (complete tenotomy is never justified). One or both eyes are operated upon depending on whether the squint is monocular or alternating.

The doctor should impress the family with one vital fact. They should be willing to place the child under a specialist's care for two years if necessary. Very often one operation does not suffice and many times it takes five or six. However, all of these children can be improved, and many cured.

Another important fact should be impressed on the parents by their physician. Binocular vision, the ability to use both eyes on the same object at the same time, develops in the first six years of life and rarely after that. How important it is then to have the child brought under treatment early.

If operative work is necessary it can be done with little risk to the eye.

Optic Nystagmus and Its Value in the Localization of Cerebral Lesions. Fox and Holmes[8] made investiga-

(8) Brain, 1926, 49:333.

tions to determine if an absence or a modification of optic nystagmus to the one side has any value in the localization of cerebral lesions. Their observations were made on 41 cases of cerebral tumor, in 24 of which the site of the lesion was verified by either operation or postmortem examination. They concluded: "That a unilateral lesion of the forebrain can disturb lateral optic nystagmus to the opposite side only. If the lesion lies in the right hemisphere clockwise rotation of the drum evokes a nystagmus, consisting of slow deviation of the eyes to the left and quick jerks to the right; in other words, a nystagmus to the right; but anticlockwise rotation has no effect, or produces a less regular or less pronounced nystagmus to the left." While to any definite conclusion some of their cases presented obvious exceptions, it seemed that nystagmus to the opposite side is effected when a lesion lies in the supramarginal or angular gyrus, in the adjacent portion of the parietal and temporal lobes, in the posterior end of the second convolution or along the line joining this with the angular gyrus. Their observations tend to support Stenvers' hypothesis, that reflex centers for optic nystagmus lie in the occipital lobe and in the second frontal convolution and that these are connected by a reflex path which runs through the white matter of the hemisphere.

Aneurysm of the Internal Carotid Artery. Vilhelm Magnus[9] reports the case of a man of 65, who came to him because of pain in the crown of the head, which radiated down the right part of the forehead, the right eye and the right side of the nose toward the right ear and down the right lower jaw. The pain had begun three months before; it was constantly increasing and never stopped for a moment, preventing the patient from sleeping at night. Sometimes the pain became unbearable and was described as a burning sensation. The patient could not stand to have his beard touched,

(9) J. A. M. A., May 28, 1927.

and when washing he was obliged to exercise the greatest care. He was able to chew solid food without the pain increasing very much. The pain was relieved when he put a handkerchief over his face and breathed inside it so that the air became heated.

As shown in the accompanying illustration (Fig. 6), the right palpebral fissure was much narrower than the left; the right eye was directed inward and moved only a little upward and downward, and the right pupil was

Fig. 6.—Patient with aneurysm of internal carotid artery.

much smaller than the left one. Both eyes reacted to light, and after the injection of a 5 per cent cocain solution the left pupil but not the right become dilated; the right corneal reflex was extinguished. The oculist who examined the patient reported only a paralysis of the right nervus abducens and sympathicus. On account of the strong inward rotation of the right eye, it was impossible to estimate the intra-ocular pressure. For the same reason it was impossible to determine whether there was a trochlearis paralysis, an oculomotorius paralysis being absolutely out of the question. Besides this condition, there was hypesthesia throughout the right half side of the face. There was no involvement of the other cranial nerves.

The patient was somewhat dull; his understanding was slow, and he looked considerably older than he was. The temporal arteries were greatly tortuous, these as well as the radial arteries being hard and knotted. The Wassermann reaction of the blood was negative, and further examination revealed normal conditions. Six years before, the patient had been treated for a right abducens paralysis.

Briefly, the patient's condition was a trigeminus involvement of the right side, besides a paralysis of the sympathicus fibers which innervate the right orbit and an abducens paralysis on the same side. The diagnosis was made, of a slowly growing tumor in the trigeminal region, which first compressed the nervus abducens and then the gasserian ganglion.

As the patient's condition was unbearable, an operation was performed in order to remove the trigeminus root. When the dura mater was detached, the middle meningeal artery was lacerated down on the base of the cranium, and as it was very difficult to ligate so far down, the external carotid artery was ligated on the neck. As the dura mater was detached from the base of the cranium, a tumor appeared about the size of a chestnut with a smooth surface and glistening like mother of pearl, strictly limited and situated on the surface of the gasserian ganglion. During the further attempts at detaching the dura mater from the surface of the tumor in its medial part, a hole was torn and the contents of the tumor poured out; they were yellowish brown, and came out in portions. About half was easily emptied with a spatula; while the rest was being enucleated, a great gush of blood that could not be stopped by tamponade poured out. The internal carotid artery was now ligated, and the bleeding stopped. The contents of the tumor could now be emptied without difficulty and the lateral wall, which was as thin as paper, extirpated. The medial wall was

not removed for fear of injuring the sinus cavernosus. Afterward the trigeminus root was removed.

The patient stood the operation very well, the pulse never dropping below 74. He was not anemic after the operation, the loss of blood not having been very great, thanks to the comparatively rapid ligation of the internal carotid artery. The blood pressure was 165.

Three days later he complained of the left hand being paralyzed; he could move his fingers just a little and could hardly dorsiflect the hand, although the strength of the upper arm was satisfactory. It should be particularly noticed that the Babinski toe and the abdominal reflexes were equally strong on the left and on the right side. The sutures were removed the fifth day after operation, and three days later he was allowed to get up. The ptosis and the position of the eyes were unchanged, and there was a total anesthesia in the right trigeminus region. He was absolutely free from pain, the paralysis in the left hand being the same.

The microscopic diagnosis of the contents of the tumor was blood coagulation. Doubtless the tumor had been an aneurysmal enlargement of the internal carotid artery in its course inside the sinus cavernosus, which had first pressed on the nervous abducens and then on the sympathetic fibers which pass from the carotid arteries to the gasserian ganglion. The coagulation of the blood indicated that there had been a tendency to repair the failing artery walls, but it is hardly probable that the cure would have been permanent. The aneurysm had constantly enlarged laterally, and by its pressure on the surface of the gasserian ganglion it had caused trigeminus neuralgia. It is supposed that the aneurysm would have burst within a comparatively short time and killed the patient.

This particular case shows that much can be done for patients suffering from this complaint, if only the practitioner who has the case adopts a similar treatment. Doubtless the mortality after ligation of the internal

carotid artery is rather great; but if nothing is done, certain death will be the fate of the patient.

The Eyelids

Blepharochalosis. The disease of the upper eyelids, to which Fuchs, in 1896, gave the name of blepharochalosis, had not been reported by American ophthalmologists until 1913, when Weidler reported two cases and gave the microscopic findings in one of them. Cases of blepharochalosis had been reported from several European clinics, and the writers had discussed the etiology, pathology and treatment of diseases of the lids similar to, but not identical with, those reported by Fuchs. Since Weidler's paper was written, seven cases have been reported in American literature.

The disease is usually found in young persons as an intermittent swelling of the upper lids. It first makes its appearance soon after puberty as a transient edema of the upper lids lasting for a few hours, the attacks coming on at intervals of a few days or a few weeks. Succeeding attacks last longer and appear more frequently, until a permanent swelling of the lid with great thinning of the skin and bagginess of the lids results. The bagginess and atrophy of the skin are the characteristics of the disease by which the name blepharochalosis is suggested. The onset is usually insidious, and its early manifestations are overlooked or misinterpreted. The diagnosis becomes clear only after permanent changes are brought about in the lids.

The disease is more commonly found in young girls but has been observed in young boys and even in old men.

W. L. Benedict[1] gives a report of three cases seen at the Mayo clinic in the last six years. These cases are illustrated by the accompanying photographs (Figs. 7, 8, 9). The author says that the disease is to be

(1) J. A. M. A., Nov. 20, 1926.

Fig. 7.—Intumescent stage of blepharochalosis. The swelling has been constant for nearly fifteen years.

Fig. 8.—Stage of blepharochalosis without swelling characterized by wrinkling of the skin of the lid.

Fig. 9.—Early stage of blepharochalosis, showing baginess of the temporal portion of the upper lids without marked alteration in the skin.

found in two stages. The first is the intumescent stage or stage of edema. The early attacks of swelling resemble those of angioneurotic edema and last, usually, for from two to four days, without pain, and with only slight redness of the skin. After several attacks of swelling, one of two things occurs: (1) The swelling becomes constant with bagginess of the skin of the lid so that loose folds hang down over the margin, giving the appearance of water-filled bags, with the skin altered slightly in color, very thin, and slightly folded or wrinkled; or (2) the swelling disappears entirely or occurs for only short times, at intervals of weeks or months, and the skin becomes reddish brown and wrinkled, and is thrown into horizontal folds resembling brown wrinkled cigaret paper. The latter condition causes less interference with vision but may be accompanied by true ptosis, as shown by the first case of this series. The stage of wrinkling is the end stage of the disease. It has been confused with chronic atonic ptosis, which condition it indeed closely resembles, but the latter can be differentiated by the absence of attacks of swelling.

The disease cannot be considered a frequent occurrence in cases of exophthalmic goiter. In the reported cases of Ascher's syndrome there were no symptoms of exophthalmic goiter noted, and Ascher himself was unable to find blepharochalosis and double lip in cases referred to him from a large goiter clinic. In the Mayo clinic, the occurrence of blepharochalosis and double lip in cases of goiter has never been noted. Edema of the upper lids with mild exophthalmos, which in itself is probably due to edema of the soft tissues behind the globe, may be an early sign of exophthalmic goiter, but the change in the skin of the lid characteristic of blepharochalosis never develops to a noticeable extent.

The only treatment suggested for the relief of blepharochalosis is excision of the redundant skin and subcutaneous tissue, with fixation of the lower margin of

the wound to the upper margin of the tarsus. If the association of the disease with development of the endocrine glands can be substantiated, it is probable that some medical treatment can be applied for the relief during the intumescent stages. For the ptosis that results from the atrophic changes in the skin, only surgical measures can be applied with hope of success.

Sarcoma of the Eyelid. The sarcomatosis that occurs about the eye is usually a feature of early youth, whereas the epitheliomas are of adult life. An epithelioma of the eyeball and adnexa is not uncommon.

Fig. 10.—Sarcoma of the lid.

Sarcomas occur in vascular parts as in the orbital cavity and in the nose. Sarcoma of the nose is not at all infrequent in the South, but rare in the North.

Sarcoma of the lid is a rare condition, and develops from something that seems very simple. Dunbar Roy[2] reports the case of an eight year old girl (Fig. 10), who had what appeared to be an ordinary chalazion on the upper lid. It was opened and curretted.

(2) South. M. J. June, 1927.

There was an unusual amount of blood, so some scrapings were taken and submitted for examination. The pathologist said he was not sure it was sarcoma, but he was very suspicious of it. Two weeks later the growth had returned and increased until it was two-thirds underneath the lid. It seemed to be freely movable under the lid and on entering the lid granulation was seen, indicating that the mass had perforated through all the tissues, through the cartilage and through the conjunctiva. Complete excision of the growth was done, removing the cartilage and conjunctiva. Microscopic examination at that time showed spindle cell sarcoma.

Radium and *x*-ray treatment were used. The child had no pain, no irritation of any kind about the eye, and the vision was good. She was treated for three or four months, when the growth returned, and extended a little to each side. She submitted to a second operation, when the growth was removed as well as possible. Radium was put in the cavity and allowed to remain for twenty-four hours.

The healing seemed to be good, and again she was treated with radium for six months. At the end of the year there seemed to be some return of the growth, but the radium treatment was continued. Six months later it seemed that the growth was getting in behind the eyeball, for there was a drooping of the lid and some proptosis. Vision was perfect, but another operation was finally done, radium put in the cavity and allowed to remain for four hours. Radium treatment was used regularly and also *x*-ray, but in spite of it the sarcoma increased in size.

In February, 1917, the patient had some pain about the eyeball, which protruded a little more, and it seemed certain that the growth was down in the orbital cavity, An incision was made around the entire orbital cavity, the lid and eyeball removed, and a perfect exenteration of the orbital cavity was done, scraping down to the

bone. Following this zinc solution was applied in the cavity and the radium and *x*-ray therapy were continued.

A short time later an exuberance of the growth and pain became so intense that the patient had to have anodynes. The case went from bad to worse and in November of that year the child died, with a great mass sticking out of the orbital cavity, and a general sarcomatosis of the skin.

This shows how an apparently simple little thing can produce a widespread malignant condition.

The Conjunctiva and Cornea

The Role Played By Epithelium In Infections of the Conjunctiva and Cornea. An understanding of the modus operandi of any diseased process is essential before advances can be made in treatment. Therapeutics based on a clinical diagnosis without some knowledge of the pathological changes that are taking place is of little value and leads to empiricism.

In the past our conception of inflammations of the mucous membranes has been a hazy one, and we have been unable to explain the reason for an absence of micro-organisms in the secretions in many instances. However, we have not hesitated to treat these cases.

For this reason W. C. Finnoff[3] presents the discoveries of Karl Lindner of Vienna. His observations in ocular conditions might apply to inflammations of the mucous membranes when bacteria seem to be absent.

While studying the conjunctiva in cases of trachoma, Lindner was struck by the frequency with which contaminating bacteria were found in epithelial cells. In the beginning, he attached little importance to this fact, but it gradually dawned upon him that this phenomenon was of importance, and he began to check it with his clinical findings.

(3) Colorado Med., December, 1926.

He observed that in chronic processes bacteria were seldom found in the pus or desquamated epithelial cells. He also noted that early in acute inflammations of the conjunctiva, bacteria were present in the epithelium in great profusion several days before they appeared in the secretion. They were usually confined to the epithelium and were rarely found in the submucosa.

From these facts, he evolved the theory that bacteria which infect the conjunctiva and cornea are epithelial parasites; that they thrive on the epithelium, liberate their toxins and exert their harmful influence from this strategical point.

The bacteria lodge on the surface of the conjunctiva, in one or several places, and form small plaques. If the epithelial cells are resistant, further development of the micro-organism does not occur. But, if the natural immunity of the cells is low, the bacteria multiply, penetrate the cell wall, and in addition invade the cement substance between the cells. As the bacteria grow they produce toxins which through chemotaxis calls out the products of inflammation that are: First, blood serum, then, serum mixed with fibrin and later leukocytes (pus). The exudates come from the blood vessels in the submucosa which is not invaded by bacteria, and pass through the epithelium before reaching the conjunctival surface. In its passage through the epithelial layer the exudates separate the epithelial cells and give the bacteria easy access to the deeper layers. The organisms invade the fissures rapidly and attack the deeper epithelial cells. They may invade the whole layer and cause extensive destruction, or the cells may have enough resistance to retard their progress. The dead epithelial cells and bacteria are carried to the surface by the secretion, and they may then be demonstrated in stained smears. In the early stage, however, the bacteria are so adherent to the epithelial cells that they can not be dislodged and carried to the surface by the secretion. It is only in the advanced stage of the disease that they

can be found in smears taken in the customary manner. Late in the disease they appear from the secretion before the termination of the inflammatory process. However, they can be demonstrated in smears that contain epithelial cells that have been scraped from the surface of the conjunctiva. This is also true of the early stage. Therefore, the popular conception of conjunctival inflammations is probably incorrect. We have believed that the inflammation was due to the bathing of the conjunctiva with infectious micro-organisms and that their presence in the secretion was of great importance. Lindner's findings seem to prove that these bacteria are epithelial parasites and it is to the epithelium that we must direct our attention.

It is not difficult to obtain smears, if one is careful in thoroughly anesthetizing the mucous membrane. In the conjunctiva this is accomplished by two instillations of 4 or 5 per cent cocain by five-minute intervals and one instillation of 10 per cent cocain. In five minutes the lids may be everted, the surface cleansed with a sterile cotton swab and a layer of epithelial cells removed with a sterilized platinum spatula or a scalpel. The best method of sterilizing the instrument is in the flame. In removing the cells one should be careful not to go too deep and draw blood. Bleeding is objectionable because it prevents the making of subsequent smears from other areas and opens channels for deep infection. If bleeding occurs one has passed through the epithelial layer and exposed the submucosa.

The smears may be fixed either by the dry or wet method. For diagnostic purposes, ordinary flaming or air drying before staining is sufficient. Either Loeffler's methylene blue or Grams stain may be used. To study bacteria in the cells one must employ the wet method of fixation, which is as follows:

"The important thing in the technic of wet fixation is not to allow the specimen to dry in the least. Specimens should be transferred to the fixing fluid and from

one solution to the next in an interval of only a second or two.

"The scrapings are spread on a cover glass in the usual manner and the cover glass is quickly placed specimen side down into the following solutions.

Cubic Centimeters

(a) Ten cc. concentrated sublimate solution.
20 cc. 95 per cent alcohol.
Keep specimen in this mixture for one-half hour.

(b) Transfer to 30 per cent alcohol, two hours.

(c) Transfer to 50 per cent alcohol, two hours.

(d) Transfer to 70 per cent alcohol, twelve to twenty-four hours or more.

(e) Transfer to 80 per cent alcohol to which a few drops of Lugol's solution has been added, sufficient to give the solution a slight yellow color, twelve to twenty-four hours. (The Lugol's solution is added in order to remove the mercury in the fixing mixture.)

(f) Transfer to 95 per cent alcohol, twelve to twenty-four hours or more. (If more, change alcohol each day.)

(g) Transfer to the Giemsa or to Lindner's contrast stain for one to four hours.

(h) Wash quickly with absolute alcohol.

(i) Wash quickly with xylol—not necessary to dry afterwards (only shake off excess xylol).

(j) Mount immediately on a slide, upon which a drop of cedar oil has been placed. (Canada balsam should not be used.)

(k) Examine."

It is by the latter method that Lindner and later Howard observed that epithelial cells had phagocytic properties, and that bacteria were digested by them. They demonstrated organisms in various stages of disintegration in the epithelial cells. Jackson stated that this observation is of almost as great importance as the discoveries of Metchinikof, because it proves that many cells are probably as capable as the polymorphonuclear leukocytes, in carrying on phagocytosis.

Quoting Jackson, "The epoch making discovery of Lindner, that the bacteria which cause conjunctivitis are epithelial parasites, is now adequately set forth in English by Dr. Howard. With it is presented, for the

first time, Howard's equally startling observation, that under the stimulus of emergency, the younger epithelial cells of the conjunctiva become phagocytes, and ingest and destroy the invading bacteria, assuming a function hitherto recognized as chiefly belonging to leukocytes.

"But the bacterial poisons, spreading to the deeper layers of epithelial cells, arouse them to rapid proliferation. These deeper layers rapidly thicken until the more superficial cells, carrying their bacterial turf, are thrown off. Meanwhile, the young epithelial cells that replace them are endowed with a certain immunity. They are not favorable hosts for the invading bacteria; and as Howard shows they become phagocytes devouring, killing and digesting the bacteria."

We have known for many years that diphtheria bacilli remained confined to the superficial layers of mucous membranes, but we have failed to investigate further to determine whether other organisms had similar tendencies. Lindner found that, in addition to the diphtheria bacillus, the gonococcus, Koch-Weeks bacillus, Morax-Axenfeld bacillus, the pneumococcus, and others had similar properties. The pneumococcus attacks the submucosa also, but in pure conjunctivitis it is confined to the epithelial layer.

There is no reason why other mucous membranes may not be affected in a similar manner to that of the conjunctiva. Lindner has shown that this is the case in gonorrheal processes in women. He explained the chronicity of gonorrhea by the fact that the epithelial surface that lines the genito-urinary tract is very extensive; and that, while in certain areas the epithelium may become immune to the gonococcus, other areas are susceptible and reinfection occurs. This process has its analogy in the conjunctiva, where relapses after apparent cures are not uncommon. That epithelial immunity to the gonococcus is of short duration has been

demonstrated bacteriologically by Lindner and others. Might not this theory explain some of our obscure infections of the mucous membranes of the respiratory, genito-urinary and intestinal tract?

The Causation of Phlyctenules. Phlyctenules are among the most common affections of children met with in the ophthalmic out-patient department, and though, in the majority of cases, eminently amenable to treatment, are in a minority obstinately recurrent, leaving more or less permanent scars on the cornea which are responsible for a notable degree, not of blindness, but of impaired vision in the general population. The etiology of the disease has long been disputed. Many have held that there is a real connection between phlyctenules and tubercle, though exactly what no one has offered to explain. Tubercle bacilli have never been found in phlyctenules and to say that the affected children are, if not tuberculous, candidates for tuberculosis, does not carry us very far. The same might be said of any poorly nourished children. It is, no doubt, a fact that attention to the diet and nutrition of the child is an important element in treatment, but that does not explain the typical phenomena of the disease.

Bishop Harman[4] has put forward a theory connecting it with decay of the milk-teeth and suggests that the lesion is a herpetiform eruption caused by peripheral irritation of collateral branches of the second division of the fifth cranial nerve in ill-nourished children. So far as we are aware this theory has not received any marked degree of general support and it is obviously inapplicable to many cases that occur. Some new light on the subject is to be gathered from a contribution to a *Festschrift* by the Swedish ophthalmologist, Hugo Laurell, dealing with the pathogenesis of scrofulosis.

Put shortly, this theory is that the bites of human parasites may introduce into the host foreign proteids

(4) Lancet, Nov. 6, 1926.

which give rise to a condition of anaphylaxis, in which any external application of the same, or even of kindred proteids, causes a local reaction of which the phlyctenules are a manifestation. The parasites with which children, subject to phlyctenules, are most commonly infested are first worms, and especially oxyuris, secondly pediculi. Both cause local irritation and scratching, and the conveyance of the offending substance by means of the fingers to the conjunctiva must frequently take place. In dealing with affections so common among the children of the poor, it is obviously difficult to get any statistical proof of the connection between these conditions that is not free from objection. At the same time a perusal of Laurell's article does leave the impression that there probably is some truth in this theory.

At any rate, he has pointed the way to a direction in which research would appear to be hopeful. It is established that phlyctenules can be experimentally produced by the local instillation of tuberculin, or of dead tubercle bacilli in animals already infected with tuberculosis. Funaishi has found that in non-tuberculous animals injected with non-tuberculous bacteria (staphylococci, etc.), instillation of the proteids of these bacteria has a like effect. It is, therefore, clear that tuberculosis is no necessary antecedent to phlyctenular disease.

Laurell's theory is that the subjects of phlyctenules, having been inoculated with the proteids of parasites, usually oxyuris or pediculi, reinfect their eyes by means of their fingers which carry the noxious material from the infected spots to the conjunctiva. If this is a fact one would expect to find phlyctenules more often at the inner margin of the cornea than at the outer. Harman found that 70 per cent were situated in the outer and upper quadrant, the spot to which the orbital branch of the second division of the fifth nerve sends its terminal twig. This is a point which might be reinvestigated.

Trachoma

The Treatment of Trachoma. Trachoma is a chronic contagious disease in which such acute manifestations as occur are the result of superadded infections with well-known bacteria. The cause of trachoma itself is as yet uncertain. It manifests itself in many widely differing forms, all of which are stages in the evolution of the disease, each stage requiring appropriate treatment. A. F. MacCallan[5] divides the disease into four stages, known as trachoma I., II., III., and IV., according to the comparative prominence of the three features —follicles (or granulations), papillary hypertrophy, and connective tissue formation.

In Trachoma I., seen soon after infection has occurred, tiny grey pinhead follicles are sparsely scattered on the conjunctiva of the upper tarsus. Trachoma II. has three subdivisions: *(a)*, in which enlarged follicles predominate; *(b)*, in which a papillary hypertrophy coexists with the follicles (this subdivision is split up into trachoma II. *(b′)*, which is unmixed trachoma, and trachoma II. *(b″)*, which is trachoma complicated by spring catarrh); *(c)*, in which trachoma is complicated by a superadded infection with the Koch-Weeks bacillus, or the Morax-Axenfeld bacillus, or the gonococcus (a common non-venereal conjunctival infection in the Near East). Trachoma III. is the stage in which cicatrization has begun. Trachoma IV. is cured trachoma, in which cicatrization is complete.

Trachoma I.

This stage may be present without causing any symptoms and without producing obvious signs until the lid is everted, when tiny pinhead follicles are seen on the conjunctiva of the tarsus and at the retrotarsal fold, more rarely in the fornix. With a lens or slit lamp may be seen a system of blood-vessels invading the cornea.

(5) Lancet, Oct. 30, 1926.

associated with tiny follicles between the corneal epithelium and Bowman's membrane.

Treatment of trachoma at this early stage is begun by the application of silver nitrate solution 2 per cent, rubbed on the everted lids daily with a pledgelet of cotton-wool wound round the end of a special glass rod. The cotton-wool must be of good quality or it will be impossible to make a neat brush. A fresh rod is used for each eye; after use it is placed in an antiseptic solution and left there until it can be sterilized by boiling. If several patients are being treated the rubber gloved hands should be immersed in an antiseptic solution such as perchloride of mercury, 1 in 1000, in 70 per cent spirit. The action of silver nitrate is not imitated by the organic silver compounds, such as argyrol, protargol, and others. If, when the patient is next seen after a rubbing, there is any coagulum or necrotic material remaining, the next treatment should be postponed until the slough has separated.

If there is much discharge this treatment should be carried out twice a day. The eyelids and the conjunctival sacs should also be bathed with a solution of perchloride of mercury, of a strength, for adults 1 in 5000, for young children 1 in 10,000. The eyelids should be anointed nightly with some ointment.

This treatment must be continued for many months. Under its influence the trachoma follicles may become absorbed without leaving any trace of cicatrization; more usually, however, faint lines of cicatricial tissue are left (stage IV. of the disease). In the majority of cases the treatment is not continued for a sufficiently long period, and trachoma I. passes into II. or III.

It is not necessary or even advisable to neutralize the silver nitrate after its application with salt solution, as this is done quite efficiently by the tears. It is advisable to vary the treatment from time to time. Instead of silver nitrate, cyanide of mercury 1 per cent, copper sulphate 10 per cent, perchloride of mercury ½ per

cent, may be employed. In addition, the instillation t.d.s. of zinc sulphate ½ per cent, or zinc chloride ¼ per cent, may be useful.

It must be remembered that many cases of trachoma pass into the cured stage IV. without treatment of any kind and without any complications; also that monocular trachoma is not uncommon. Treatment by means of a pencil of carbon dioxide snow in this stage may be satisfactory. It must be applied with considerable judgment or serious scarring may result. Treatment by means of radium has been unsatisfactory. Local phototherapy for trachoma has been employed experimentally by means of the mercury-vapor lamp suitably screened acting on the everted lids.

Surgical treatment is not usually indicated in trachoma I.; however, radical cure of the disease may occasionally be attempted, when it is confined to the conjunctiva of the upper tarsus, by means of removal of the tarsus with the diseased conjunctiva overlying it. Subconjunctival injections behind the retro-tarsal fold have been employed. They are attended with considerable inflammatory reaction, and should only be used by specialists.

Trachoma II.

In trachoma II. *(a)* the gelatinous follicles are ruptured, mechanically allowing the escape of their contents. This may be carried out by means of Graddy's forceps assisted by a curette. Excessive bleeding is prevented by thoroughly bleaching the conjunctiva beforehand with adrenalin chloride solution, 1 in 1000. A general anesthetic is frequently necessary, though in a large number of cases a thorough infiltration of the lids with novocain solution 1 per cent, with instillation of 4 per cent cocain hydrochloride into the conjunctival sac is quite adequate; 10 or 15 minutes must be allowed for the anesthetic solution to act.

The upper lid is everted and Graddy's forceps are

applied to the everted conjunctiva and withdrawn, carrying in front of their concavity the gelatinous contents of the follicles which are ruptured by the passage of the instrument. If follicles are present in the fornical conjunctiva, previous to using Graddy's forceps the retro-tarsal fold should be seized with a pair of toothed forceps in order to allow of the lid being re-everted; the fornix is then curetted. The lower lid should be curetted, since unless the conjunctiva is loose Graddy's forceps are not applicable.

Perchloride of mercury solution, 1 per cent, is then applied to the bleeding conjunctiva by means of a pledgelet of good quality cotton-wool wound round a glass rod. If necrosis of the conjunctiva occurs, the use of escharotics should be deferred until the necrotic membrane has disappeared. Otherwise the perchloride should be applied once daily.

Improvement should have occurred at the end of a week, and at the end of a fortnight the commencement of the change into trachoma III. should be observed. At the end of a month a network of cicatricial lines should be seen. This improvement is usually permanent, although in the absence of further treatment relapse is liable to occur with a redevelopment of follicles. The treatment may be supplemented by the use of zinc sulphate drops ½ per cent, or zinc chloride drops ½ or ¼ per cent, bathing with an antiseptic solution such as perchloride of mercury, 1 in 5000, and anointing the edges of the lids with ung. hydrarg. ammon. dil. The mechanical treatment sometimes needs to be repeated after 7 or 15 days. Inevitably some cases develop entropion, seeing that the process of cure depends on the laying down of scar tissue. If inflammatory signs and excessive discharge suggest a superimposed conjunctivitis, no operative procedure should be undertaken. In such cases the conjunctivitis should first be treated with silver nitrate, 2 per cent.

Invasion of the Cornea.—When ulceration from tra-

chomatous invasion of the cornea occurs, silver nitrate, 2 per cent, should be applied to the conjunctiva once or in severe cases twice daily.

The eye should not be tied up except out of doors, but should be bathed by the patient every ten minutes or so during his waking hours with perchloride of mercury solution 1 in 5000, or a weaker solution if the skin becomes irritated. In ordinary cases the pupil should be kept dilated with atropin; but if a perforation seems likely to occur atropin should be discontinued.

Pannus.—Treatment of pannus is for the purpose of improving deteriorated vision, but in advanced cases scar tissue obstructs the nutrient flow between the corneal corpuscles and renders necessary the persistence of pannus vessels. Attempts to reduce the vascularity of the cornea in trachoma are harmful.

When there is great thickening of the tarsus together with the presence of follicles of the conjunctiva, the radical operation of combined excision of the tarsus with the overlying conjunctiva is much the best procedure, provided the conjunctiva of the fornix is free from follicles.

Trachoma II. (b′) may be treated by curetting and application daily of perchloride of mercury 1 per cent, or more satisfactorily by the combined excision of tarsus and conjunctiva overlying the tarsus. This operation may be performed for upper and lower lids.

Trachoma II. (b″) must be treated by the combined excision operation. Even after this it is common for symptoms of spring catarrh to persist.

Trachoma III.

In this stage cicatrization has definitely begun, or is more or less advanced. Islands of inflamed conjunctiva or of trachomatous follicles are seen to be surrounded by a network of fine lines of connective tissue. In this stage spots of necrosis often result from the pressure of the shrinking connective tissue (post-trachomatous

degeneration). The necrotic tissue may remain as a cyst or may become calcareous.

The beginning of this stage is best treated by the application of perchloride of mercury solution, 1 per cent, daily. This may be alternated with the use of copper sulphate solution 10 per cent. The old-fashioned copper sulphate stick is very painful, may cause excessive scarring, and when many patients are being treated carries infected mucus from one to another. In some cases which are not apparently very severe corneal complications occur in the form of small white spots of infiltration situated beneath the superficial epithelium, not staining with fluorescein. Copper should never be used in this condition; daily treatment with silver nitrate solution, 2 per cent, together with frequent skilled hot bathings, and atropin drops 1 per cent, should be substituted. In certain selected cases the combined excision of tarsus and overlying conjunctiva may be satisfactorily performed. This operation has the advantage of curing entropion and of preventing its occurrence, for entropion depends on cicatricial changes in the tarsus; when the tarsus has gone it cannot occur. When the operation is performed with ordinary skill there is never any ptosis afterwards, and from inspection it is impossible to know that any operation has been performed.

The complications of trichiasis and entropion frequently occur in this stage of trachoma. The three operations, Streatfield's, van Milligen's, and Saunders's, for relieving these conditions cannot here be described.

The necrotic foci mentioned as frequently found in this stage merely require opening, and calcareous particles, if present, picking out.

Trachoma IV.—Prophylaxis of Trachoma

Trachoma IV., being the stage of cured trachoma, requires no treatment unless a relapse occurs.

Prophylaxis.—It is impossible here to deal with the prophylaxis of trachoma from a general, social, or institutional standpoint, but a few words must be said as to prophylaxis in the family of the sufferer. If possible, the infected person should have a separate bedroom; in any case a separate bed. He should not use the same washing utensils, nor the same towel or table-napkin. Roller towels should be abolished from the house. All members of the family should have instilled into their eyes as a prophylactic, drops of zinc chloride solution, ½ to ¼ per cent, twice a day. Adequate treatment for the infected person may have to be persisted with for years.

Prophylaxis and Treatment of Ophthalmia Neonatorum. In 1882 Credé suggested the conjunctival use of a 2 per cent silver nitrate solution to prevent blindness in the new-born. This remedy was widely adopted and is still extensively used. Experience has taught us, however, that the silver salt often acts as an irritant and sometimes aggravates the inflammation. These objections were overcome by evolving other silver preparations, notably argyrol and protargol. But, after unlimited use of these substitutes, we are still searching for a successful remedy. In short, the present method of attacking the disease by aiming to destroy the bacteria in situ is a failure, according to Louis Weiss.[6]

Let us consider the subject from another point of view. This writer directs our attention to rendering the conjunctiva unsuitable for bacterial growth. We need, he says, an agent that will make the conjunctiva anemic; an agent that will temporarily suppress but not destroy the normal activity of the conjunctiva; an agent that will lessen the flow of blood, and hence stop furnishing inflammatory material to the affection, as fuel to a fire.

The physiologic effects of cocain used in solution locally on mucous membranes are twofold: the mucous

(6) J. M. Soc. New Jersey, May, 1927.

surface is blanched and rendered anesthetic. After the use of cocain solution in conjunctivitis, an ischemia is produced in the affected area, a starvation of inflammation. The anesthetic effect makes the inflamed area painless. Cocain solution, therefore, is the remedy indicated in ophthalmia neonatorum.

Prophylaxis

The first step is the cleansing of the eye area, which should take place immediately after the birth of the child. It should be performed gently and carefully. Our cleansing should be confined to the outside of the eyelids, their edges and inner and outer canthi, with the eyelids closed. These cleansings should be done with small sterile cotton or gauze wipes. Warm sterile water may be used. No pressure upon the eye should be applied in cleansing the lids.

After the toilet of the eye area has been attended to as suggested, several drops of a 4 per cent cocain solution should be instilled into the lower conjunctival sac of each eye, the fingers being used gently, either to draw the lower lids downward, or to separate the eyelids. The strength of the cocain solution should be 4 per cent, not less; it may be more if desired. Cocain instillations should be made once daily for 7 days, the period in which ophthalmia usually occurs. If the conjunctivæ remain normal, only cleansing is needed thereafter.

Treatment

If, however, ophthalmia or purulent conjunctivitis ensues, the following treatment should be instituted. This will require constant attention for a day or two, or until the affection is conquered.

Every 2 hours, or more often if necessary, instill several drops of a 4 per cent cocain solution into the lower conjunctival sac of the eye, or eyes, affected. Between instillations, have a trained attendant separate the child's inflamed eyelids with the fingers, gently, using

no pressure. When the pus appears at the edges, let the lids close and wipe the expressed pus with a small piece of sterile cotton or gauze, which is then deposited in a waste receptacle conveniently placed. This procedure must be repeated every few minutes, because the formation of pus is continuous.

There is no need for the attendant to press out the pus. The exosmosis, or flow from within outward, which is one of nature's methods of healing, directs the pus towards the edges of the lids. Our duty is to assist the exit of the pus by separating the lids.

If the lids of both eyes are affected, this method is applied alternately to each eye. If the lids of one eye are affected, this method is a protection to the sound eye, because no pus is permitted to reach beyond the piece of absorbent cotton or sterile gauze used as a wipe. The eye area, that part of the face surrounding the eyelids, is thereby kept dry and clean. The child should lie on its back while suffering from ophthalmia, whether the lids of one or both eyes are affected; because the eyelids are then best under observation and can be given the best attention. Since the nose is a natural barrier between the two eyes, no dressing or shield need be applied to cover the sound eye when this method is used. It is advisable to have these wipes prepared in advance.

This method requires more than one attendant. The attendants should work in relays without interruption during the acute stage of the disease, feeding time and other necessary care of the baby excepted. Do not stop while the child is sleeping. Gentle separation of the eyelids will not interfere with the child's sleep. Allowing accumulation of pus under the eyelids during sleep, which may last for hours at a time, may retard healing or lead to serious sequellæ. This strenuous treatment lasts usually from 24 to 48 hours, if instituted at the beginning of the ophthalmia. As the inflammation begins to subside, the intervals of cocain solution instilla-

tions are lengthened, and the sterile cotton or gauze wipes are used less often. Finally the cocain instillations are discontinued, but the daily cleansing of the eye area is kept up with the infant's eyelids closed.

If, after 48 hours the ophthalmia does not show sufficient improvement, hypodermic treatment may be administered. Some prefer autogenous, others stock, vaccines.

If a nasal discharge is present the nose should be cleaned frequently to prevent annoyance to the infant, or it will instinctively use its hands and fingers to spread the discharge into its eyes and thus set up or increase an inflammatory process. Warn the attendants of the danger of cleansing the nose and eyelids with the same cloth.

Cleanliness, well directed and thorough, is imperative at all times in this as in other affections. Frequent cleansing of the hands of attendants, or the rubber gloves if worn, should be insisted upon. All objects, such as cotton, gauze, towels and napkins used in the care of the child, should be either sterile or clean. The water of the baby's bath should not be allowed to contaminate the conjunctivæ. It is the lack of careful cleanliness to which the child is subjected, whether in the parturient canal or out of it, that is an important factor in the cause of ophthalmia neonatorum.

The newlyborn infant must be kept warm from head to foot, with sufficient warm clothing and covers. Warmth maintains the general health, stimulates activity in the tissues, promotes healing and gives comfort. With a comfortable patient treatment is more effective. During the inflammatory stage, the child should be given warm water to drink in abundance. The water may be sweetened. Water dilutes the poison in the system and helps to eliminate it. When the acute stage of the disease has passed, small feedings at intervals of 3-4 hours are advisable. The room should be warm, well lighted and properly ventilated, fresh air entering at

one side only, to avoid draughts. Attention should be given to the infant's bowels. Paregoric, 15 drops, may be given for restlessness.

No cold wet dressings or ice packs should be put on the eyelids in ophthalmia neonatorum. Cold retards healing. Dressings keep the eyelids closed and cause retention of pus, which may be followed by disastrous results. Cold applications to the eyelids may chill the body and predispose the child to pneumonia or other ailments.

Among the other preventive measures, the following may merit attention. Each candidate for a marriage license should be required to present a certificate of health, signed by a physician licensed by the state. The prospective mother should be in the care of a physician as soon as her menses have ceased. As a prenatal measure, daily vaginal douches should be recommended throughout pregnancy. If gonorrhea or some other disease affects the parturient canal it should receive appropriate treatment. The obstetrician should facilitate and stimulate labor, in order to prevent injury and infection of the conjunctivæ from prolonged pressure upon the head and eyelids. Boards of Health should work out a plan to help in the prevention and treatment of ophthalmia neonatorum.

Cocain solution, by blanching the mucous membrane and making it anesthetic, increases the resistance of the conjunctivæ to bacterial invasion, and keeps the affected parts free from pain. Gentleness, cleanliness and care in the method outlined, help this remedy to prevent complications. Cocain solution, as herein applied, is the ideal remedy in the prophylaxis and treatment of ophthalmia neonatorum.

[When we consider the vast decrease in the number of cases of ophthalmia neonatorum under the Credé method of treatment, as compared with the number occurring before its adoption, we are hardly justified in declaring this method a failure. Because of its known

deleterious action upon the corneal epithelium, cocain would seem to us a very dangerous agent to employ in this condition. Holocain or butyn might conceivably be used for this purpose, but it is very doubtful that a method which has undoubtedly saved thousands of eyes in the last thirty-five years, will be abandoned for any method that has not been proved to be superior. —Ed.]

The Lacrimal Apparatus

Mumps of the Lacrimal Glands. Mumps is a systemic disease, which, though typically associated with parotitis, may produce localized phenomena elsewhere, with or without a co-existing affection of the salivary glands. Orchitis, mastitis, pancreatitis, arthritis, encephalitis, meningitis and ocular affections are among the complications at times encountered. That the orchitis of mumps may occur in the absence of parotid gland involvement has been definitely established; and recently it has been demonstrated that the meningoencephalitis of mumps may likewise occur independently, and as the only manifestation of the disease.

The ocular complications of mumps may be very serious. The diagnosis is oftentimes puzzling, for not only is the involvement of the eye in mumps uncommon, but the relationship to the disease may be by no means apparent. If the eye becomes affected, it is generally at a time when the usual symptons of mumps have begun to subside, that is, at the beginning of convalescence or within a few weeks subsequent to the attack.

In reviewing the literature on this subject, Lebensohn[7] finds that the first recorded observation of ocular involvement in mumps was made in 1872 by E. Ryder, who reported two cases of dacryoadenitis. This was followed in 1876 by a report of Hatry of 10 instances of neuro-retinitis. Since then other ocular complica-

(7) Illinois M. J., March, 1927.

tions have been noted. In a resume of the literature in 1894, J. H. Woodward collected 23 cases of neuroretinitis, 14 of dacryoadenitis, 6 of optic atrophy, 6 of iritis, 3 of retrobulbar neuritis, 3 of paralysis of the intrinsic or extrinsic ocular muscles, and 2 of keratitis.

The lacrimal gland involvement in mumps, like that of the parotid, is bilateral, and almost never suppurative. The palpebral portion of the gland is that most affected. The process begins acutely with pain, redness, and swelling of the outer extremity of the upper lid and conjunctiva. The upper lid droops, the gland is very sensitive; the enlargement is readily felt and the skin overlying the mass is freely movable. On elevating the lid the lower part of the swollen gland becomes visible, but eversion of the lid is quite painful.

Bilateral dacryoadenitis is rare, and outside of mumps may be caused by influenza, rheumatism, smallpox, and leukemia. Metastatic dacryoadenitis in gonorrheal patients has been described. Tuberculosis and syphilis may affect the glands but only exceptionally.

Unilateral dacryoadenitis occurs more commonly than the bilateral forms, and may follow injury or be secondary to diseases of the conjunctiva or cornea.

Mikulicz' disease must be considered in this connection. In this affection there are bilateral lymphomata of the lacrimal, parotid, and submaxilary glands. No pain is present, no derangement of function, and no demonstrable systemic disturbance.

Though the majority of patients with mumps are between 5 and 15, there is no immunity with advancing years, but merely a diminished susceptibility. Individuals of 60 and 70 have been affected.

Case Report. A male negro, stockyards worker, aged 26 years, reported to the Illinois Charitable Eye & Ear Infirmary for a painful swelling in both upper lids of two weeks' duration. The palpebral portion of both lacrimal glands was markedly enlarged and indurated. The tissue about the ducts was palpable as

discrete nodules. His general health was otherwise excellent. He remembered no recent diseases, such as mumps, influenza, or other systemic disturbance. The blood Wassermann taken previously had been found negative. The test was repeated with a similar result. The blood count was normal. Vision was 20/20 in each eye, and the media and fundi showed no pathology. A bit of tissue from the right lacrimal gland removed under local anesthesia revealed but a simple inflammatory reaction.

As possible causes of this condition, influenza, rheumatism, gonorrhea, leukemia, smallpox, syphilis, tuberculosis and Mikulicz' diseases were considered and ruled out. The presumptive diagnosis became narrowed down to mumps. That the patient did not remember ever having had mumps previously supported this view. The treatment consisted of iodine-petrogen applied locally, hot compresses, potassium iodide internally, mercury rubs, and daily catharsis with sodium phosphate. After three weeks of this management the swelling almost entirely disappeared, and the patient was discharged from treatment.

The Cornea

Ulceration of the Cornea Due to Bacillus Pyocyaneus. *Bacillus pyocyaneus,* like many micro-organisms, is occasionally found in a purely saprophytic state; Koch, in earlier studies, declared it to be an organism incapable of playing a pathogenic rôle. However, in certain strains, marked virulence has been noted. Infection of surgical wounds, otitis media, urinary infections, meningitis and pneumonia are the most frequent. The first eye case was reported in 1891 by Sattler. W. T. Garretson and K. W. Cosgrove[8] report an epidemic of sixteen cases originating in the same industrial plant.

First aid care and treatment were given, including

(8) J. A. M. A., Mar. 5, 1927.

removal of adherent foreign bodies, foreign body stains and loose foreign bodies from the cornea and conjunctival sac. Irrigation with a 4 per cent boric acid solution and instillation of 10 per cent neosilvol followed removal in each case. A pad was placed over the injured eye for twenty-four hours. The ulcers developed from one to four days following the injury. In this series, three cases did not present an abrasion of the cornea which could be recognized microscopically. The remaining injuries were not of a penetrating nature. Small particles of emery or débris were adherent to the cornea, which resulted in loss of epithelium. In rabbits infection of the cornea was not possible by inoculation of an abrasion produced experimentally. To obtain similar serious sequelæ, the bacteria had to be injected between the layers of the cornea. In an attempt to discover the source of the infection, a careful survey of the positions held by the men was made. Only two were working in the same part of any building (foundry). Another two men were from the same department. The remaining men were scattered over the plant in widely separated buildings.

The only place where all the men had congregated was the first aid hospital. A careful survey made here did not unearth any definite focus. Cultures taken of the boric acid used were negative. That *Bacillus pyocyaneus* will live in 4 per cent boric acid was proved experimentally. We have therefore to assume that the boric acid was the most likely focus. Careful surgical technic and cleanliness were instituted with no further cases developing. Between three and seven days from the date of injury, all patients complained of lacrimation, photophobia and pain. Examination revealed deep sloughing ulcerations of varying sizes. The base of the ulcer was covered with exudate and débris. Around the infected areas a ring of clouding of the cornea existed extending about 2 mm. The exudate, present in large amounts, was of a fibropurulent nature with a slight

grayish tinge. Circumcorneal injection associated with mild iritis was present in some cases. All cases showed marked hyperemia of the bulbar and palpebral conjunctiva. The dirty appearance of the ulcers associated with the large amounts of exudate differentiated them from the ordinary pyogenic or catarrhal ulcerations.

Primary treatment consisted of actual cautery, by which means the overhanging edges and sloughing bases were sterilized. This was immediately followed by 68 per cent phenol (carbolic acid) neutralized in two or three seconds with 95 per cent alcohol. The eye was then irrigated with boric acid. An ointment of a mercury salt was instilled into the conjunctival sac before the patient returned to his room. In several cases this treatment had to be repeated one or more times before the activity was halted.

The eyes were treated subsequently with irrigations of 4 per cent boric acid solution every one or two hours. This was carefully done with the intention of cleansing the base of the ulcer and freeing the cornea from reinfection by its own exudate. The mercury preparation was instilled into the conjunctival sac after each irrigation. A 1 per cent solution of mercurochrome-220 soluble was used three times a day. Cold compresses were applied by the patient himself continuously. As in all eye infections, atropin was used in a 1 per cent solution three times a day.

When the activity of the ulcer decreased, thereby decreasing the exudate, the boric acid and the mercurochrome were discontinued to prevent secondary irritating effects. The course of the ulcers varied with the size and length of time before radical treatment was instituted. Activity varied from three to twenty days. When the activity subsided a period of repair followed, lasting from four to fifteen days, varying directly with the destruction. During the latter period, mercuroform ointment was the only medication.

In three cases, perforation of the cornea occurred within from seven to eleven days. A conjunctival flap was sutured over the cornea, with complete healing in two cases. In the remaining case, because of persistent fistula and recurring uveitis, the eye was enucleated.

Keratitis as a Complication of Dengue Fever. Dengue has occurred in the United States as an epidemic ten times since 1779. In Florida during the months of July, August, September and October, 1922, the State Board of Health estimated that there were 82,681 cases, while in the City of Jacksonville alone there occurred approximately 20,000 cases.

The literature reveals a mass of references to the ocular symptomatology of dengue and, in a few instances, complications are recorded. In nearly all of the general descriptions of the disease, mention is made of the ocular symptoms occurring during the acute stage but most authorities pay little attention to the ophthalmological phases and their significance. Manson's "Textbook of Tropical Diseases" disposes of the subject with the following terse statements: "The head and eyeballs ache excessively;" "The face, particularly the lower part of the forehead, round the eyes and over the malar bones, may become suffused with a deep purple;" "The eyes are usually much injected."

Elliott in his text on "Tropical Ophthalmology" devotes only a few paragraphs to the eye manifestations of dengue, mentioning that such complications as keratitis, iritis, irido-choroiditis, amaurosis, and muscular paralysis have been ascribed to the disease.

Santos-Fernandez, writing on "Ocular Manifestations in Dengue" in 1900, says that he has not heard of any special study of the ocular manifestations of dengue. Such manifestations have been observed, but only mentioned incidentally. In common with others, this author notes pain in the eyes, and sometimes photophobia as characteristic symptoms of the early stages of the disease; the eyes appear "brilliant and con-

gested'' at this stage. During convalescence, some diminution of vision has been noted, which is due to paresis of the muscle of acommodation. Hyperesthesia of the retina has been noted manifesting itself as special alteration of vision so that all objects appear as of a red or yellow color.

Barkan has reported a case of paralysis abducens and of accommodation following dengue.

Shaler Richardson[9] whose interest in the ocular manifestations of dengue fever was aroused during the epidemic which visited Florida and other Southern states in 1922, saw many patients presenting eye complications, during and subsequent to the infection. He finds no mention in the textbooks of dendritic or vascular keratitis complicating dengue, but in his own experience, six cases of keratitis were seen, all of which occurred in the first week of convalescence. In each instance, it was definitely established clinically that the patient had suffered with dengue. Four of the cases were of the typical dendritic variety, the corneal lesions assuming a characteristic arborescent conformation. The remaining two cases were of the vesicular type, the lesions never coalescing. Iritis or hypopyon did not complicate any of the cases. Partial anesthesia of the cornea was observed in three of the patients, while the other three cases had unimpaired corneal sensation. In all instances, the corneal lesions were unilateral. Great stress was made of the ocular discomfort occurring during the acute stage of the disease by each of the patients. Smears and cultures failed to reveal anything. Three of the patients were relieved within two weeks with no impairment of vision. One case persisted over a period of three months, vesicles forming in successive crops and ultimately the vision was reduced from 20/30 to 20/70 because of a central opacity that resulted. Two cases were of three weeks' duration and terminated with

(9) South. M. J., January, 1927.

a very slight reduction in vision as a result of nebular opacities.

Ocular symptoms in the active stage of dengue were in most instances very prominent. The patient usually complained of an intense aching of the eyeballs and supra-orbital neuralgia. There was a sense of tension within the globe and the slightest movement of the eye produced great discomfort. Lacrimation and photophobia were characteristic and frequently patients were only comfortable in a darkened room. Burning of the eyes with a feeling of sand under the lids was often complained of. Objective examination during this stage often revealed blepharospasm, injection of the ocular and palpebral conjunctiva, this being so intense at times that an acute conjunctivitis was simulated. However, in none of the cases seen were organisms found in the smears or cultures that could account for the injection. The ocular tension was consistently normal, as were the pupillary reactions and ophthalmoscopic findings. Three cases of herpes of the eyelids were seen, one of them occurring in the above mentioned cases of dendritic keratitis. Two of the cases showed herpes of the lips and in one, in addition to the lesion of the lip, there was involvement of the alae of the nose. In all the cases the herpes were unilateral.

Most of the ocular manifestations noted in dengue fever suggest the possibility of an involvement of the fifth cranial nerve. Could this not be a toxic Gasserian ganglionitis, or is it a terminal fiber involvement? On the other hand, we must consider seriously the thought that the keratitis noted may have been due to a form of herpes simplex, and possibly the inoculation of animal corneas with serum from these vesicles would have established this fact.

Translucency of the Cornea. Opacity of the cornea is a common cause of impaired vision in every degree from the slightest defect of sight to complete blindness. It is, therefore, important to understand what causes

corneal opacities and how far they are curable. The anatomical structure of the cornea consists of parallel fibrous lamellæ bounded on the outside by an epithelium and on the inner side by an endothelium, which normally protects it from infiltration by the aqueous humour. Slight opacities may be caused by injuries to the epithelium but this is soon regenerated and complete transparency may be restored.

Infiltration of fluid into the substantia propria may be due to pressure as in glaucoma or to disease such as interstitial keratitis. In this case the infiltrating fluid contains cells and the opacity may be extreme. Nevertheless the infiltration may eventually be completely or almost completely absorbed and the transparency of the cornea restored.

A third type of corneal opacity occurs from actual injury of the fibres of the substantia propria such as results from a deep ulcer or a wound. Here the opacity may be partly due to infiltration and, in so far as this is the case, treatment by such things as stimulating ointments may be partially effective, but there remain the cases in which there is actual replacement of the normal fibres of the cornea by scar tissue. In the worst cases such as follow a severe ophthalmia neonatorum the whole cornea may be converted into scar tissue, and in these no treatment which has hitherto been devised can possibly restore the transparency.

A suggestion has been made by S. G. Moore,[1] who has seen the wonderful specimens prepared by Prof. Spalteholz, of Leipzig, in which the tissues are rendered so translucent that, for example, injected arteries are readily seen in relief in transmitted light—that this process, applied to living tissues, might restore some measure of useful vision in cases of blindness due to opacity of the cornea. This process consists in impregnating the tissues with a fluid of suitable refractive index, composed of oil of wintergreen and benzyl benzoate.

(1) Lancet, Oct. 9, 1926.

Plastic Repair of Perforation of the Cornea. In this operation, devised by Rea,[2] which is a modification of Kuhnt's keratoplasty, the conjunctiva is dissected from the limbus around half the circumference of the cornea, a straight incision is made through the conjunctiva from 4 to 6 mm. from the limbus, the walls of the perforation are carefully scraped, and the loose strip of conjunctiva is drawn over the wound and held by a suture on either side of the cornea.

The lids are then kept closed for ten days, during which time the conjunctiva becomes adherent to the wound and new vessels grow into the substantia propria of the cornea, supplying the graft which fills the wound. The conjunctiva shrinks away, leaving only the denuded area covered. This is cut away with blunt pointed scissors. The lids are then closed for two days. When they are again allowed to move freely it is seen that there is a supply of blood vessels growing from the limbus through the cornea, supplying nourishment to the graft. As the latter shrinks in size the vessels disappear.

This operation is used in cases of perforation by trauma, phlyctenular ulcers, and septic ulcers.

The Iris

An Explanation of the Arygll-Robertson Pupil. The Argyll-Robertson phenomenon was first described by Argyll-Robertson in 1869 and refers to the condition in which there is abolition of the direct and consensual pupillary reaction to light incidence in both eyes, while the reaction to accommodation is found to be normal.

Its importance lies in its connection with certain diseases which, as Babinski first pointed out, are the consequence of syphilitic infection. Anton Lutz, however, states that there is no doubt that the typical Argyll-Robertson phenomenon is very exceptionally found

(2) Proc. Roy. Soc. Med., 1926, XIX.

in certain non-syphilitic diseases: *sclerosis multiplex, syringomyelia, atrophia muscularis spinalis progressiva, neuritis interstitialis hypertrophica, ataxia hereditaria, alcoholismus chronicus gravis* and diabetes and often in certain traumatisms of the skull. But these are rare exceptions.

The importance of the phenomenon is still further emphasized when it is realized that it can precede a metasyphilitic disease for several years and can be during that time the only sign of syphilitic infection. It always developes very slowly and after having appeared, remains, as a rule, permanent. Again it is almost always found in both eyes, but there are rare cases in which it occurs only on the one side and in these it is mostly the precursor of general paralysis.

Although this reaction is now well known and its importance is usually well recognized, its explanation from a neurological point of view has been difficult. So far most of the controversy has centered around the question of why the light reflex is abolished, but it is now generally agreed that the light reflex path is interrupted in the mesencephalon in the region of the aqueduct of Sylvius, where a lesion of small dimensions can interrupt the connection between both *superiores colliculi* and the *nuclei photomotorici* on both sides.

While it appears that our views as to the cause of the abolition of the pupillary reaction to light incidence in this phenomenon have now become very definite, yet up to the present no satisfactory explanation has been put forward as to why, at the same time as the reflex to light is abolished, the reflex to accommodation remains unaffected.

Herbert J. Wilkinson[3] has conducted a series of experiments which seem to show that lateral rotation of the eye is associated with momentary pupillary dilatation in the same eye and that medial rotation is similarly associated with momentary pupillary contraction in the

(3) M. J. Australia, Feb. 19, 1927.

same eye. These facts tend to support the hypothesis that sensory stimuli, set up by the movement of the eye, may reflexly cause changes in the size of the pupil. It is, therefore, suggested that the sensory limbs of the reflex arcs, concerned in reflex contractions of the pupil on accommodation and to light, travel by entirely different afferent pathways and that this forms the neurological basis of the explanation of the Argyll-Robertson pupil. In central syphilis a lesion in the region of the aqueduct of Sylvius breaks the arc concerned in reflex contraction of the pupil to light only and the arc associated with reflex contraction of the pupil on accommodation is not affected, as it does not lie in relation to the damaged area at all, but passes *viâ* the oculo-motor nerves to the third nucleus.

Recurrence of Iritis as Influenced by the Removal of Infections. In 1916 and in 1923 E. E. Irons and E. V. L. Brown[4] reported two series of 100 cases each of iritis, in which careful studies of each patient were made to determine what kinds of infection were present and the probable cause of the iritis. The infections found were removed, so far as possible, and the effects on the eye noted. From these studies, as well as from experiments in animals, it seemed evident that iritis is frequently caused by infections in other parts of the body. From three to twelve years have now elapsed since these patients were studied, and they now present a summary of the first fifty cases from which they have been able to obtain reports with reference to recurrence.

In forty-three of fifty cases there were no recurrences of iritis after the removal or adequate treatment of infections found and believed to be the cause of the iritis. In four others in which there were recurrences, the infections were known not to have been removed. In one of the three remaining cases, in which old quiescent pulmonary tuberculosis was found, they were unable to locate other infections; and, although they had ample

(4) J. A. M. A., Oct. 9, 1926.

opportunity for study and carried out extensive examinations and treatment, the process went on to blindness. In another, primarily due to sinus infection, the eyes were quiet when last seen, but some years later recurrences led to blindness. In the remaining case there was a local tuberculin reaction; the cause of iritis was undetermined, and restudy was not allowed.

As freedom from recurrence is an evidence of the etiologic relation of infections to iritis, this series emphasizes the importance of thorough examination and removal of infectious processes in iritis.

The Crystalline Lens

Lenticular Opacities. Primary inflammation of the lens, or phakitis, does not occur, though secondary invasion by inflammatory cells may take place from surrounding parts.

Recent studies by the slit lamp have given us a vast amount of valuable practical information on this subject, especially in the way of working out a more exact diagnosis. It has demonstrated that opacities exist in all crystalline lenses. So all are not pathological. It is not essential, however, as it only amplifies and renders more accurate the diagnosis worked out with the ophthalmoscope and with oblique illumination.

The decrease in the acuity of vision, caused by lens opacities, cannot be correctly estimated until any refractive error that may be present has been corrected.

It is a great mistake to tell our patients who have very slight haziness of the lens, or with opacities which are not likely to progress or which may disappear with proper treatment, that they are doomed to more or less complete blindness before anything can be done. The diagnosis of this condition should never be announced without most careful investigation.

Lenses of aged people reflect so much light as to give a milky appearance which is intensified in the presence

of absolute hyperopia. A correcting lens in such cases brings about normal vision, and the ophthalmoscope the usual red reflex.

The lens can be thoroughly studied only after complete dilatation of the pupil, care always being taken not to mistake small white deposits, caused by cyclitis, for those of the lens itself.

The study of the pathology of the lens is not an easy one, although many thousands have been removed. The operative process mixes up capsule, cortex, and nucleus so that we do not get a clear picture of the conditions as they exist in the living eye before removal. The introduction of the corneal microscope and slit lamp is aiding us now greatly by affording us the opportunity to study pathology of the lens in the living subject. The lens never was an easy subject for sectional study, but the slit lamp enables us to see the lens in profile exactly as though the section had been made with a knife.

Cataract is not a disease, but a symptom. It is met with at all ages. It is associated with many diseases, and the possibility of dealing with it successfully in the stage of incipiency is constantly becoming more apparent.

Oculists of the country are becoming intensely interested in the importance of treating lens opacities in their early stages. There is a growing feeling among our most studious ophthalmologists, who are proud of the fact that they are usually able to relieve eye defects without interfering with function, in favor of this line of treatment and for this reason to use operative procedures as a last resort. In this they differ from the general surgeon whose surgical procedures are so frequently along the line of amputation.

During the past few decades our leading ophthalmologists of all nations have had their minds so completely taken up devising better technic for removing cataracts, with or without iridectomy, with or without capsule, that the causes, hygiene, and treatment of lens opacities have been sadly neglected. Operative procedures, for

the removal of cataracts, have been worked up to such a high degree of excellence that if a single eye is lost in one hundred extractions, we feel quite certain that some one has blundered. The losses that do take place are nearly always due to some local or systemic condition which could not be removed.

There is a strong tendency to underrate the importance of local treatment. Those who condemn such treatment are those who have not used it faithfully or made a thorough study of its applications. We are all aware that opacifications of the lens clear up spontaneously, but, according to J. F. Fulton[5], who writes at length on this subject, if these cases were carefully studied it would be found that the fortunate result is associated with improved hygienic conditions resulting in better health. Eighty well-authenticated cases have been reported of spontaneous absorption of senile nuclear cataracts. Does this not encourage us to hope that a line of treatment may be worked out that will enable us to accomplish what Nature has done in these cases without our assistance?

In order to treat lens opacities intelligently we must study carefully their causes. With this subject we are not so familiar as we should be.

Defective correcting of errors of refraction, or failure to correct them at all, is an important factor in the causation of lens changes. Most ophthalmologists of vast experience stress the importance of looking very carefully after refractive errors. Kirkpatrick suggests that the zonular fibres during accommodation sometimes produce areas of uneven capsular pressure, resulting in injury to the lens. That distressing condition known as spasm of accommodation is a frequent causative factor in bringing about lens opacities. That defective calcium metabolism is one of the causes of a certain form of cataract as indicated by the presence of calcium crystal found in the lens.

(5) Journal-Lancet, Nov. 15, 1926.

The author's treatment of incipient opacities is very simple, but quite satisfactory on account of its efficiency. Sixty per cent of all cases of opacities coming before us in the early stages can be checked, improved, or cleared up entirely by the proper treatment persistently applied and followed out. It consists in the use of two remedies: cyanide of mercury and adrenalin.

The vast majority of acquired cataracts that go on to complete development, requiring extraction, start in the nasal quadrant of the lens. This condition should be carefully looked after in every case of refraction correction, especially if they are approaching the presbyopic age. If the least bit of haziness is in evidence, treatment should be immediately commenced. The patient is given a solution of cyanide of mercury, 1 to 1,500 to be dropped into the eye three times a day. The cyanide of mercury stimulates the lymphatic circulation of the eye, having a favorable influence upon the lens lymph as well as that of the whole anterior section of the eyeball. He applies a stronger solution of the same remedy, rubbing it into the posterior folds of the conjunctiva, together with a solution of adrenalin. The adrenalin seems to have a powerful therapeutic effect, most favorable in these cases. Occasionally, in obstinate cases, it is necessary to inject the cyanide solution under the conjunctiva, or it may be injected into the orbit structures. This treatment is kept up for two weeks at a time, and then the patient is directed to return in a month, when the treatment will be resumed, according to lens conditions.

Of course, this is understood: that at the time of commencing the eye treatment a very careful diagnostic examination of the patient is made so as to locate any septic focus or any constitutional condition that may be a causative factor in producing the lens opacity.

With the advent of an industrial medicine era, electricity and heat have become prominent factors in the production of cataract. A number of cases have been

reported lately of serious lens opacities having been produced by lightening and applied radiation. The changes in the lens produced by electricity are somewhat characteristic. The anterior part of the lens is affected primarily; this extends into deeper parts later and usually associated with burns of the face and lids.

We read in literature considerable of glassblowers' cataract, which more accurately should be called heat-produced cataract, as smelter workers and those engaged in laundry work, and many other similar occupations, suffer eye injuries of this nature. All of the authorities seem to agree, however, that the excessive heat brings about this condition by its action on the ciliary body, thus interfering with the nutrition of the lens.

There is a great similarity in the production of the opacities of the lens and cornea, both, as a rule, being the result of disease or trauma, and the principles of treatment and results are about the same. When persistently carried out, the results are usually satisfactory. Success in treating both depends in relieving the cause first and the persistent application of local and protein treatment, associated with constitutional, whatever it may be.

The leading French ophthalmologists, especially Badal and Dor, have given medical treatment of cataract considerable attention, and report most encouraging results. Their remedies are slightly different, for the reason that each one directed his therapeutic agent to a different stage of the formation of cataract. Dor demonstrated that cataract was the result of hydration of the lens. Badal assumed that cataract was due to dehydration, which condition is simply the later stage of the former. The remedy which they recommended, calcic-alkaline, is unquestionably a very valuable therapeutic agent.

Cataracts are one of the most common complications of diabetes. Unfortunately, they make their appearance during the later stages of the disease and are, pos-

sibly, not so favorably influenced by the marvelous therapeutic agents which we now have for the control of that disease.

There are two forms of diabetic cataract, one coming on rapidly in the young, the other forming slowly in the adult. Very frequently the approach of this condition is indicated by a rapid development of myopia, running as high as 7 diopters. This increases and decreases in proportion to the sugar output. Local treatment is useless, lens usually becoming completely opaque, demanding extraction. It is claimed by the use of insulin, lens complications are growing less frequent and operative procedures safer. Fortunately, the operative procedure for the removal of diabetic cataracts is just about as successful as that of removing any other form. At times it is impossible to make out the difference between this and so-called senile cataract.

Traumatic cataract demands our most careful attention. Small opacities occasionally disappear or may be so located as not to interfere with the acuteness of vision and remain permanent. A very interesting and somewhat unusual result of trauma applied to the eye is the Vossius ring. It is best seen with the ophthalmoscope. It is a round reddish ringlike formation on the anterior capsule, about the size of the pupil, consisting of blood and pigment. Sometimes the small grayish ring appears inside of this. They both usually disappear without damage.

The successful reports from the result of treatment, made by many others, are numbered by the hundreds and as high as a thousand by one of our greatest teachers.

Very encouraging reports come to us now for the treatment of cataract by means of lens protein. Experimental investigation is being carefully worked out in some of our most reliable medical centers. It is hoped it may become an immunizing agent. At the present time, however, the beneficial effect seems to be that of other foreign proteins. In the hands of those familiar

and skillful in its use, most encouraging results have been obtained in the treatment of cataract. This good result is obtained by stimulation of the involuntary nervous system, and of the bone marrow system, and an increase of the flow of the leucocytes to the affected area with increased activity of the lymphatic system and permeability of the vascular walls.

In regard to the best procedure for immature cataracts in the aged after they have developed to an extent which seriously interferes with function, the author recommends performing a preliminary iridectomy and massaging the anterior capsule of the lens, followed by extraction later.

When this class of patients have their vision reduced by an unprogressive lenticular opacity to 20/100, they can sometimes be greatly aided by the use of carefully worked out telescopic glasses.

So it becomes apparent as we carefully investigate this subject that the prevention and cure of lenticular opacities require the combined work of the physiologist, the biochemist, the general practitioner, and the oculist. The ophthalmological clinician who does not study and treat lenticular opacities is not practicing modern ophthalmology, and the day is near at hand when opacification of the lens, requiring extraction, will be as rare are trachoma, ophthalmia neonatorum, and sympathetic ophthalmia.

Cataract Extraction. A few suggestions are offered by Melville Black,[6] to physicians who refer cataract cases to the oculist for operation. If the patient has a fully matured cataract in each eye and has good perception of light in all parts of the visual field, the operation is indicated, providing there are no physical conditions which contraindicate it. If the cataract is mature in one eye and immature in the other, the amount of vision in the better eye will determine whether an operation is indicated. If the patient is able to read with one

(6) Colorado Med., July, 1927.

eye, it is better to defer sending him to the hospital until he is able to do this. The reason for this is that he will be unable to use the operated eye while he has useful vision in the other one. If a cataract glass is placed before the operated eye while the other eye has good vision, double vision and confusion will result. It is best, therefore, to wait until the vision of the better eye is reduced to enter into the visual act sufficiently to cause disturbance. With old people who, at best, have only a few years to live, it is good policy to postpone operating so long as they have one eye functioning enough to enable them to get along. Some acute process may come up at any moment and result in death, which automatically adjusts everything.

Before cataract patients are referred to us for operation, the question of general physical conditions, which might have a bearing upon the success of the operation, should be gone into by the home physician. Diseased teeth, pyorrhea, dead teeth and old dead stumps, should be attended to at home and the patient's mouth cleaned up and rendered free from infection. The patient should not be sent to us until at least a month after this has been done. For us to extract the teeth and to wait until such mouths are clean means unnecessary hospitalization, with corresponding unwarranted expense to the county and state.

The question of operating upon more than one eye in an old person is a debatable one. Aged people do not bear any kind of an operation well and any unnecessary operating is contraindicated. If the operation upon one eye is successful, his advice is to let the other eye alone. A person can see to read and to get about almost as well with one eye as with two; the only thing is stereoscopic vision. Stereoscopic vision is difficult to acquire when both eyes have been operated upon and, unless the patient is in the fifties, it is not worth while to subject him to two operations.

It is not advisable to operate upon both eyes at the

same time. It is better to have the experience with one eye to guide us in the management of the other.

The presence of diabetes always presents a formidable physical obstacle to healing after cataract extradition. It is always desirable that the home physician examine the urine for sugar. If present, the blood sugar should be estimated and the patient put on insulin, in appropriate doses, until the blood sugar is down almost to normal. If such patients come to us and we discover diabetes, it means weeks of insulin treatment before operation is safe.

People who are inclined to be "flighty" at home, who are difficult to manage and who are very senile, make poor risks from a cataract extraction standpoint.

Cataract mania is a most undesirable thing after such an operation, where absolute quiet and rest are essential to a perfect healing of the wound. If a patient has to be confined in a strait-jacket in order to control him, the operated eye is almost sure to be lost. The home physicians are familiar with the nervous condition of a patient. It would help some if we were warned by the physician who refers an erratic, unreliable, nervous patient.

Extraction of Lens Entire in Capsule Without Iridectomy. A slight difference in the technique of cataract extraction is described by Daljang Singh Khanka[7]. He makes a sclero-corneal incision about one-third of the circumference leaving as little cornea near the base of the iris as possible. Without cutting the iris the lens it taken out entire within its capsule. This entire iris is pushed out by the outcoming lens, and it spreads itself over the sharp edge of the inner margin of the cut cornea like a blanket, so that the sharp edge cannot cut the capsule in its outward journey, and thus helps the removal of the lens entire in the capsule. In those cases in which the iris is cut the accident of the rupture of the capsule happens oftener than it is ex-

(7) Practitioner, May, 1927.

pected, simply by its rubbing against the naked, sharp edge of the cut cornea. There is no chance of the iris being caught in the corners of the incision in the cornea, as is occasionally the case with those cases in which the iris is cut.

After the operation the corneal flap is raised up just a little to make sure that the iris is snugly lying flat on the surface of the vitreous without any tendency to a prolapse, and the eye is shut and bandaged. The patient is advised to sit up and not to lie down for six hours, to provide against the chances of prolapse of the iris for the following simple reason. In the position of lying on the back the aqueous humour collects inside the anterior chamber and makes the iris float upwards, and as the wall is weak at the incision, the internal pressure all around the iris tends to bulge it out at the base into the incision and thus favours prolapse. In the sitting position the aqueous fills the anterior chamber from below upwards, and its level rises gradually upwards; thus there is fluid on both sides of the iris which hangs like a vertical curtain, and any more accumulation, instead of pushing the iris out from behind, finds a natural, easy passage, on the lines of the least resistance, into the incision without disturbing the iris. This has been proved by the results in actual practice; after the wound has united the pupil is central and there is no lens matter left.

Facoerisis. Facoerisis consists in grasping a cataract with a suction apparatus and removing it within its capsule, leaving a clean, round, black pupil. If this method can be accomplished without complications and without a full iridectomy, one would think it should be the operation of choice, as it can be performed without waiting for the cataract to ripen, eliminates secondary operations, lessens prolapse iris, and is practically free from post-operative inflammation. Some claim it has a special technique, but the difference between facoerisis

and other methods of operation appears to be only in the mode of grasping and removing the lens.

In the hands of Barraquer, who has brought the technique of facoerisis to its greater perfection, the operative manipulations have become a matter of routine, and are carried out with a very small percentage of complications; but such facility and such a large practice in this method cannot be easily acquired by the average ophthalmic surgeon.

If a method could be devised to familiarize surgeons with the suction apparatus, apart from practicing upon human eyes, the operation would become as simple as other methods. W. A. Fisher[8] believes this experience can be obtained by removing the lens of a chicken, placing it upon a table and practicing manipulation with the suction apparatus. Machines devised for removing cataracts by facoerisis should be mastered, if possible, before operating upon human eyes. All seem dangerous at first, many skillful operators rightly hesitating to work in this manner, but fear lessens as skill is gained with practice upon the chicken lens.

Ophthalmic surgeons are looking for some practical intracapsular technique since so much has been written recently regarding post-operative inflammation following the capsulotomy operation. Operators have known for a long time that clinically, post-operative inflammation occurs more frequently after the capsulotomy than after intracapsular methods.

As a result of his own experiences in operating upon more than 2,500 eyes by the intra-capsular method, and from the reports of a number of other operators by the same method, Fisher concludes: that

Facoerisis if properly done seems to be the best operation for all kinds of cataracts, except dislocated lens, but it must be emphasized that it is not as simple as capsulotomy. Complete anesthesia, paralysis of the orbicularis, efficient lid control and a good light are

(8) Illinois M. J., February, 1927.

necessary, and are also desirable in any method of operating.

Post-operative inflammation seldom follows an uncomplicated facoerisis operation.

Detention in the hospital is reduced.

The technique of facoerisis is simplified by practice upon chickens' lenses.

Six weeks old kittens give quite good practice for the capsulotomy method and also for the Smith, Knapp, Torok, Verhoff, Wright, Sinclair and Fisher intra-capsular methods.

Facoerisis operators should be familiar with, and favorable to, the Smith operation, because it is usually quite necessary to employ the Smith Technique if a complication occurs while doing facoerisis, such as:

(a) Slipping of the erisofaco from the lens after the lens has been dislocated.

(b) Too great contraction of the pupils after the incision is made.

(c) Blood in the anterior chamber obscuring the pupil, or, if for other reasons the operator decides not to do facoerisis.

From recent literature a conjunctival suture seems desirable, but it must be emphasized that it is not a simple procedure. Some form of intra-capsular operation will produce better results in a competent surgeon's hands than the capsulotomy operation, and facoerisis, properly performed, is the ideal operation but not the simplest.

Immunity in Cataract Operation. R. Comenge[9] suggests immunization of cataract patients before operation after Besredka's method of local vaccination. An autovaccine is prepared from the bacteria found in the tears of patients with infection of the conjunctival sac, and this is injected beneath the integument. The antivirus might be instilled into the conjunctival sac one day before a cataract operation. The vaccine itself is

(9) Siglo méd., Jan. 15, 1927.

entirely nonirritating and can be obtained as a specific against any kind of pathogenic micro-organism. If more than one such is found in the conjunctiva a mixed vaccine should be employed. The chief danger in cataract operation is a panophthalmitis, and the author urges local immunization to prevent this catastrophe.

Blocking of the Main Trunk of the Facial Nerve in Cataract Operations. R. E. Wright[1] suggests a method of blocking the facial nerve in cataract operations in the cases of unruly patients. It has been tried in 150 cases with good results. The side of the face becomes mask-like and the pressure on the globe is limited to that caused by the levator muscles of the globe or a bulging eye. The only disadvantage arises from the lagophthalmus. In four cases, this persisted so long that a tarsorrhaphy was necessary. The lids must be carefully approximated while the dressings are applied.

The lobe of the ear is pulled forward and upward and the needle introduced at about the level of the mastoid process. Paralysis results after from five to fifteen minutes.

The Retina

The Interpretation of Retinal Folds. The observation and interpretation of folds in the retina present an interesting phase of the ophthalmoscopic study of the fundus. The introduction of improved means of observation has greatly stimulated the study of these important retinal changes. An increase in the illuminative power such as we have in the large electric, the Gullstrand binocular ophthalmoscope and in the use of red free light, discloses an abundance of reflections which are due to changes in the contour of the retinal surface.

The introduction of red free light by filtration for ophthalmoscopic illumination by Vogt has opened a

(1) Arch. Opth., 1926, lv. 555.

new era to fundus observation. His observations were made with a perfect red free filter and a microarc lamp. They can not be made with the semired free lenses that are found in many of the present day hand ophthalmoscopes. A true red free light filter will show the normal living macula canary yellow in color.

After extensive observations in this field, von der Heydt[2] finds that among the many advantages derived by using red free light, is the one that with it we are able to see a greatly increased number of reflections from the anterior retinal surface. This is possible because of two factors: a predominance of short wave rays and an obscuration of the usual reflection from the choroid. Red free light allows of a greater differentiation within the retina because it produces an increased opacification of the latter. The reflections from the choroid are in variations of red and therefore are rendered less visible by red free light, hence choroidal changes are correspondingly obscured.

Retinal folds in older persons and such as are less pronounced are visible only by means of red free light.

Folds in which the whole of the retina is involved are especially seen in cases of retinal separation, tumors, the scar contraction following exudative retinitis (retinitis proliferans) and at times if large foreign bodies have been imbedded in the retina.

These folds usually extend from the lesion to the nervehead, hence are radial to the latter. More interesting and more frequently seen are folds of the anterior retinal surface, that is the limitans interna. This limiting membrane of the retina is frequently separated from the nerve fibre layers by fluid in cases of retinal edema. As the edema subsides folds of the anterior retinal layer are seen.

Just as the slitlamp has exposed so-called folds in the cornea as being strictly confined to Descemet's membrane, so experience with red free light has proven the

(2) Amer. J. Ophth., January, 1927.

limitation of a preponderance of retinal folds to the internal retinal limiting membrane.

Retinal folds in which the limitans interna forms the anterior folded surface may be dull or reflecting. In the latter case they will show double contoured preretinal reflex lines.

These folds of the inner retinal surface may be dull with ordinary light while with an increased source of illumination or in red free light they may show reflex lines. The difference in behavior in this instance is due to the illuminant alone. Dull folds do not reflect because the limitans interna and usually transparent retina behind it are in a state of edema and cloudy swelling.

Recovery manifests itself by a return to transparency and a change from a dull to a reflecting surface. This metamorphosis may at times be observed in adjacent retinal areas, dull folds may even merge into such as will show reflections. Beyond middle life the anterior retina is more opaque hence preretinal reflex lines will not be found with ordinary illumination. In order to see retinal folds in age, red free light must be the illuminant of choice.

The vitreous surface adjacent to the retina may also be folded and give origin to reflecting folds. This must be accepted in view of the occasional finding of linear reflexes which extend onto and cover the disc.

Regarding the direction of folds:

Irregular folds of the retina are seen in connection with scar contraction, tumors, detachment, and following edema of the papilla. These extend in the direction of traction, or they may be due to a lateral displacement of tissue (corrugation folds).

The direction of folds is influenced by the position of the lesion in its relation to the other points of retinal fixation: the disc and ora serrata. They are, therefore, often radial to the disc.

Folds that are radial to the macula are seen after contusion, in iridocyclitis, optic neuritis, after exudative

retinitis, thrombosis, embolism, retinitis pigmentosa, hole in the macula, and in acute retrobulbar neuritis.

The radial direction of the folds is due to the fact that the limitans interna is more intimately connected at the macula with the underlying retinal structures. That this is the case has been proven anatomically by Dogiel.

A case quoted by Vogt of hemorrhage into the anterior retina (so called preretinal, but in reality back of the limitans interna) gives added proof of this more intimate attachment. The blood in this case had spread over a large intraretinal area but it almost completely spared the macular region because of the more intimate cohesion of the layers in this modified retinal area. Therefore the macula presents a point of fixation for the various retinal layers, hence the radial direction of superficial folds.

A case of folds radial to the macula is shown in the illustration. It is a photograph of a fundus taken one week after trauma. The patient was injured by a wrench. There was a very large cut in the bulbar conjunctiva and one thru the upper canaliculus. Apparently there was no injury to the eyeball (slitlamp examination) with the exception of the radial folds seen passing over the foveal rim. These folds were visible only with intense illumination.

The immobility of the retinal layers at the macula and the retina at the disc creates two fixed points and thereby also allows of the development of vertical folds in the area between these two points.

Very delicate vertical folds in this area between the macula and disc in youth may be considered as normal. The author has seen a case of dull vertical folds in this area with ordinary illumination as well as with red free light in the case of a boy after orbital cellulitis.

Either the long continued pressure against the eyeball or more likely a local toxic absorption may have caused a retinal edema in this case. This edema was later fol-

lowed by the development of these interesting vertical folds between the macula and disc.

Summary:

1. Retinal folds may involve the retina as a whole, the limitans interna, or they may be simulated by a folding of the vitreous surface adjacent to the retina.

2. The direction of folds is determined by the points of retinal fixation—lesions, the ora serrata and disc, as well as the cohesion of the retinal layers at the macula.

3. Folds that radiate from the macula likely involve the limitans interna only, because of the intimate attachment of the retinal layers to one another at this point.

4. Dull folds may have the same substratum as reflecting folds. The latter are evidences of the retinal transparency of youth or a recovery from the opacity of edema or cloudy swelling.

5. Red free light enhances our ability to interpret correctly these interesting phenomena.

Looking at the Sun. In clear weather it is only at sunrise and at sunset that we can with comfort look directly at the sun with the unprotected eye. At these times the great distance of atmosphere through which the sun's rays have to travel before reaching our eyes serves to diminish their intensity to a point within the limit of safety. When the sun is high the eyes are protected from glare by the lid and brow, and if we attempt to look up at the sun's disc we are dazzled and instantly turn our eyes away. If in spite of being dazzled we persist in looking, we run a great risk.

This risk,[3] as Sir Arnold Lawson and Mr. A. L. Whitehead pointed out, is especially great when looking at an eclipse of the sun. Even after any ordinary partial obscuration of the sun a few cases of "eclipse blind-

(3) Lancet, May 7, 1927.

ness'' come under the observation of ophthalmic surgeons. The visible and infra-red rays from the sun passing for the most part unchanged through the cornea and lens are focused approximately on some part of the retina whenever the eye is at rest and the sun within the field of vision. Reaching the retina, these rays pass through its superficial layers without doing any harm until they reach the pigmented epithelial cells at the back, where they are degenerated into heat, which gives rise to a thermal lesion (an ordinary burn) spreading inwards to the retinal tissues and outwards to the choroidal vessels. Fixation of the sun's image on any peripheral part of the retina must, however, be a very rare occurrence, and a point lesion, if it should occur, would probably give rise to no inconvenience. But at the macula or central spot of distinct vision the case is quite otherwise. Here in the normal eye the rays are accurately focused and at a moment of keen interest discretion may be thrown away and fixation of the sun's image occur. The macula is the most vulnerable part of the retina, for at this spot the retina is thinnest, all the layers having nearly disappeared except the cones and the pigmented epithelium, while there are no blood-vessels which supply the central spot direct and might help to distribute the heat. Hence, if the warning sensation of dazzle is disregarded, a thermic lesion may result, leading to permanent damage at the macula, with pigmentary changes which can be seen with the ophthalmoscope; and at the macula even a point lesion will lead to a visible blank in the field of vision. It is thus the red and yellow rays from which the retina runs the chief risk. The ultra-violet rays, it is true, cause conjunctival trouble and pain, but they are, it seems, largely absorbed by the cornea and the crystalline lens and therefore do not reach the retina in any dangerous quantity except in young children in whom the lens is very transmissible, or in those whose lens has been extracted by operation.

We dwell upon this danger to the unprotected eye to remind would-be astronomers, and especially all who have the care of children, that the danger is as real as the safeguard is simple. All that is necessary for a brief survey of an eclipse is to interpose a piece of smoked glass or of fogged photographic film of such a density that the sun when seen through it is no brighter than the setting orb. The photographic film is the safer, as the smoked surface rubs easily off the glass when in use. Untreated film does not afford sufficient safeguard for prolonged sun-gazing. It may remove the glare, but it does not prevent the ultra-violet burn of the anterior structures of the eye, and they have collaborated in the production of photographic film so treated that all the short waves are cut out completely, made up in a mask at a price designed to bring it within reach of nearly everyone.

Retinitis Pigmentosa. Cyril Dixon and L. J. C. Mitchell[4] contributed jointly a report of a series of cases of retinitis pigmentosa occurring in one family. The father, aged 54, and the mother, 56, had six sons and four daughters. Of the sons, one, aged 30, was normal; another, 28 years of age, presented gross deafness, the vision in both eyes being 6/18 with typical retinitis pigmentosa. A third son had died at the age of 21, being blind and deaf; another son, aged 19, was normal, and the sixth son, aged 16½, had right vision 6/9, left vision 6/12. His field was contracted and he suffered from typical end-organ deafness. Of the daughters, three were normal and one, aged 15, had 6/9 vision in both eyes, and definite retinitis pigmentosa with typical gross end-organ lesion. The father had been deaf since the age of 29, but had no eye defects. The mother was normal. The father had had two deaf and dumb cousins, both of whom were dead. The Wassermann test was negative in all cases.

(4) Brit. M. J., Apr. 23, 1927.

The Optic Nerve

Optic Nerve Disturbances from Focal Infection. Needless or too radical intranasal surgery in cases of optic nerve involvement from focal infection; in other words, the routine opening of uninfected sinuses, has been found unnecessary by Leon E. White[5] and is to be condemned. The large amount that has been written on the anatomical relationships of the optic nerve to the posterior sinuses, has thrown these latter structures too much into the limelight, while the more remote sources of infection have been left decidedly in the background.

Looking in retrospect over more than one hundred cases, this author believes that it is usually possible to find the focus of infection and by eliminating it, before the nerve is damaged, to obtain prompt recovery. Nasal obstruction when well marked should be removed. As the posterior sinuses are rarely infected it is unnecessary to open them except in a few desperate cases. The advocacy of exenteration of the ethmoids and sphenoids, even when they show no definite infection, is to be condemned. The benefit following the opening of the sinuses would naturally occur about that time, although some of it might be due to the depletion of the structures adjacent to the nerve. As sufficient pathology was not found in the sinuses to account for these optic nerve disturbances more distant foci were sought. The removal of infected teeth and tonsils soon proved to be the most effective method of treatment. Infection is now believed to come from either some systemic condition as influenza or intestinal toxemia or from some definite focus in teeth, tonsils or sinuses. This infection travels by way of the blood stream and produces a neuritis of the optic nerve. Eliminate it from the blood stream and the neuritis subsides.

The prognosis is dependent upon the duration and

(5) Boston M. and S. J., Apr. 21, 1927.

extent of the loss of vision, the condition of the fundus, the virulence of the infection and the size of the optic canals.

About 85% of the cases would recover under conservative treatment such as local medication and the removal of some definite focus. These cases are usually taken too seriously. Extreme measures are instituted where little or no treatment would suffice, and while recovery may take place in spite of, rather than because of, radical operative procedures, the patient is submitted to a needless risk.

In the remaining 15% where we are contending with a severe neuritis with marked or complete loss of vision, it is usually advisable, in addition to the removal of the focus, to also remove the middle turbinate and open the posterior sinuses.

Teeth should be studied by an expert odontologist, devitalized ones especially.

Negative pressure in the sphenoid would favor the migration of bacteria and toxins from the blood stream to the optic nerve, a condition similar to that which takes place in the tympanum in Bell's palsy.

A definite focus was found in fifty-three of the sixty unreported cases. The tonsils appeared to be the only focus in seventeen, the teeth in fourteen and the antrum in two. Teeth and tonsils either alone or combined was considered to be the focus in 70%. In but six cases were the ethmoids involved and even in these there was also infected teeth, tonsils or antrum. The frontal and sphenoid were each involved but twice. The removal of the focus was followed by normal vision in 50% and marked improvement in 25%. Much better results would have been obtained had the focus been removed earlier.

With regard to the influence of negative pressure in the sphenoid on the optic nerve, this same author in an earlier paper[6] says that the theory of negative pressure

(6) Boston M. and S. J., Dec. 23, 1926.

in the posterior sinuses would explain the beneficial results which follow the opening of normal sinuses.

Negative pressure is considered under two aspects:—

1. Is it possible for it to take place in the posterior sinuses?

2. If it does exist, would this negative pressure favor the passage of the bacteria in the blood stream to the nerve?

Negative pressure is a well recognized condition in the frontal sinus, antrum, anterior ethmoids and middle ear, and is brought about by a closure of their ostia or ducts, so that reasoning by analogy a similar condition should be brought about by closure of the sphenoidal ostium.

In Bell's palsy negative pressure within the tympanum seems to favor the migration of bacteria from some distant focus to the facial nerve, so that it seems logical to conclude that a similar condition of negative pressure within the sphenoid would favor migration of bacteria to the optic nerve. If it is conceded that a closed sphenoid may favor the invasion of the optic nerve by bacteria from the blood stream, the logical thing is to eliminate the focus that feeds the bacteria to the blood.

Treatment is considered under three heads:—

1st. About 50% of the cases will recover spontaneously. Remove any definite focus. If none is found, surgical intervention is contraindicated.

2nd. In 30% of the cases the relief of nasal blocking is indicated in addition to the removal of the focus.

3rd. In somewhat less than 20% of the cases it will be found necessary to open the posterior sinuses to prevent optic atrophy.

Thirty-three optic nerve cases are analyzed. In but 15% were the sphenoids and posterior ethmoids opened and even in some of these it was unnecessary. Postoperative cicatricial obliteration of the sphenoidal ostium with resulting negative pressure was found in one case.

Retrobulbar Neuritis Associated with Sphenoidal and Ethmoidal Sinusitis. J. Flynn[7] describes the following interesting case which throws light upon one of the causes of retrobulbar optic neuritis. The patient, a man of thirty-seven years, had complained of headache over and behind the right eye for about two years. He was wearing glasses. Visual acuity with the right eye was 6/12 and with his glasses 6/6 minus. Left eye, 2/60, unimproved with his glasses.

The left eye was amblyopic, having a very high degree of myopic astigmatism. The left cornea was nebulous. He stated he had never seen with the left eye. Slight alteration of the axis of cylinder of the right glass gave him 6/6. There was no fundal change. As he also complained of catarrh at the back of the nose and throat, he was advised that he should see a rhinologist in regard to any possible cause of headaches in that field, but this he postponed.

Sight had become blurred during the night and the neuralgic pain about the right eye was worse. The vision of the right eye was 6/36 and with glasses 6/18. Fundal examination revealed nothing abnormal. The eye was tender on pressure and painful with movement. There was a very definite central scotoma for red and green. Pupil reaction was normal, the so-called "courtesy" reaction was not present.

A diagnosis of retrobulbar neuritis was made. The probable cause in light of his history was sphenoidal or posterior ethmoidal trouble. There was no story of injury, no other evidence of enlargement of the pituitary or of insular sclerosis or of acute myelitis, nor was there any history, suggesting toxic amblyopia (alcohol, tobacco, diabetes, *et cetera*). He had taken a little "Aspirin" for his headache.

In an examination of the nose no pus was seen. Vision was soon reduced to hand movements. A submucous resection of the septum was performed. Both middle

(7) M. J. Australia, Apr. 9, 1927.

turbinals were removed; the posterior ethmoidal cells on both sides were curetted; the right sphenoidal orifice was enlarged with forceps, no actual pus was detected, but the ethmoids were in a crumbly condition and very juicy.

Four days after the operation, the patient read the top print on the bed temperature charts. He was having nasal douches of warm saline solution.

Ten days later he was discharged from hospital with vision 6/6.

Three months later, the patient complained again of headache and pain behind the right eye of one week's duration. The eyesight was not affected. The nose appeared clean. Trichloracetic acid, one part in three, was applied to the right sphenoid.

In November, 1926, two years after retrobulbar neuritis, the patient reported, "just for an overhaul of the right eye." The sight of the right eye had kept quite well and no headaches had occurred since the last treatment. Vision of the right eye was 6/12, with glasses 6/6. He recognized the smallest red and green on Cruise's scotometer in a normal manner.

Of course it is impossible to state whether the complete recovery from the retrobulbar neuritis after the sinus operation was *post hoc* or *propter hoc,* but the latter is more than probable, especially in view of subsequent similar headache, responding so readily to treatment of the sinus.

If *propter hoc,* it may be emphasized that the sinuses in question should be cleared out, even though no pus is seen in nasal cavities on ordinary examination.

In discussing the etiology and treatment of non-suppurative intra-ocular affections, including retrobulbar neuritis, H. F. Shorney[8] deals with the etiology under the headings of affections, of the teeth and gums, tonsils, and accessory sinus diseases, mentioning the frequency of infection of the optic nerve and nerve head in sinus af-

(8) Brit. M. J., Apr. 23, 1927.

fections. His experience pointed to the occurrence of a descending retrobulbar inflammation, accompanied as it not infrequently was by some inflammatory reaction of the nerve head, rendered visible by the ophthalmoscope. Other etiological points were: metabolic diseases, diseased organs producing altered chemical action from hypersecretion or hyposecretion, parasitic causes, infection from penetrating wounds, and endogenous infections. After describing the routine treatment of acute iritis, he gave details of the milk injection therapy. He reviewed the substances used in the treatment of intra-ocular infection, mentioning chemical agents, such as afenil, alvonal, urotropin, argoflavine, rivanol, atophan, atophanyl, bismogenol, spirovismol, sodium cacodylate, solarson, and astorin. The biological remedies he had tried were milk, aolan, and caseosan, vaccineurin, artheigon, insulin, and sanocrysin. He had also employed for light treatment the quartz lamp, Solex lamp, the Koppe blue light, and Roentgen rays.

The Orbit

Hemangioma of Orbit. In considering tumors within the orbit, it may be well to picture the orbit as a rigid cone-shaped cavity made up of seven different cranial bones having nine foramina or channels opening into it, and containing besides the eyeball, the lacrimal gland, orbital fat, cellular tissue, muscles, arteries, veins, lymphatics, nerves, both motor and sensory as well as of special sense. Any one of these structures may give origin to a tumor. In addition, neoplasms may develop in the orbit from metastases from growths originating elsewhere in the body, or from invasion from cavities adjacent to the orbit. The growth may involve but a single tissue, but as these different orbital structures rest so closely together, it is not difficult to understand that compound tumors involving more than a single tis-

sue may be met with and make differentiation between them a perplexing problem.

One general symptom of essentially all orbital tumors is exophthalmos. This may be slight in the early stages, but is progressive and naturally becomes more pronounced as the tumor grows. Palpation, transillumination, percussion, auscultation, focal lighting, skiagraphy, and fluoroscopy are all of much diagnostic value, and should be utilized whenever it is practical to do so. Before undertaking any serious operation for the removal of an orbital growth, Wassermann tests should be made, and the nose and accessory cavities should be carefully examined. Tuberculin tests are also advisable.

The appended case, reported by G. E. Curry,[9] is that of a forty-four-year-old male who gave a history of a gradually growing prominence of the right eye which began when he was twenty-four years old. Two years prior to this he received a blow on the side of his head from a thrown baseball. However, he is uncertain on which side of the head he was struck, so this accident may be of no significance. He gave a somewhat indefinite account of several attacks of hemoptysis about six months before the eye symptoms began, in one of which the bleeding was profuse. The loss of blood was estimated to have been at least three pints. There have been no hemorrhages since, and the patient is inclined to think this bleeding may have been from the nose. No other significant facts were elicited. Some six months following the first sign of the proptosis there was some puffiness of the eyelids and a slight blurring of the vision in the eye. For the next five or six years there was little or no noticeable change in the eye, but subsequently a steadily increasing bulging forward of the eye and more and more impairment of the vision took place. For the past two years the eye had been decidedly more proptosed, and much of the time the upper lid had to

(9) Atlantic M. J., February, 1927.

be seized with the fingers and drawn down over the eyeball in order to close the eye and protect the cornea. The patient has worn glasses for many years, and frequent changes have been made in the lens for the right eye. The present correction and vision is as follows:

O.D. S + 7.00 = C + 1.25 ax. 90° = 18/20.
O.S. S + 1.00 = 20/20.

There is a large relative scotoma in the right eye. Diplopia has not been present.

Fig. 11.—Hermangioma of orbit, showing displacement of eyeball.

The accompanying photograph shows the exophthalmos and displacement of the eyeball better than it can be described. A distinct mass could be felt in the upper and outer part of the orbit. It was firm and immovable. There was no pulsation. No bruit could be de-

tected. A lipoma or one of the slow-growing sarcomatous growths were considered as possibilities as to the nature of the growth. Luetic infection was denied, and Wassermann examination was negative. (Fig. 11.)

The radiographs, while showing a darkened, diffused area limited to the orbit, did not aid in determining the nature of the growth.

The ophthalmoscopic picture showed some pallor of the optic disc and a very slight venous congestion, but much less than might be expected from the pressure required to cause so much displacement of the eyeball. The increasing exophthalmos is shown by the following exophthalmometer readings:

	Right Eye	*Left Eye*
June 5, 1924	33	24
August 4, 1924	37	28
April 9, 1925	40	29

On the latter date, the vertical width of the palpebral slits was 24 mm. in the right eye and 11 mm. in the left eye.

Before operation the red blood cells amounted to 3,452,000, hemoglobin 90 per cent. On April 17, 1925, the patient being etherized, an elliptical incision was made, beginning on a line with the upper external angle of the orbit, curving slightly forward, and about 1¼ inches in length, exposing the external wall of the orbit. Then, by blunt dissection, a dark-colored mass was exposed to the outer side and above and behind the eyeball. This mass was freed by finger dissection. It was found to be encapsulated, most firmly attached far back to the orbital wall. There was no pedicle. The mass was ovoid in shape, and measured 3¼ cm. by 4 cm. The tumor was freed and removed without great difficulty. It was not necessary to resort to the Krönlein operation, or even to remove a part of the bony rim of the orbit.

In July, 1926, or fifteen months after the operation, the opthalmoscope reveals no discernible change in the fundus. The scotoma remains. The vision equals 20/120

in the right eye. There is ocular comfort and no indication of any recurrence of the growth.

The second photograph (Fig. 12), made fifteen months (July, 1926) after the operation, shows the contrast in the appearance of the man prior to the operation and at the present time.

Fig. 12.—Patient fifteen months after operation.

The Uveal Tract

The Prostate as a Remote Focus of Infection in Ocular Inflammation. A causal relation of a focus of infection to a metastatic inflammation is not often susceptible of scientific proof, but Zentmayer[1] reports in

(1) J. A. M. A., Oct. 9, 1927.

detail a number of cases of ocular inflammation, due undoubtedly to a focus of infection in the prostate. From an exhaustive study of these observations he comes to the following conclusions:

1. The prostate may be the source of infection in certain ocular inflammations.

2. The prostatic infection is probably more often nongonococcal than gonococcal.

3. The metastasis, as in other focal infections, may occur in any of the ocular tissues susceptible of inflammatory reaction, but the uvea and cornea are probably most often involved, the latter, and also the iris alone, especially when the gonoccus is present.

4. The fact that an inflammation persists after the removal of a suspected focus of infection does not prove that this was not the primary source of infection, as the resistance of the tissues may have been so reduced by this inflammation as not to be able to withstand the action of organisms or toxins of much less virulence from some other part of the body.

5. Only when a metastatic inflammation subsides after the removal of one possible source of infection does it prove this to have been the exciter.

The Ocular Fundus in the Acute Toxemias. The type of ocular lesions found in the patients in a medical service differ markedly from those found in an *eye* clinic. Those found in medical patients are apt to be less widespread, and of a more transient character with less destruction to tissue and vision. The conditions encountered in an eye clinic cause ocular symptoms chiefly, such as disturbance of vision or pain, and are usually more widespread, destructive and permanent.

Findings in the fundus examinations of eight hundred and fifty cases are analyzed by Albert I. Brown,[2] and show that in the toxemias there are certain conditions in the fundi which are not characteristic of any one disease but are common to all.

(2) J. A. M. A., July 16, 1927.

Only 3 per cent of the patients examined had any ocular complaint other than the simple statement that they wore glasses.

Fifty-two per cent (440) of the patients presented abnormal fundus conditions which were considered to be dependent on some constitutional condition. Eighty-five per cent (374), or 44 per cent of the 850, were considered to be dependent on the acute toxic processes for which the patients were then being treated. The lesions reported exclude all thought to be due to retinal arteriosclerosis, or renal or diabetic diseases.

After the first seventy-five cases were observed, it was evident that there were certain deviations from the normal occurring with some regularity. They appeared to be dependent on the type and especially the severity of the infection. They changed with the course of the disease, became less marked when the temperature fell and the infection seemed to be subsiding, and advanced when the disease seemed to be progressing. These manifestations could be grouped into three classes:

1. Toxemias of mild intensity and short course (18 per cent, 153): (*a*) disks normal or slightly hyperemic, with vessels (especially the veins) slightly dilated. Associated chiefly with influenza, acute rhinitis and acute sinusitis of moderate intensity. (*b*) Average temperature 100 F. (*c*) Average duration from four to five days.

2. Toxemias of moderate severity and longer course (5 per cent, 476): (*a*) Disks rather hyperemic, margins occasionally blurred; vessels definitely dilated, and often slightly tortuous. Associated with pneumonia, severe sinusitis, severe acute polyarthritis, typhoid, pyemia, septicemia, encephalitis and meningitis (especially cerebrospinal). (*b*) Average temperature from 102 to 103 F. (*c*) Average duration from one to eight weeks and occasionally death.

3. Toxemias of great severity (26 per cent, 221): (*a*) Disks with margins blurred by edema and vessels quite

dilated. Surface of disks often fades insensibly into surrounding retina. While streaks show line of nerve fiber bundles. Occasionally retinal edema; punctate hemorrhages from the finer vessels into the retina. Twice small whitish, retinal areas around or near the disks were seen (retinitis septica of Roth?). Occasionally edema of the disks was seen as a forerunner of a frank optic neuritis (1.5 per cent).

In this class are grouped the cases of severe pneumonia, meningitis, severe typhoid, septicemia and sinus diseases. Eighty-five per cent (190) in this group presented changes. One hundred and seventy-eight had various degrees of disk changes, ranging from increased capillarity to optic neuritis. Eighty-six presented a moderate edema of the disks, with slightly blurred margins and dilated vessels. Fourteen of these eighty-six had marked papilledema, which advanced with the progress of the disease and receded as the condition subsided. After recovery, the eyegrounds were entirely normal without sequelae. Thirty-two patients developed retinal hemorrhages. Twenty-six of these were of the finer punctate character, which were apparently from ruptured fine vessels. Twenty-two patients in this group presented severe changes of one sort or another. Six developed optic neuritis, which appeared after the inception of the toxemia in each case. All developed the usual picture of visual disturbance and sequelae. Two developed embolism of the central artery; one, thrombosis of a branch of the central vein; one, a metastatic choroidal exudate; two metastatic choroiditis, and two, white retinal areas around the disks (septic retinitis?).

From the foregoing analysis it is evident that the severer types of infection produced the greatest percentage of lesions, both mild and severe. The cases that presented the simplest conditions, such as increased capillarity, slight edema of the disks, and retinal edema, associated with dilation of the larger vessels (especially the veins), were of greater interest and of more

importance than those which presented the severer lesions, such as hemorrhages, areas of degeneration, and neuritis. The former, if present, seemed to present a sort of bird's-eye view of the course of the disease, from which, quite often, could be told the stage and probable severity of the infection. All these signs seemed to be stages of varying degrees of the same process. The degree was usually found associated with the height of the temperature; i. e., the higher the temperature, the more pronounced the manifestations. In cases in which there was very mild involvement, such as uncomplicated influenza or not too severe pneumonia, nothing more than a mild hyperemia or dilation of the larger vessels occurred.

The reactions described under 3 were considered to have occurred with sufficient regularity to entitle them to consideration as definite entities in these diseases, and consequently as of practical importance in diagnosis and prognosis.

Ocular Disease Occurring in the Course of Nondysenteric Amebiasis. Ophthalmology has a great pathologic opportunity, and perhaps a great humanitarian one, in establishing or disproving the thesis which relates protozoa, in particular, to general or local disease either by direct or mediate invasion through the intestinal wall. Many eyes are enucleated each year for the intolerable distress of intractable secondary glaucoma in patients who show the typical oculo-articulo-intestinal syndrome. Such eyes, in patients untreated with ipecac derivatives, should provide the needed pathologic material. The difficulty of identifying amebas in tissues after tissue death is great, because of the rapidity with which these protozoa disintegrate. Their resistance is extremely low even in untreated living tissue, and treatment with ipecac appears to produce degenerative changes in vivo, which increase the difficulty of recognition of protozoa in cases in which such treatment has been received. This has accounted, in part, for our

inability up to the present to demonstrate amebas in ocular tissues. The search is being continued. Loss of these eyes comes about by means of the progressive deposit of plastic exudate between the iris and the lens, lending to secondary glaucoma. Whenever the syndrome has been recognized in time, active antiamebic treatment has arrested progress so effectively as to reduce the amount of material which finally comes to sectioning almost to nothing. Sections of iris from treated cases thus far have failed to show amebas or flagellates in the iris stroma.

An investigation of eighty-eight cases of chronic ocular inflammation or disease, by Lloyd Mills,[3] confirms his opinion, that protozoa, notably *Endameba dysenteriae* (histolytica-cell solvent), and possibly the flagellates *Chilomastix, Craigia* and *Giardia,* were fundamentally the cause of a certain proportion of cases of chronic, recurring and intractable inflammation of the eyes. Whether the ocular lesions result from direct protozoan invasion, from secondary bacterial invasion by way of the damaged intestinal wall, from other foci or infection, or from the toxic changes so often noted, is not yet proved. It is certain, however, that the arrest or cure of chronic iridocyclitis, choroiditis, retinitis, episcleritis, keratitis and conjunctivitis has followed the faithful use of ipecac and its derivatives when the recognition of a protozoan or flagellate background has ended repeated vain searches for a bacterial etiology. Not seldom a remarkable improvement in the chronic conjunctivitis which is often present results from the first injection of emetin. In fact, the symptomatic relief which follows the use of emetin in some cases of amebic iritis is enough to raise the question as to its possible value in iritis and scleritis of other origins. Reversely, the exacerbation of colonic and hepatic discomfort and tenderness, which is now believed to represent excystment of the amebas and renewed activity of the basic

(3) J. A. M. A., Oct. 9, 1927.

infection, often is heralded by functional discomfort of the eyes, mild photophobia, tearing, conjunctival inflammation and a flare of iritis in that sequence. The relation between the periodicity of the abdominal discomfort and the periodic attacks of iritis and other ocular inflammation has been noted many times.

Relief, arrest or cure has resulted in nearly every patient who was able and willing to undergo the requisite medical and surgical treatment. A single course of treatment sufficed in a few cases, but the majority required two or more courses before the ocular condition could be considered as arrested. The ocular lesions often clear before the intestinal condition is wholly mastered; but this local improvement should induce no let up in the fight for the complete elimination of the parasites, if possible.

The appearance of patients suffering from ocular disease occurring in the course of nondysenteric amebiasis and some flagellate infections often is so characteristic that the correct impression as to the origin of the local disturbance may be given at the first visit. Such patients, if the disease is at all advanced, have the typical mild pallor and lassitude of a secondary anemia. They complain of vague abdominal discomfort and nearly always have constipation; they have low muscular and mental tone, and the general appearance is one of a mild chronic intoxication, with especial reference of symptoms to the abdomen. "Patients suffering with this varied symptomatology have usually seen several physicians. Their tonsils, teeth and appendixes are usually or are very often out. Their funds often have become as low as their vitality. They are discouraged and long have been diagnosed as neurasthenics."

The fact that enucleation of one eye had been performed in sixteen out of eight-eight patients (18 per cent) attests the chronicity and severity of these cases. This enucleation was done in all cases for terminal secondary glaucoma, which followed uncontrollable plastic

iritis in thirteen cases, so-called idiopathic retinal detachment in two, and retinal detachment, following hemorrhage into the vitreous and retinitis proliferans, from an unknown source, in one case.

In nearly half of the patients, operative work, including fourteen appendectomies, six cholecystectomies, ten tonsillectomies, some pelvic surgery, nasal septal work, sinus drainage and the extraction of numerous teeth had given temporary benefit, but had cured none.

Blood counts, blood Wassermann tests, urinalysis, and examination of teeth, tonsils, nasal sinuses and stools were done almost uniformly. Whenever possible, the sputum was examined, the Detre test for tuberculosis was performed, the phenolsulphonephthalein test for renal function was recorded, the icterus index was determined, smears were taken from the genito-urinary tract, abdominal roentgenographic studies were made, and in a few cases, protein sensitization tests were carried out exhaustively.

A summary of the results of these tests shows negative blood Wassermann reactions in the eighty-one cases tested. The Detre test for tuberculosis was negative in all the fifty-two cases tested and was confirmed further in cases of possible doubt by twenty-three negative sputums. The urine showed the presence of sugar in one case, of albumin and granular casts in six, and the presence of indican in twenty.

The renal function tests averaged 60 per cent and added no light to the subject. The icterus index, a test for free bilirubin in the blood stream, averaged the high figure of 11, the normal range being between 4 and 6 and that of "latent jaundice" lying between 6 and 15, beyond which clinical jaundice usually appears. This figure might have been expected from the frequency with which frank hepatitis and minor grades of liver involvement occur in protozoan infestations of the intestines. Such an excess of pigment undoubtedly was

a decided factor in increasing the appearance of anemia in so many of these cases beyond the degree of secondary anemia actually shown by blood tests. The average hemoglobin was 83 per cent; erythrocytes, 4,300,000; leukocytes, 8,000; polymorphonuclears, 65 per cent, and mononuclears, 35 per cent. This depression of polymorphonuclear leukocytes is characteristic of protozoan infections and is seen even in solitary abscesses of the liver.

Smears from the penis, vagina and cervix were negative in fifty-six cases and were not taken in the remainder. Diseased teeth had been extracted or roentgenograms showed no involvement save in five cases in which root abscesses were cured by extraction. The tonsils were slightly diseased in seven cases, badly diseased in two, and had been removed or were normal in the remainder. Two patients had ethmoiditis as a possible contributory factor.

Spinal roentgenograms were taken in several cases in which arthritis of the spine was in question, and roentgenographic studies of the abdomen were made in twenty-one cases showing a severer form of the disease, in which they confirmed the medical diagnoses of appendical and cecal adhesions, colon stasis and gallbladder involvement. The recognition of these severer abdominal lesions is of the greatest importance to a final cure, as the presence of a diseased gallbladder or appendix, or cecal or appendical adhesions may serve as foci of further infection or may produce intestinal pocketing and stasis, without the correction of which no medical treatment can be of more than temporary benefit.

The general treatment of these cases has to deal with the elimination of decided intestinal faults, such as adhesions, bands, diverticula and tumors, which require surgical correction, if their interference with normal intestinal function is great. If such defects do not exist or have been remedied, the main remedial weapons are ipecac and its alkaloid emetin. Chaparro amargoso and

certain of the arsenical preparations, notably stovarsol and neo-arsphenamine, are used as alternative remedies, but their place is not yet certain. An organic iodin preparation (iodo-oxybenzenepyridin sulphonate) has some adherents. Ipecac is usually given nightly for from six to ten nights in the massive dose of 60 grains (3.9 gm.) in keratin coated pills. This is given about five hours after food is taken, and in the effort to retain the medication the patient is kept quiet and ice bags are used on the throat and epigastrium. Emetin bismuth iodide pills are given similarly. The duodenal tube occasionally may be substituted for medication by mouth, from 0.5 to 1.5 drachms (2 to 5.5 gm.) of the fluid extract of ipecac in 4 ounces (118 cc.) of water being introduced directly into the duodenum. Emetin is given hypodermically in daily dosage of $\frac{1}{3}$ grain (0.02 gm.). It is somewhat toxic at times, and this effect must be watched with care. Enemas given daily or on alternate days often give much benefit. The usual high soap enema is probably most valuable for any extended period of time, but directly curative results are reported from time to time following enemas of emetin and of neoarsphenamine. All experienced investigators of this subject state that freedom from symptoms after treatment and one or two negative stools do not constitute cure of a case of amebiasis which, instead, may have gone into the stage of encystment to become a chronic cyst excreter or carrier with future exacerbations. Motile forms are found by giving salts and examining the stools while still warm. Cure of the infection may be announced with confidence only when negative examinations are found over a period of three or four months or longer.

A possible dietary angle should be mentioned in connection with the subject of chronic colitis and its ocular relations. The extreme restriction of food to which some of these patients are subjected produces at times deficiency disorders in the form of conjunctival and

corneal inflammations, such as have been noted in xerophthalmia, as due to a lack of vitamin A. Antiamebic and antibacterial treatment fail fully to relieve the ocular condition, which usually responds to a change in diet.

The statement that protozoa and flagellates are the direct cause of any or all of the ocular conditions studied in this connection is purposely avoided as unproved up to the present. The overwhelming clinical evidence, however, the exclusion of all possible bacterial causation, the almost constant presence of parasites of known tissue-invading capacity in the intestines of persons suffering from chronic, severe and unexplained ocular conditions and, finally, the arrest of ocular symptoms which follows the elimination of these parasites, would appear to justify the belief that protozoa and flagellates play a fundamental part in the production of many chronic ocular inflammatory conditions such as iridocyclitis, choroiditis, primary and secondary glaucoma, episcleritis and conjunctivitis.

Glaucoma

Some Features of Glaucoma Important to the General Practitioner. The matter of differential diagnosis in ocular diseases is sometimes an imperative call upon the family physician. He is the only one, perhaps, in a position to warn the patient of the perils confronting him. He is the one who must initiate measures of relief or overcome the error of placid inaction. It is his knowledge of the prognosis in ocular affections that must give the patient a measure of his danger and a measure of the reasonable hope he may cherish.

One of the most important ocular diseases involving the responsibility of the general practitioner is that of chronic glaucoma. Its significance depends upon the fact that it is exceedingly easy to confuse this condition with other intra-ocular changes not associated with pain

or other distressing manifestations calling for immediate relief. Many times the patient depends upon his family physician to guide his conduct in the earlier stages of ocular affections, intending to submit his condition to an oculist at some later period. The great importance of chronic glaucoma, therefore, to the general practitioner hinges upon the fact that there may be some difficulty in the earlier stages in differentiating chronic simple glaucoma from some other conditions that do not demand such immediate attention. From a practical point of view, the mistake most frequently observed is in confusing a chronic glaucoma with incipient cataract or various changes in the fundus. J. O. McReynolds[4] calls attention to the importance of a correct diagnosis in these conditions.

With reference to the first two conditions—chronic glaucoma and senile cataract—you might say that there are many points in the subjective manifestations that are quite similar, but the prognosis and treatment are so entirely different that an accurate differentiation is extremely necessary. In the first place, whatever ground is gained by a chronic glaucoma, as a rule, is permanently held and, therefore, the important consideration is to prevent the advance of the glaucoma; whereas in the matter of incipient cataract, uncomplicated, there is no great loss in the final result, even if there is considerable delay and the patient may be able to secure perfectly useful vision whenever the lenticular opacities have advanced to a point that requires relief—in other words, glaucoma simplex requires early diagnosis and prompt attention to prevent irrevocable damage; whereas senile cataract can be attended to at any time that the patient requires additional vision. In considering these two conditions, we might divide the subject into two divisions: first, the subjective manifestations, and, second, the objective manifestations.

(4) Kentucky M. J., March, 1927.

Subjective Manifestations

Under this head, we might consider, first, the element of pain or physical discomfort. In both of these conditions there is practically no pain at any time unless there should supervene on the chronic glaucoma an acute or subacute process in which case pain would certainly be present. There is in each case a great deal of diminution in vision, but the character of this diminished vision will be likely to show certain characteristic features in each case. In chronic glaucoma, there may be, not only diminished vision for the point of fixation, but even in advance of this there may be a marked contraction of the visual fields, so that the patient may preserve central vision for an indefinite period, while his field of vision is steadily contracted down to the point of practical annihilation of the visual field without the patient being aware of such an impending calamity. Cases of this kind will frequently go for a change of glasses and they may find that it is still possible to secure for them fairly acute central vision, and on this account they may be led into the error of thinking that nothing of a serious nature is transpiring in the globe, whereas, the eye may be undergoing destructive changes that cannot be remedied. In senile cataract, however, there is more of a general dimness throughout the visual field, the central area not being more affected than the peripheral zones. It is true that the exact amount of visual disturbances in senile cataract will depend upon the special form of cataract which is present. In some forms the opacity is fairly evenly distributed throughout the substance of the lens, while in other cases it may be confined to certain areas of the lens and, consequently, the vision will be impaired, especially under those conditions in which the rays of light are forced to pass through the lenticular opacities. It is also to be observed that there are certain subjective visual sensations in both of these conditions that are worthy of regard. In the case of glaucoma, in the event there

should be subacute or acute exacerbation, there would result certain modifications in the dispersion of light, in consequence of which the rainbow rings, or halos, would form around a lighted candle held at a distance. These subjective sensations are produced by a certain cloudiness of the cornea leading to the breaking up of white light into its primary colors, or in producing elongations of the images formed by the entrance of light through the cloudy media. In the case of cataract, where the index of refraction is different in different sectors of the lens, it will be possible to have polyopia or multiple vision, due to the fact that this irregular refraction of the lens throws different images upon the retina. In neither of these conditions is there any notable inflammatory reaction or any discharge whatever. In each case, there is not much difference in the size, shape, or mobility of the pupil until visual acuity is reduced to a considerable degree.

Objective Manifestations

The objective manifestations are extremely important. In glaucoma simplex there would generally be a somewhat more shallow condition of the anterior chamber and the pupil would respond more sluggishly to the impression of light. The ophthalmoscopic and perimetric examinations would constitute the most important features in the differential diagnosis. The ophthalmoscope would show a distinct recession in the plane of the lamina cribrosa. There would be the characteristic break in the retinal vessels as they would pass over the scleral rim of the optic disc. There would also be, as shown by the perimeter, a marked retraction of the visual field, and the dioptric media would remain clear; whereas, in developing cataract the dioptric media would be less accurately outlined, but from the examination possible it would probably be easier to distinguish that there were no alterations in the nerve head itself or in the blood vessels, but the fundus and the field of

vision, as shown by the perimeter, would be unaltered. The intra-ocular tension, as determined by palpation, or a tonometer, would show no alteration whatever in the development of senile cataract; whereas, in glaucoma simplex, there would be a slight elevation in the tension, certainly at intervals, although there might be times when the intra-ocular tension would be normal. It is the slight increase in the intra-ocular pressure continuing for a protracted period that explains the absence of pain and the diminished vision in glaucoma simplex.

In all of these cases, where it is desirable to make an ophthalmoscopic examination and a dilated pupil is to be obtained, it is necessary to use some mydriatic whose action will rapidly disappear, such as euphthalmin cocain and homatropin, and, then, it is important to keep the patient under observation while the miotics are used to bring back the pupil to its normal size before allowing the patient to pass from observation, because whether the patient has already developed glaucoma or simply has a predisposition to it, the dilation of the pupil may help to determine the onset of the condition, and, under such circumstances, a patient with senile cataract could have added to this malady, also, an attack of glaucoma. In all these cases, it is desirable to keep the patient under observation, because of the fact that the picture may change from time to time, which would necessitate an alteration in the general management of the case.

In the case of glaucoma simplex, the treatment should be instituted at the very beginning and should consist either in the judicious employment of measures to reduce the tension by instillations of miotics, or recourse should be had to surgical measures intended to produce a freer filtration, these measures being especially the different forms of anterior sclerectomy.

With reference to senile cataract, the important consideration is that there is no necessity that the patient

should be allowed to become blind with senile cataract in order to secure a successful result from operative procedures. The lens can be removed just as successfully at one period as at another, and the patient is entitled to the increased vision whenever he reaches a point where he is unable to discharge his usual duties of life.

Acute Congestive Glaucoma

Acute glaucoma is a condition of extreme importance, not only to the patient and the oculist, but the general practitioner as well, because the responsibility of making a correct diagnosis and instituting appropriate treatment, many times will devolve primarily upon the family physician. It falls to his lot ordinarily to see the patient first, and it is in the early stage of acute glaucoma that the greatest good can be accomplished by an accurate diagnosis and by judicious management. There is no other condition that requires so imperatively correct treatment from the beginning, because, if incorrect management is employed, either in the way of active applications or a dilatory practice, disastrous results that cannot be overcome by any amount of subsequent diligence and care may speedily follow.

It is especially important that this condition should not be confounded with another condition with which, unforunately, it is most likely to be confounded, namely, acute plastic iritis. The importance of this differentation depends upon the fact that the treatment in these two conditions is diametrically opposed. In the case of acute congestive glaucoma, the great advantage to be sought is a speedy reduction in the tension, and this is accomplished most successfully by causing a marked contraction of the pupil, which results in pulling away the root of the iris from the filtration angle, thus opening, to some extent, the spaces of Fontana and the canal of Schlemm; while the object to be accomplished in acute plastic iritis is just the reverse—a speedy dilation of

the pupil to prevent permanent adhesions between the iris and the anterior capsule of the lens.

Let us now consider the important points of differentiation in diagnosis between acute congestive glaucoma and acute plastic iritis. The differential points may be considered under two general headings, the subjective manifestations and the objective manifestations.

Subjective Manifestations

1. Pain.—The pain in acute congestive glaucoma quite resembles that in acute plastic iritis inasmuch as the pain is distributed not only in the region of the eyeball and the orbit, but over the entire side of the head. However, the pain is much more acute in its character, much more rapid in its development, and much more extensive in its distribution in acute congestive glaucoma. It is frequently mistaken for a severe neuralgia, so the patient not infrequently comes to us with a history of having gone blind with neuralgia, when in reality he has gone blind with acute congestive glaucoma characterized by intense pain resembling neuralgia.

The constitutional manifestations are likewise more pronounced in acute glaucoma. There may be a distinct depression, with nausea and vomiting, which seldom occur at the onset in acute iritis. In both of these conditions, the pain is deep-seated in character, because of the fact that it is produced by pressure upon the deep-seated sensory nerves of the globe, and is in marked contrast with the superficial, scratching pains that are present in conjunctival inflammation. While the pain is excruciating, the sensitiveness of the cornea to the touch of the finger is rapidly reduced in acute glaucoma, because of the paralyzing pressure upon the sensory nerves, but the sensitiveness of the cornea to the touch is preserved throughout the course of acute plastic iritis.

2. Vision.—The vision is speedily reduced, or actually annihilated, many times within a few hours, in cases of the rapid development of increased intra-ocular

pressure, interrupting the circulation within the globe, exerting marked pressure upon the optic nerve fibres as they come through the lamina cribrosa, and also by producing an edema of the cornea and a cloudiness of the other dioptric media. The vision in acute iritis is slightly diminished by the accumulation of plastic exudates in the line of vision, but this result does not rapidly supervene. In addition to the loss of central vision, there is frequently a reduction in the field of vision in acute glaucoma, which may be made out in the earliest stages of the trouble, particularly if there have ever been preceding acute attacks, or a preceding chronic glaucoma. This reduction in the field of vision may consist in a concentric limitation of the field with a special reduction on the nasal side, or with various forms of irregular scotomata. It may also be observed that in looking at a lighted lamp in a room, for instance, the patient may distinguish a kind of halo around the light somewhat resembling the appearance of a street light as looked at through a frosted window pane on a winter night. This halo is due to the cloudiness of the cornea produced by the edema consequent upon the intra-ocular pressure, and it may assume the appearance of rainbow rings around the light.

3. Discharge.—There is no purulent, or muco-purulent discharge, as an essential feature of either acute glaucoma or acute iritis, because the pathological process is intra-ocular rather than extra-ocular. However, there is in both instances a profuse flow of tears.

Objective Manifestations

In both of these diseases the eye is intensely red, but in acute glaucoma there is a more marked distinctness of the episcleral veins and anterior ciliary veins, so that they stand out in bold relief because of the interference with the return circulation occasioned by the intra-ocular pressure. The eye assumes a kind of purplish hue on account of the venous stasis. In acute iritis there

is more of a diffused pink color surrounding the limbus and extending over the globe. In acute glaucoma the cornea rapidly assumes a steamy appearance, resembling a pane of glass that has been breathed upon, while in acute iritis the cornea remains perfectly clear. The pupil in both cases is relatively immobile, but is especially so in acute glaucoma, and in this condition is widely dilated, while in acute iritis the pupil is inactive but contracted, unless a myriatic has been used, in which case the iris will show adhesions to the anterior capsule of the lens, giving an irregular outline to the margins of the pupils. The anterior chamber in acute glaucoma is much shallower than normal and may be entirely obliterated, the iris and the lens pressing against the cornea, while in acute iritis the depth of the anterior chamber is unaltered. If the media are sufficiently clear to permit of an ophthalmoscopic examination, the fundus in acute glaucoma will show some reduction in the caliber of the retinal arteries, with a marked increase in the caliber of the retinal veins, which are distinctly tortuous in their course, on account of the interference with the return circulation. There may be hemorrhages, also, especially of the venous type in acute glaucoma, and these are unusual in acute iritis. The optic disks, in acute glaucoma, if the condition has supervened upon a more or less chronic trouble, will show a marked excavation which is total in character and presents characteristic features that distinguish it from other forms of excavation of the optic disk. The entire lamina cribrosa is pushed backward by the intraocular pressure, so that the retinal vessels appear broken in their course over the rim of the sclera, while in atrophy of the optic nerve, there is a pallor of the disk and a slight diminution in the prominence of the disk, but with no actual recession of the lamina cribrosa. In a physiological excavation of the optic disk, the central portion may appear deeply excavated, while the peri-

pheral portions, containing the normal number of normal optic nerve fibres, will show no such depression.

The essential condition of acute congestive glaucoma is the increase in intra-ocular pressure, and upon this one circumstance develop all of the symptoms enumerated. The eyeball may vary in hardness from a very small increase, capable of being appreciated by the touch, to those cases of extreme hardness in which the eyeball is apparently hard as marble. This intra-ocular pressure is variously estimated, by palpation with the fingers, or, more accurately, by a tonometer, which measures in millimeters of mercury the intra-ocular tension. In acute plastic iritis there is no increase of importance in the intra-ocular pressure.

Whenever a patient becomes suddenly blinded, or has his vision rapidly reduced, associated with pain radiating to the brow, and the side of the head, with a dilated pupil, with a shallow anterior chamber, with halos around the light, and with increased intra-ocular pressure, caution the patient to secure at once not dilation of the pupil, but contraction of the pupil, and follow this with a careful investigation into the exact condition. Finally, in all cases of diminished vision, no time should be lost in ascertaining, as accurately as possible, the exact situation, so that remedial measures may be adopted promptly and not indefinitely postponed in the vague hope of better days.

It is a matter of utmost humanitarian and economic importance to secure vision for a patient when it is possible to do so rather than have the patient spend the final years of life in the fruitless waiting for complete blindness. This protracted delay simply results in the loss of general physical strength and endurance, so that when the patient finally reaches the stage of complete blindness he may be so enfeebled by the various infirmities of age that he is not in so favorable a condition for any kind of operation, and has such a poor remnant of life left that he may not have the cour-

age and confidence and strength to undergo an operation for the restoration of sight, and thus, hesitating on the brink of the grave, passes on from the darkness of this world into the deeper darkness of the great unknown.

A Nonoperative Treatment of Inflammatory Glaucoma. The ophthalmologist is often confronted with cases of glaucoma so desperate that any relief which could be afforded in addition to the means which were commonly employed would be most welcome. F. Park Lewis[5] states that it not infrequently happens that he sees a patient for the first time when the sight has been lost in one or both eyes and when little more could be expected by any methods than the relief of pain. In other instances operative measures were refused by the patient and such means must be employed to alleviate suffering, to retain vision and sometimes even to preserve the eyeball as might be found in any degree effective. These were such as not to give the surgeon or the patient much comfort.

Important as was von Graefe's discovery of the value of iridectomy, it has been replaced by the Eliot and Lagrange operations, and yet every surgeon of experience knows that the best results in the hands of the most skilled operators are often impermanent and unsatisfactory. Even though there were many cases of acute glaucoma in which the pressure symptoms were relieved by a filtrating scar and in which a very long or even indefinite period of safety might be secured, in other almost equally promising cases there might be an intra-ocular hemorrhage or the operation may be followed by degenerative changes in which the sight was nevertheless slowly lost. In fact, all the operative measures that have been proposed, of which between fifty and sixty were on record, were designed to relieve the intra-ocular pressure. The conditions that caused this increased pressure have not yet been learned, and

(5) M. J. & Record, May 18, 1927.

therefore the essential source of the disease can not be reached.

Posey's contribution was of great value when he demonstrated that in chronic glaucoma better and safer results might be obtained by miotics than by surgical procedures as long as increased narrowing of the visual field did not occur, but all the operative measures, as indeed practically all of the medicinal measures that had been used, had a mechanical purpose. They were designed to keep pervious the spaces of Fontana and to prevent the closure of Schlemm's canal in order that the intra-ocular circulation might continue as far as possible unimpaired. But except in secondary glaucoma the increased pressure was not in itself the disease any more than was the closure of the lymph spaces. These were evidences or symptoms of the disease while the real condition upon which these are dependent is as yet unknown.

Hamburger's theory considered that glaucoma must depend on an inhibition more or less complete, of the vasoconstricting mechanism, thereby producing a relaxation of the vessels and a consecutive repletion of the eye with blood. It would seem rather that there must be in the endocrine system two principles upon which the control of the circulation within the eye depended, one of these to stimulate and the other to inhibit. When the controlling secretions were produced in normal proportion the intra-ocular balance was preserved and when for any reason one or the other of these was in excess there was an interference with the intra-ocular flow and a consequent disturbance of normal pressure. These double secretory organs were found in the pituitary, the thyroid and the ovary. Might it not be possible that epinephrin was one of these controlling substances and that it acted less by its mechanical action on the vessels than by supplying that deficient element whose presence was essential to the maintenance of the normal pressure within the eye? Whatever might be

the theory of glaucoma there was no doubt that in some instances of acutely inflamed and painful glaucomatous eyes the longer wave lengths of the light spectrum, visible and invisible, seemed to have a definite value in relieving the symptoms and in controlling the inflammation. Its effect was so marked in plastic exudates in uveal trouble that the writer was led to experiment with it when similar conditions were found in glaucomatous eyes. In the half dozen cases reported there were none in which the effect was not immediate and gratifying.

Glaucoma Without Appreciable Rise in Intra-Ocular Pressure. After a more or less quiescent period in the progress of the study of glaucoma, attention is being drawn at times to border-line cases of what appears to be simple, non-inflammatory glaucoma, though they appear to have no appreciable rise in intra-ocular pressure. It has been said that such cases of glaucoma occur but seldom, and, though this may perhaps be true to a certain extent, the very fact that they sometimes present almost no rise in tension, together with the variation of their mild manifestations from those of typical, undisputed cases of glaucoma, leads one to believe that the number of cases of this type is not so small as it is unrecognized, and this evidently because of the very fact that they are associated with a very slight, and at times, no pathological increase in tension. It may perhaps also happen that there are periods of slight, temporary increase in tension in these cases during the intervals between examinations, thus accounting for the failure to recognize at least some of them as glaucoma.

With this type of case in mind, L. Nippe[6] reports the case of a woman, age 53, under observation at various intervals over a period of eighteen months, with at first very slowly diminishing vision in the left eye which became very much more rapid in its decline during the last six months of this period, the vision in the right

(6) Ohio State M. J., March, 1927.

eye not suffering any decrease until the latter part of this period.

This case was characterized from the start by shallow anterior chambers, slight dilatation of the pupils and periods of increase in tension so slight as to be very close to normal. The increased tension was always more marked in the left than in the right eye. The fundus examination, taken at the same time as the vision last mentioned, showed some slight radial opacities on the nasal side of the lens of the right eye but nothing further pathological. The left eye presented a deep glaucomatous cupping of the entire temporal side of the disk, extending from the region of emergence of the retinal vessels, which in this instance were displaced markedly toward the nasal side, to the undermined scleral border behind which the retinal vessels curled in typical fashion. There was also the ashy gray color of the disk in contradistinction to that of primary optic atrophy. Slight radial opacities were present on the nasal side of the lens of this eye also. The visual fields as tested with Lloyd's stereocampimeter were not typical of glaucoma as one commonly finds them, that of the right eye only showing a peripheral defect in the lower temporal region, while that of the left eye presented a scotoma continuous with the blind spot, and involving the entire nasal half of the field, the line of demarcation extending upward and slightly outward from the blind spot and below slightly downward but almost directly horizontally and outward away from the blind spot.

Fuchs, Elschnig, Lauber and others have observed cases in which there appeared to be no increase whatever in the intra-ocular pressure but the most logical explanation of the cause of the glaucomatous cupping in these, if not in all cases of glaucoma, appears to come from Elschnig, who says that "glaucomatous disease of the optic nerve is caused by absorption of the nerve fiber tissue and supporting structure of the optic nerve

as a result of its being affected by the intra-ocular fluid." He further states that "the rapidity of the progress of the cupping depends upon the nature and quantity of this fluid coming in contact with the nerve head." This theory also furnishes us with a very plausible explanation of the fact, proven in numerous instances, that miotics are frequently of no avail and that operations for the relief of intra-ocular pressure, though correctly performed, are in some cases followed nevertheless by progressive diminution of vision to the point of absolute blindness.

There are many questions that one could ask in this connection. One of them would be: Isn't the increase in the intra-ocular pressure just incidental in causing the optic atrophy? It would be possible to have a difference in the rate of secretion of the intra-ocular fluid also, though perhaps not to the same extent, a difference in the rate of drainage away from the eye. Assume that such were the case in some of the instances which have been referred to by Fuchs, Elschnig and others as having shown no variations in tension above normal, and assume that they had been observed every day during their entire course without showing a rise in tension above what we usually consider normal. This could easily be accounted for by increased drainage or diminished secretion of the intra-ocular fluids.

It seems that the most plausible explanation of the cause of glaucoma is to be found in the theory of changes in the optic nerve produced by changes in the intra-ocular fluid bathing it, the rate of progress of the disease depending upon the amount of this fluid coming in contact with the optic nerve in a given period of time. This may be constant in a given case, but then the concentration of the toxin carried in that fluid may vary according to the rate of production of toxin at its source as, for instance, in focal infections.

Regarding this type of case there are many questions which must remain unanswered for the present. How-

ever, this particular case is cited merely as a means of calling attention to the fact that there are many cases of chronic glaucoma, or at least stages of this or a similar type of disease, in which the pathological condition is progressing without an increase in the intra-ocular pressure.

Besides offering a plausible explanation of a clinical observation, Elschnig's theory opens up a wide and encouraging field for further research from which much enlightening information is to be hoped for.

Injuries and Foreign Bodies

Eye Injuries and Previous Condition. Seigrist of Berne[7] has recently studied the influence of the previous state of health on occupational injuries. The general state previous to the accident, especially in its relation to tuberculosis and syphilis, less frequently to arteriosclerosis and hemophilia, is susceptible of influencing occupational injuries. A contusion without any apparent wound may give rise to a local state and, if the subjects are, for example, tuberculous, the specific bacilli circulating in the blood become fixed in the tissues whose capacity for resistance has been decreased by the traumatism. In scrofulous ophthalmia—besides the internal factor of the disposition—the external stimulants, such as dust and minute foreign bodies, play an etiologic part of the greatest importance. Seigrist does not admit a tuberculous origin for parenchymatous keratitis, which he believes is almost entirely due to hereditary syphilis. This lesion is not the result of the action of toxins but the direct action of living spirochetes entering the cornea through the blood. This penetration is easy during fetal life but less so when the cornea has attained its complete development. The absence of inflammation persists as long as a "favorable state of allergy" is not disturbed by disturbances of metabolism, which allow

(7) J. A. M. A., June 4, 1927.

the spirochetes to attack the injured structures with success. Hence a contusion may cause a parenchymatous keratitis in hereditary syphilitic subjects. The influence of the local condition previous to the traumatism can readily be surmised in many instances. An exophthalmic eye is more exposed in case of an accident, a congenital ectopia of the crystalline lens to complete dislocation. A contusion which would not result in detachment of the retina in a strongly miopic one. Should a stye or a suppurating dacryocystitis exist, perforating traumas will become easily infected.

On the other hand, a trauma has no relationship with the pathogenesis of sarcoma; at the most it can accelerate the development of a pre-existing neoplasm. Corneal lesions supposed to be due to a long standing keratitis or to recent trauma may be mooted questions, and a competent ophthalmologist should be called as soon as possible after the injury in order to detect the corneal lesions and to come to a conclusion in respect of their age.

In cataract and morbid processes of the retina and choroid, identical lesions will be found in both the uninjured and injured eye. Very frequently, subjects having been the recipients of mild ocular traumas—such as foreign bodies in the cornea—attempt to show that by the accident they have lost a considerable degree of vision; frequently this claim is due to an amblyopia from astigmatism or a strong unilateral hypermetropia, chronic glaucoma, optic atrophy uveitis or other conditions.

Industrial Eye Injuries. The rapidly increasing use of agricultural machinery and the great increase in all types of industry all over America have resulted in a commensurate increase in injuries to the eye and its appendages. Workmen's compensation laws in many states may be subject to some justifiable criticism, but they have had at least one good influence, that is, workmen now attend to even minor injuries which they for-

merly neglected with not infrequent serious damage to vision.

Notwithstanding the protection afforded by the orbital rim and lids, the exposed position of the eye makes it peculiarly liable to accident and the delicacy of its structure renders accidents, which would elsewhere be trifling, of extreme seriousness to the earning power and happiness of the individual.

About one-twelfth of the non-fatal industrial accidents are to the eyes, and about one-tenth of our blindness is the result of industrial injuries. This necessitates an enormous industrial loss and an enormous expenditure for the upkeep of the blind, not to speak of suffering and unhappiness which cannot be measured in dollars.

By far the most common injury, according to J. B. Stanford,[8] is that from small foreign bodies in the eye, most frequently in the cornea. This is often looked upon by workmen as a minor affair, but all of us who have had some experience have seen eyes lost from neglected or improperly treated corneal foreign bodies. In every shop there is one man, often the foreman, who professes to be very clever at removing foreign bodies. His armamentarium comprises a looped hair from a horse tail, a sharpened toothpick and a pocket knife which doubles in the cutting of plug tobacco. While this operator sometimes fails to infect the eye, he always succeeds in destroying a large area of corneal epithelium and sometimes a part of Bowman's membrane. Stringent measures should be adopted in all industrial plants to prevent these men from attempting to remove foreign bodies from the eye. Unfortunately in many plants this dangerous practice is encouraged in the belief that economy is promoted. The contrary is true.

By using a sharp spud, corneal foreign bodies may be removed with ease and with little trauma. Butyn is the anesthetic of choice in these cases, for the anesthesia

(8) South. M. J., May, 1927.

is rapid, corneal desquamation is not promoted, as is the case with cocain, and the pupil is not dilated. After removal of the foreign body some sort of germicide, such as mercurochrome, should be used, and the patient should be instructed to use an eyewash hourly until bedtime. Frequently a workman will allow such a foreign body to remain in the eye for one or more days. In these cases the eye will show marked ciliary injection, and there will be an infiltrated area around the foreign body. A mydriatic should be used in these cases.

A number of cases of severe acute conjunctivitis have been observed following the lodging of sawdust on the conjunctiva of the lid. The inflammation is not unlike that which we have come to term "swimming pool" conjunctivitis and follows pretty much the same course.

In infected wounds of the cornea foreign protein is given early and in rather large doses. The injection of milk has undoubtedly saved many eyes that would have been lost without its use. Some years ago the author had a disagreeable experience with an abscess following the injection of improperly sterilized milk. Since that time ampoules of a milk product put up by one of our pharmaceutical houses has been used exclusively. The content of these ampoules is sterile, is much more easily administered than milk, and the effect is apparently the same. When an otherwise healthy adult appears with an infected corneal ulcer, 10 c.c. of the milk product is given under the skin of the abdomen, or 6 c.c. in the muscle of the buttocks. The patient usually had a marked reaction, but the discomfort is of short duration and the effect on the ulcer has been uniformly satisfactory. This is repeated or not as indicated.

In woodworking plants corneal abrasions and contused wounds of the eye are quite common from "flybacks." In the case of abrasions, cleanliness is the only treatment necessary in most cases. Butyn has proved to be of great value in these cases for the relief of pain, and has apparently no retarding effect on the regen-

eration of corneal epithelium. In contusions of much severity, cycloplegia is always indicated. No case of contused wound of the eye should be discharged without first making a careful ophthalmoscopic examination, as hemorrhage and rents in the choroid are not uncommon. The rents in the choroid are the result of contre coup and may be caused by a comparatively light blow. Dislocation of the lens, iridodialysis, rupture of the fibers forming the pupillary margin, detachment of the retina and hemorrhage into the sheath of the optic nerve should be looked for in all cases of contusion of the eye.

Perforating wounds of the eyeball are quite common, and care must be taken in these cases to determine the presence or absence of intra-ocular foreign bodies. The location of such injuries is also of great importance. The danger of infection in these cases is in direct ratio to the length of time the wound is left open. When these patients are sent to the office, it is the custom of the author to operate immediately rather than to waste time in sending the patient to a hospital. If necessary, the patient is later sent to the hospital. The operation, of course, consists in a toilet of the wound and the covering of the wound with a flap of conjunctiva. This procedure is by no means a new one but a surprisingly large number of oculists appear to be unfamiliar with it. It has saved many eyes that would otherwise have come to enucleation.

There is a regular order of the various steps of this operation which should not be varied. The flap is prepared preferably at the side nearest the wound to be covered. If one is careful in undermining the conjunctiva, the flap will be thin and may be easily stretched without undue tension on the sutures. The sutures are introduced and are ready to tie before the wound itself is touched. When the flap is ready, iridectomy if indicated, and other toilet of the wound are done and the sutures tied immediately. There is no difficulty in covering any part, or even all the cornea. The flap is not

disturbed until the sutures pull out, when it will slip back to its normal position. Such a flap will protect a corneal wound from infection, will insure good apposition, even in irregular wounds, and will furnish a blood supply to the normally bloodless cornea. If an intra-ocular foreign body is known to be present, it is, of course, removed before the wound is closed if the anterior route is advisable. The problems of intra-ocular foreign bodies must be met as they arise, since no set rule may be made to cover all cases. As a general rule, magnetic foreign bodies in the lens or anterior to it are removed through a keratome incision at the limbus. Probably the best procedure in the case of foreign body in the vitreous chamber is to make a small incision in the sclera and draw the foreign body through this. In these cases, make an incision through the conjunctiva and sub-conjunctival tissue down to the sclera. This incision is somewhat curved and a double-armed suture is introduced in the convex flap and an ordinary suture in the other flap. These sutures serve to retract the flaps during the magnet operation and then are used to cover the scleral wound with a double layer of conjunctiva after the method of Francis. The problems of non-magnetic foreign bodies are as numerous as the accidents. In no case should a surgeon attempt to remove a foreign body without first having it definitely localized.

Burns have usually been from electric flashes, hot metal and chemicals. Those that have given the most trouble have been the result of lime and molten metal. Workmen are still careless in the inspection for moisture of the vessels, implements and holes into which they pour molten metal, and they often neglect to put on their goggles.

So far as known, nothing new in the treatment of chemical and actual burns of the eye has been developed recently, except the use of picric acid in combination with a local anesthetic. The drug is put in an ointment.

In repairing wounds of the eyelids, care is necessary

to prevent subsequent ectropion and to prevent epiphora. This subject is thoroughly covered by the good textbooks on ocular surgery.

Many of the accidents with which we have dealt are preventable by proper lighting in shops, proper guards for machines and by enforcement of rules as to the wearing of goggles in certain occupations. There is apparently an increase in the number of eye accidents which we see on dark, cloudy days. Fortunately the insurance companies are now employing expert inspectors who give advice as to lighting, machine guards and other appliances for the protection of workmen.

The determination of percentage of permanent visual defect is frequently quite difficult, and much injustice has been done both to the employer and the employe in many cases. The reduction of the common fraction representing visual acuity by the Snellen standard to a percentage of vision for settlement of claims is obviously unjust. This, however, has been done and is still being done by those who have not thought deeply on the subject. The plan recommended by Snell of employing a maximum and a zero of industrial vision with the intermediate degree of visual acuity accurately related to the whole is entirely satisfactory for the determination of visual loss for distance. This plan, however, does not take into account near vision, fields of vision, nor aphacia. It is hoped that the American Medical Association will soon adopt a standard by which we may all be guided in the estimation of percentage of visual loss.

Ocular Therapeutics

Some Unusual Effects from the Use of Cycloplegics. In 1910, when Gifford reported a case of glaucoma brought on by the use of homatropin, only two other cases had been reported, and by 1916 he had been able to collect only eight more cases from the literature, including four more of his own reported in that paper.

But nearly every one who spoke in the discussion was able to add one or more cases, and it is probable that many more cases occur than those reported. E. C. Ellett[9] gives the details of three cases in which glaucoma developed after the instillation of homatropin, used for the estimation of refraction. In the first case the glaucoma appeared five days after the homatropin was used. In the second case nine days intervened, and in the third case about three weeks.

Since 1916 a few additional cases have been reported.

There are several points that appear from a perusal of the reported cases.

1. This form of glaucoma is more common in women.

2. The possibility of this unfavorable result is small. Millions of people have had homatropin put in their eyes and very few have ever developed glaucoma as a result of it.

3. Homatropin and other mydriatic drugs can not be said to cause glaucoma. They merely precipitate its development in eyes predisposed to its occurrence.

4. In the use of eserin and other miotics after the mydriatic has served the purpose for which it was instilled, we have an almost certain preventive of any trouble of this nature. Therefore the occasional occurrence of glaucoma is no more a reason for not using mydriatic drugs than is an occasional death from a general anesthetic a reason to withhold these blessings from those who need them. The dangers in each instance should be recognized and precautions taken to prevent their occurrence.

5. In more than any other form of glaucoma, that which follows the use of mydriatic drugs seems to be favorably influenced by miotic drugs and medical treatment.

6. It should be the invariable rule to instill a miotic drug in the eye after the test is completed for which the mydriatic was employed.

(9) New York State J. Med., May 15, 1927.

In four cases marked constitutional symptoms have been observed in patients who had some mydriatic drug instilled into the eyes. In three of these patients the mental disturbance was most pronounced, and it is probable that an error occurred in using hyoscin instead of homatropin, due to a mistake in labels on the part of the manufacturer. The symptoms were not serious and soon passed away.

In commenting upon this extremely rare complication, Duane says that glaucoma following the instillation of homatropin is certainly very rare. He used homatropin very frequently and, morever, quite often in the sort of cases in which glaucoma is most likely to develop, *i. e.*, subjects over 40. He has used homatropin more than 6,000 times, and has had only one case of glaucoma attributable to its use. It is noteworthy that in this case, as in Dr. Ellett's, homatropin had been used previously without ill effect. In addition, he had seen homatropin used in a great number of cases examined by others—in the clinics and in Dr. Herman Knapp's office when he was acting as his assistant, and in none of these was glaucoma induced.

It occurs so rarely that it furnishes no contraindication to the routine use of homatropin in refraction work. This is particularly so when we consider that as Dr. Ellett rightly says, this accident occurs only in those predisposed to glaucoma, who, we may be sure, would have developed an attack anyhow, and it is in that case rather fortunate, at least for the patient, that the attack should develop under our eyes so that immediate steps can be taken to relieve it and to proceed at once to further thoroughgoing treatment of the eye condition, thus unexpectedly disclosed.

Of course, we should be on our guard and try to avoid the production of glaucoma by a cycloplegic. Before instilling homatropin in persons of forty or over, he regularly takes the finger tension, and in cases of doubt the tension with the tonometer. It is a good plan in

the older subjects after the examination under a cycloplegic is over to take the finger tension again and to instill eserin.

One other rather more frequent inconvenience that occurs after the use of homatropin is an unduly prolonged effect on the accommodation. In this regard he has made studies in several thousand cases of homatropin cycloplegia. In all of these cases, careful measurements of the accommodation were made before the homatropin was instilled, and in a very large number further measurements were made a week or so later. The results may be thus stated:

1. An effect on the accommodation obvious to the patient, *i. e.*, interfering with his ability to read, lasts usually for about 48 hours. In some, especially in the young, the ability to read may be regained in 24 hours or even much less. This is no indication that the accommodation is not considerably affected, and hence reading sooner than 48 hours should be discouraged. As opposed to these cases there are not a few cases in which the evident disability of the accommodation lasts for from 48 to 60 hours.

2. The dilatation of the pupil usually persists for about the same period, *i. e.*, 48 hours and sometimes longer. It may be evident when there is no disability for reading.

3. In some cases the disabling effect on the accommodation and pupils is prolonged for several days (3 to 6). They ranged in age from 15 to 50 (five being under and five over 32), and for the most part showed a slight hyperopia and astigmatism. In several the cycloplegia was marked and, although eserin was repeatedly instilled, this had no permanent effect.

4. Apart from these cases, which certainly are quite rare, his observations show that quite generally during a period of some weeks after the instillation the accommodation when measured by careful tests is less than when tested before the drops were used. This causes the

patient no inconvenience as a rule, but it has a very direct bearing on the prescription of glasses. One conclusion, important in practice, is that it is unwise to attempt to prescribe a glass from a post-cycloplegic examination made within a week of the time the homatropin was instilled. If the examination is made sooner the residual deficiency of accommodation may be such that, particularly in presbyopic cases, we are led to prescribe a glass that is too strong for near work.

Whether this prolonged moderate deficiency of accommodation found after the use of homatropin represents a real reduction produced by a lingering effect of the drug or rather represents simply a relaxation due to the let-up allowed by the use of a correcting glass, cannot be definitely determined, although the latter explanation seems more probable.

In some patients—but fortunately very few—we find an actual idiosyncrasy against homatropin, which nauseates them or makes them feel faint or otherwise uncomfortable. In such cases another cycloplegic may be tried, but in general he has thought best to depend upon results made without cycloplegia.

In a few cases, on the other hand, homatropin renders the patient more comfortable, affording a sense of rest and relief. One patient, a physician, stated that for quite a period in her life her eyes were never comfortable except when under homatropin.

Dionin in Ophthalmology. After more than twenty years of experience with dionin in an industrial community, Edward Stieren[1] regards it as a most valuable ocular remedy, second in importance only to atropin and eserin in ophthalmic therapeutics. W. H. Snyder, in 1905, illustrated its physiologic effect on rabbit eyes, projecting upon a screen a number of slides which showed the usual signs of general edema, vacuolation of the cells, and dilation of the lymph spaces. He concluded that the action of the drug is purely local, and

(1) Atlantic M. J., January, 1927.

greatest where the drug has actually rested; that its most marked action is in eyeballs whose tension is increased; that it has some dissociating action on the intracellular cement substance, allowing a transudation of serum from a globe under pressure; and that its analgesic action is explained by its lessening of tension and the well-known action of the derivatives of opium.

Dionin is a valuable remedy in all acutely inflamed globes, equally potent in cases of hyper- or hypotension. As a resolvent of exudates, adhesions, opacities, or scars in eyes quiet after a siege of inflammation it is equally efficacious. *It must, however, be used energetically and persistently or disappointment is sure.*

Dionin is soluble in eight parts of water, twenty parts of syrup, and twenty-two parts of alcohol. Hence 12½ per cent is the strongest aqueous solution that can be made.

In all cases of acutely inflamed globes Stieren prescribes a 5-per-cent solution in addition to meeting the special indications in each individual case. Two or three drops of this solution are instilled into the eye, and ten minutes later, after the smarting has subsided and the characteristic conjunctival edema is at its height, hot compresses are applied continuously for ten minutes. This is repeated two, three, or four times in twenty-four hours, depending on the severity of the case. If, after three days of this procedure, results are not forthcoming, a small amount of dionin powder is applied directly to the globe, and the strength of the solution is increased to 10 per cent. Powdered dionin is applied at the daily visit.

In hazy and nebulous corneas and in corneal opacities and scars, striking results are often obtained by persistence in the intensive use of dionin. The conscientious ophthalmologist will endeavor to clear corneas no matter how hopeless they may appear at first. Scars and opacities from chemical burns, scars or ulcers, and dendritic corneas often resolve and disappear.

The use of dionin in clearing corneal opacities differs but slightly from treating inflammatory conditions. Invariably the home treatment begins with a 5-per-cent solution, three times daily, followed each time by hot compresses. The aqueous solution gives better results than an ointment. The patient is seen at least once weekly, when the powder is applied directly to the globe, a chalazion curet carrying about one-half grain being used. After a month's treatment a saturated solution is prescribed, and continued without interruption. The conjunctiva may at times show irritation, and an astringent solution such as zinc sulphate and camphor water is used concurrently, and alum is applied to the everted lids when necessary. The eye soon establishes a tolerance for the drug, and the phenomena of edema and congestion are not evident after a while, but the gradual and steadily increasing clearing of the cornea gives satisfying evidence of the continuous efficacy of the treatment.

As an addition to the above paper, J. G. Lin reports eleven cases of interstitial keratitis, three of marked corneal scarring, nine of trachoma, and one of lime burn of the cornea treated by the intensive use of dionin.

[Because of the intense reaction and local edema which so frequently follows the use of dionin, it is important, when prescribing this drug, to be used at home, to explain fully to the patient the action to be expected. Otherwise he will be unnecessarily alarmed.—Ed.]

Foreign Protein in the Treatment of Inflammations of the Eye. The intravenous injection of bacterial suspensions such as typhoid bacilli, colon bacilli or staphylococci; their intra-muscular injection in larger doses; the intravenous injection of bacterial or other protein split products such as proteases, of colloidal metals; of distilled water or hypertonic salt solutions, of various serums and antitoxins; the intra-muscular injections of milk or casein, etc., are all followed by a reaction that varies from a mere stimulation of leuco-

cytes, to mild febril reactions, and to extreme shock pictures associated with profound vaso-motor paralysis. The reaction varies with the substance used, with method of application and absorption, and its dosage; with the type of infection with which we are dealing; with the number of previous injections; with the physical condition of the patient; with the duration of the disease from which the patient is suffering; with the temperature of the patient at the time of the injection and other individual factors.

We do not know how much of the reaction that we elicit is necessary to bring about the therapeutic effect that we seek to achieve. We know that some substances provoke fever symptoms that are uncomfortable to the patient and yet seem quite efficacious in their results. On the other hand some substances are followed with only a mild reaction and seem much less effective than the methods that are seemingly more drastic in their actions and much more unpleasant for the patient.

M. G. Erehart[2] believes that the injection of foreign protein intramuscularly and intravenously, especially of milk and typhoid vaccine, in the treatment of eye inflammations, is one of the most energetic stimulants of the general defenses of the body. It constitutes one of the surest means of fighting the most varied of infections and particularly, infections of the cornea with ulceration, iritis, traumatic and post-operative infections, etc. It is very evident that injections of non-specific foreign protein, namely, milk and typhoid vaccine, exerts a marked influence on those infections in which it has been used. It is not believed, however, that this type of treatment is a cure-all. It does, however, open up new possibilities and suggests good methods for attacking infections of unknown etiology. That all cases might not be benefited does not reflect on the value of the treatment. There are very few therapeutic methods which do not have the same objection.

(2) J. Indiana M. A., April, 1927.

Eye Contra-Indications in the Arsenical Treatment of Syphilis. It is realized that there are certain eye diseases found in syphlitics which are extremely difficult to differentiate from eye changes that might result from the use of arsenicals in the treatment of this disease.

Ossian H. King[3] reviews the signs of arsenic poisoning, as revealed by certain eye changes due to the administration of arsenicals in the treatment of syphilis.

The fact that the eye may be affected in syphilis was revealed by some of the earliest medical writers. But not until the advent of the ophthalmoscope was there any knowledge of the intra-ocular changes that might take place in this disease. Since Hutchinson first gave the result of his studies in this field, much has been said and written upon the eye changes in syphilis. Ophthalmic evidence of the presence of a syphilitic infection in the unsuspecting patient has been found so often that it has taught us always to be on the lookout. In many cases the only clinical sign of a syphilitic infection is visible to the oculist.

As the knowledge of syphilis advanced the therapeutic attack has kept pace and at times has been in the lead. After the discovery of the causative factor a great stimulus was given to the search for a specific. Many drugs were tried and found wanting, while others proved to be of inestimable value.

As a result of much experimentation and research along this line by many different workers, we have the following named arsenicals: arsphenamin, neo-arsphenamin, sulpharsphenamin, silverarsphenamin, and tryparsamid, which are being used more or less successfully in the treatment of syphilis.

Experience with the earlier arsenical compounds revealed certain deleterious effects upon the eye. Studies to determine the cause of this reaction were made by various investigators.

(3) South M. J., April, 1927.

The arsenical compounds used in the treatment of syphilis appear to fall into two groups as far as the possibility of eye injury is concerned: a less dangerous group to which arsphenamin, neo-arsphenamin, silver-arsphenamin and sulpharsphenamin belong; and a more dangerous group including atoxyl and tryparsamid.

Case reports of optic lesions resulting from the use of the arsenicals in the less dangerous group have been hard to find. To the contrary, the reports have been encouraging as far as eye injury is concerned. Steindoreff, after the administration of fifty thousand injections of arsphenamin, says there were few, if any cases in which optic nerve injury could be honestly laid at the door of the remedy.

Laureret gives the result of six years' experience with arsphenamin treatment, but does not mention eye injury in his report upon the by-effects of arsphenamin and neo-arsphenamin in twenty-seven thousand injections to two thousand and eight hundred patients.

Injury to eyesight made unhappily familiar by early experience with atoxyl, and the close relationship existing between atoxyl and tryparsamid, caused much study of the latter arsenical before it was given to the profession at large. With the introduction of tryparsamid came the announcement that the main ill effect is an occasional tendency for the drug to produce optic symptoms.

Subjective symptoms should be the signals for immediate testing for objective evidence of injury. When an objective basis is found for the subjective symptoms, treatment should be discontinued for a time.

Diminution of visual acuity, contraction of color fields and changes in the fundus are symptoms that argue for caution when tryparsamid treatment is contemplated.

The risk is increased in tryparsamid treatment when, through lack of cooperation on the part of the patient, routine fields cannot be taken.

Hiram Woods, in discussing this paper, says that enough has been discovered and enough harm has been done to make the syphilologist, neurologist and ophthalmologist each conscious of responsibility in his own sphere. If a certain remedy can cure otherwise hopeless cases of neuro-syphilis, the neurologist ought to know about it. If, in its administration, harm can come to the visual apparatus, the ophthalmologist should know the danger signals and the man treating the underlying disease should be guided by his findings. These principles are applicable not alone to one or occasional consultations but throughout the course of treatment.

Among the accepted facts are: (1) that the arsenicals have sometimes a functional or destructive effect on the visual apparatus; (2) some are more destructive than others and have been abandoned; (3) it is through involvement of the optic nerves that trouble comes.

Tryparsamid is the particular arsenical now under study. Its function is to clear up luetic lesions of the cerebrospinal system, and its effects are somewhat analogous to the supposed effects of potassium iodid, upon which reliance has been put for generations. Tryparsamid therapy is applicable in general paresis, tabes, muscular paralysis, and other conditions of luetic origin.

A report from two observers as to the results of tryparsamid treatment stated:[4] "Among thirty-five paretics, six died during the course of treatment. Nine were worse after treatment than before. Three of them developed serious eye symptoms. Ten showed no material change following treatment. The remaining ten improved. The results with the fifteen cases of cerebrospinal syphilis were little different. Three patients died during treatment. Six showed no change whatever. Of the remaining six, two showed moderate improvement and four slight improvement."

Oculists who see cases of cerebral syphilis and who are familiar with the almost helpless issue of many of

(4) Am. J. Ophth., March, 1925.

them, should move slowly and then only under the guidance of an experienced syphilologist; should make periodical examinations of the eye background and visual fields while the case is under treatment, and should be hopeful of the result but by no means enthusiastically confident.

Radium in Ophthalmology. Laura A. Lane[5] makes a plea for more careful reporting of cases in which radium is used for the sake of future sufferers with glioma when radium and the roentgen ray appear to offer some spark of hope; for those with corneal opacities, tuberculous keratitis, keratoconus and trachoma which destroy vision as well as for those with many other intractable lesions of the eye in which radium appears to offer a considerable measure of relief.

This author has devoted more than a year to an experimental study of the effect of radon (radium emanation) on the normal eye of the rabbit, and also to a clinical study of the effect of radium on various eye affections, using radium element in some and emanation in others. In the experimental work, particular attention has been paid to (1) dosage, (2) screening, (3) immediate and remote clinical changes, (4) effect of radium on the intra-ocular tension, and (5) histologic changes. In every way possible this study has taken into consideration the practical application of radium so that results could be in general applied to the human eye if the findings seemed to warrant such application.

Of the patients treated by radium, she states that many of these patients had been under treatment for years. The cases of xerosis and acne rosacea were of eight years' duration, and both gave excellent response. Attention is called particularly to the corneal diseases treated. The results as to improvement in vision and deformity are most gratifying. In tuberculous lesions, radium alone or in conjunction with tuberculin has proved highly efficient. A patient with hopeless uveitis,

(5) J. A. M. A., Jan. 22, 1927.

reduced to light perception, was able to go about the ward alone. The improvement in corneal ulcers is often remarkable; practically all treatment except atropin as indicated and cleansing with boric appears unnecessary if radium is properly used. It relieves pain and congestion and promotes healing. The doses used have been from 0.75 to 1.25 mg. hours, applied every three to five or seven days at a distance of 2 mm., a platinum needle of 1 mm. thickness containing 15 mg. of element being used. Several cases have been tried with silver tubes using up to 25 mc. of emanation, but the results have been no better and there was considerable irritation, so that this method has been entirely abandoned for the first.

The results in trachoma do not appear so good, but are modified by the fact that four of the number were either able to take only a few treatments or immediately after starting the treatment were operated on.

After nearly five years' use of radium in the treatment of diseases of the eye, she has come definitely to the conclusion that the best results are obtained with the gama radiation in comparatively small amounts used over a more or less extended time except in those patients suffering with malignancy. It has also been found that the physical condition of the patient has much to do with the response to radium and the result. One cannot get results where the basal metabolism, for example, is lowered. Individual study of the patient, the type of the lesion to be treated and minute details in the application of the radium are very essential to attain best results.

Some years ago W. H. Wilder presented a case of epibulbar tumor of the sclerocorneal region supposed to be melanotic sarcoma by those who had seen it, and all advised enucleation, which was declined by the patient. Treatment with radium was carried on for a considerable length of time, at first with emanations, and although upward of eighty treatments were given,

they did not completely check the growth. Treatment with radium element seemed to be efficient, and after seven such treatments the growth disappeared. The patient when last seen, seemed to be in perfect health, with nearly normal vision, and with no sign of the growth and no sign whatsoever of any opacity of the lens.

Radium Therapy in Some Ocular Conditions. In addition to its use in malignant ocular conditions, radium has, in recent years, been applied to benign ocular lesions as well. There has been a lack of uniformity in the results obtained so that the value of radium in ophthalmology is still extremely doubtful in the minds of many.

Much of the experimental work done on the use of radium in the region of the eye is of no practical value today because of the change in the types of screens, this change being the result of our increased knowledge of the effect of radium. There have been numerous clinical reports of its use in various ocular conditions. A review of these in most instances is of little value due to a lack of detail of the method employed. Important items such as the amount of radium, type of container, whether element or emanations, screening, type of applicator, distance, time, and details of application have often been omitted.

That radium has a definite place in ophthalmology there can be no doubt. More careful clinical reports must be presented in order that we may arrive at a better standard to serve as a guide in the treatment of various conditions.

Walter Scott Franklin and Frederick C. Cordes[6] present a few cases of ocular lesions treated with radium. While these cases are more or less isolated ones, the results have been definite enough to warrant the assumption that the effect obtained was due to the therapy applied.

(6) Surg., Gynec., Obstet., May, 1927.

Only the positive findings have been noted in the following case reports.

CONJUNCTIVITIS

Case 1. Mrs. A. F. M., 67 years ot age, had been under observation for 11 years with a persistent chronic conjunctivitis, the result of the cicatricial changes of a trachoma contracted in childhood. There was a definite conjunctival hypertrophy accompanied by dilated ocular blood vessels and mucopurulent discharge. Bacteriological examination showed staphylococcus in pure culture. All the usual therapeutic measures, including vaccines, had been tried with only mild relief from time to time. The patient had seen many oculists here and abroad without permanent improvement. December 14, 1925, radium was applied. Ten milligrams of the radium element in an 0.8 centimeter circular plaque screened by 0.5 millimeter silver and a piece of rubber dam was applied over the closed lids for one hour at a distance of one centimeter. This was repeated twice a week to each eye for a period of four months. At the end of this time the condition was markedly improved. There was no discharge present and the lids had lost the thick puffy appearance they previously possessed. In addition, the ocular conjunctiva was now pale.

Case 2. Miss M. C., age 55, was seen in August, 1922, with a bilateral acute conjunctivitis that proved most resistant and developed into a chronic type with considerable hypertrophy and mucopurulent discharge. In addition, the bulbar blood vessels were markedly injected. After six months of unsuccessful treatment with the usual therapeutic agents the patient disappeared, to return in June, 1925. Treatment elsewhere had been of no avail and the condition remained the same. Radium was applied June 23, 1925, the method being identical with that of Case 1. After six months' therapy the condition had improved to such an extent that the conjunctivitis (including the bulbar) was practically normal.

Vernal Conjunctivitis

Case 3. Lionel V. D., age 11, case of aggravated vernal conjunctivitis. In addition to the use of copper sulphate and silver nitrate therapy, radium had been applied but was discontinued after a severe reaction. October 19, 1925, radium therapy was instituted twice a week to each eye, the dosage and method being identical with that in Case 1. The condition improved very materially the first two months, probably in part as a result of the change in climate. Following this the improvement was very slow. A stronger dosage was advised and on April 13, 1926, the above plaque of radium was applied screened only with rubber dam, directly to the everted lids for a period of one minute. Because of the size of the plaque, two applications were necessary to cover the entire lid. April 23 the other eye was similarly treated. On June 21, 1926, the same precedure was repeated on each eye. There was no acute reaction following this type of application. The lids are decidedly better but there are several nodules still present. The radium therapy will be continued.

Recurrent Pterygium with Hypertrophy

Case 4. Mr. J. P., age 48, reported to the clinic October 10, 1925, with the following history. Twelve years previously a rapidly growing ptergyium in the left eye was operated upon, and gradually recurred. The patient had been under the care of an oculist who stated that he had subsequently operated upon the pterygium (transplantation) three times, only to have it recur persistently. The left eye showed nasally a pterygium composed of a raised nodular mass encroaching upon the cornea for about two millimeters. There was definite contraction of the conjunctiva; below and nasally was a symblepharon. Because of the size and the lobulated appearance, malignancy was considered a possibility. A small piece of tissue removed for examination was reported to be granulation tissue with no evidence of malignancy.

Radium was applied October 29, 1925, a 53 millicurie capillary tube screened only by a strip of adhesive being held directly to the pterygium for four minutes. Two weeks later the patient had a well defined radium reaction that subsided gradually and coincident with this the granulation tissue disappeared. At the time of the last examination, September 14, 1926, there was present only a retrogressive flat pterygium, the blood vessels being markedly contracted. In this particular case only one application of radium was deemed necessary.

Corneal Malignancy

Case 5. Mrs. E. L. S., age 68, was seen May 7, 1925, and gave the history of observing a white spot on the right eye for the past few months that seemed to have grown slowly. It caused no symptoms. Examination showed in the cornea of the right eye an opaque roughly circular mass extending from the limbus to near the upper pupillary margin. The periphery appeared grayish white, flat and inactive, while the center was darker in color, finely lobulated, located in the adventitia and apparently extending to Descemet's membrane. From the limbus were both superficial and deep blood vessels extending into the growth. Diagnosis: Corneal malignancy.

On May 11, 1925, the eye was cocainized and 143.6 millicuries (emanations) in a small capillary tube screened with .5 millimeter silver and .5 aluminum was applied to the cornea over the mass for a period of five minutes. May 27 the mass seemed a little smaller. June 4, 1925, 264 millicuries were applied for three minutes, the same screening being used. June 25, the emanations not being available, a 10 milligram plaque (same as in Case 1) screened with .1 millimeter aluminum and rubber dam was applied for five minutes. This was repeated July 22. The tumor mass was now half its original size and the blood vessels definitely smaller. The dosage given June 25 was repeated August 12 and

again September 2. October 6, 135 millicuries screened only by a piece of adhesive were applied directly to the cornea for two minutes. This application was followed by a mild local reaction. The corneal process gradually subsided so that by January 6, 1926, only a flat scar remained in which there were several small areas that gave the appearance of calcification. The blood vessels were now barely visible. Subsequent observation has shown no change in the condition.

The cases here reported are all of the type that were resistant to the usual therapy, the type that frequently is a source of chagrin to the oculist, when, after extensive treatment, the condition remains unaltered. It is in this variety particularly that the possibility of radium therapy should be kept in mind.

In the conjunctival cases the desired result was obtained with much milder doses, that is at a greater distance and with more screening, than those used in the vernal conjunctivitis, the pterygium, or the corneal malignancy. Another factor to be observed is that the dosage, which with very little screening was applied directly to the everted lids, did not produce a reaction in vernal catarrh, but in the pterygium with its granulation tissue this amount produced a reaction. In the corneal malignancy the application of radium made unnecessary the enucleation of an eye that had .8 of normal vision before and after treatment. In this particular instance it seemed the only available therapy.

An interesting observation has been called to the authors' attention numerous times during the application of radium, particularly during the work on incipient cataracts in which a large series of cases was under treatment. Patients frequently commented upon the fact that indefinite neuralgia-like pains that had been present about the eyes and temples disappeared after a few applications of radium. They do not attempt to explain the reason for this.

Enucleation of the Eyeball with the Implantation of Endogenous Cartilage. Since sympathetic ophthalmia has occurred after failure to remove all of the sclera in an enucleation, all methods of exenteration are condemned. A good cosmetic result may be obtained by the implantation of autogenous cartilage in Tenon's capsule, as described by C. H. Bagley.[7]

After ordinary surgical preparation, a vertical incision is made over the sixth rib 5 cm. to the right of the midline. The insertion of the rectus muscle is split, exposing the fused cartilage of the fifth, sixth, and seventh ribs. The sixth and the anterior perichondrium are removed, the posterior layer being left to allow future regeneration. The usual enucleation is done, sutures being attached to the recti muscles during the operation.

After all bleeding has been checked by hot solutions or adrenalin, a graft composed of several layers of cartilage, secured by fine catgut and about three-fifths as large as the globe, is placed in Tenon's capsule. Tenon's capsule is closed with a pure string catgut suture, and three sutures of the same material are employed to close the subconjunctival tissues. The conjunctiva is carefully apposed to prevent infolding and is closed with a horizontal row of interrupted silk sutures.

No blood matching is necessary, the cosmetic result is good and permanent, sympathetic ophthalmia is eliminated, and there is little postoperative reaction.

New Instruments

Iridocapsulotomy Scissors. These scissors, devised by Conrad Berens,[8] have been found satisfactory for cutting dense secondary membranes, where de Wecker's scissors or Noyes' scissors would ordinarily be used, and for performing iridocapsulotomy. (Fig. 13.)

(7) Am. J. Ophth., 1926, p. 873.
(8) J. A. M. A., Oct. 16, 1926.

As the blades of the scissors are very thin and narrow, they may be introduced into the anterior chamber through a 2.5 mm. subconjunctival opening made at the limbus, a narrow Agnew keratome being used.

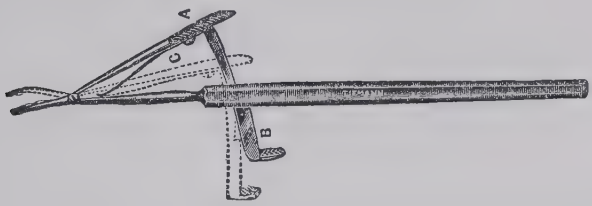

Fig. 13.—Iridocapsulotomy scissors: Dotted lines indicate position of blades when forced open.

This method is probably the one of choice, although the instrument was primarily designed to penetrate the limbus subconjunctivally without making a keratome incision.

Description of Scissors

The blades are 14 mm. long, pointed and slightly curved, and are held closed by a strong spring. One blade is the direct extension of the octagonal handle, which is 14 cm. in length. The other blade, which is movable, is activated by an arm (*A*), 48 mm. in length. This arm is joined to an arm (*B*) at right angles to it, which passes through the center of the handle 57 mm. from the tip of the blades. The scissors blades are forced closed by a strong spring (*C*).

Downward pressure on the end of arm *A* and upward pressure by the tip of the index finger under the angular end of arm *B* opens the blades. The blades are the same shape as the Noyes scissors except that both blades are pointed instead of one being dull. The action is entirely different; the Noyes scissors have the usual crossed scissors action, while these have the duck bill action, being always closed by a spring unless pressure or traction is exerted by the operator, which makes it easy to introduce and manipulate the instrument in the

anterior chamber. The Noyes scissors are always open unless pressure is made by the operator, making it practically impossible to turn the scissors in the anterior chamber. The Noyes scissors can be manipulated only from one side unless the scissors are removed from the anterior chamber, but arm *B* passed through the handle of these scissors makes them easy to manipulate from either side.

After introduction into the anterior chamber, either blade is passed through the membrane or iris after they are opened by downward or upward pressure of the index finger, depending on the direction of the curve of the blade desired by the operator. The spring closes the blades and will cut any but the toughest membrane, in which case pressure may be exerted by the index finger.

A New Ophthalmoscope. The image of an eye-ground as seen with an ophthalmoscope has a soft, blurred quality in which the finer details are obscured. Indeed the definition of the image falls far short of what would be regarded as satisfactory in most other optical instruments. The problem of improving the ophthalmoscope resolves itself into a consideration of the various factors which produce the blur in the ordinary image. These factors are thus enumerated by Jonas S. Friedenwald.[9]

1. The spherical aberration of the normal eye is very considerable and causes a blur in the ophthalmoscopic image which increases with the size of the observing aperture, and with any decentering of the observing system away from the axis of the observed eye. This aberration can be reduced to a minimum by using an observing aperature 2mm. in diameter, carefully centered along the optical axis of the observed eye.

The chromatic aberration of the eye is about five times as great as this minimal spherical aberration and can be reduced to a negligible quantity, either by inserting a correcting lens into the observing system, or by limit-

(9) Bulletin Johns Hopkins Hosp., April, 1927.

ing the spectral range of the light used to about one-fifth that of the visible spectrum. If such a spectral band is located near the violet end of the spectrum, the retina appears more or less opaque and a veil is cast over those structures that lie beneath its surface. This is true of the so-called "Red-Free Light." If the band is located at the red end of the spectrum, there is a loss of contrast between the retinal blood vessels and the general background of the fundus. The maximum definition can, therefore, be obtained by using yellow light of narrow spectral range.

3. A slight further gain in definition can be obtained by applying the method of oblique focal illumination which has been used to such advantage in the slit lamp corneal microscope. This aids greatly in the perception of variations of depth and elevation of details in the fundus.

An instrument has been constructed on these principles. The light from a ribbon filament bulb is first focussed upon a narrow slit. With the aid of a system of lenses and a mirror, an image of this slit can be focussed upon the observed retina. A color filter is inserted into the illuminating beam yielding a light, the wave length of which lies between 550*uu* and 625*uu*. By a suitable diaphragm, the illuminating beam can be greatly narrowed. This narrow beam can be decentered in relation to the observing system so as to produce oblique focal illumination of the retina, and also to extinguish the glare of light reflected from the surface of the cornea. By this means the eyeground can be examined through even an excessively narrow pupil, though the maximum definition of the ophthalmoscopic image cannot be obtained in such a case. By adjusting the decentration of the illuminating beam to the size of the pupil of the observed eye, the observing system is automatically centered along the optical axis of the eye.

The gain in definition of the ophthalmoscopic picture with this instrument is so great that a magnifying ocular can be used to advantage, and this has been supplied in the form of a small 2½ × magnifying telescope which is attachable on the observer's side of the ophthalmoscope yielding a total magnification of 37 diameters as against 15 with the ordinary ophthalmoscope. A fairly satisfactory view of some parts of the retinal capil lary bed is thus obtained.

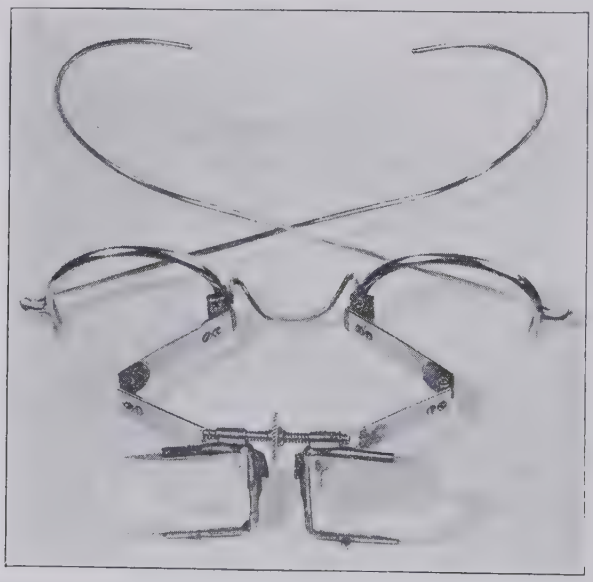

Fig. 14.—Folding Beebe Loupe.

Folding Beebe Loupe. The size of the case containing the ordinary loupe is a disadvantage when thrown in one's bag, for which reason G. F. Harkness[1] has devised a folding Beebe loupe, which can be carried in a small case in the oculist's bag. (Fig. 14.)

(1) Tr. Amer. Acad. Ophth. and Oto-Laryng., 1926.

Head Mirror. A head mirror, which is now available and exhibited by H. B. Lemere,[2] has the following advantages of the band head mirror (Fig. 15):

1. Lightness, due to small size and no metal back.
2. No pressure nor disarrangement of hair from headband.
3. Can be used with or without lenses in frame.

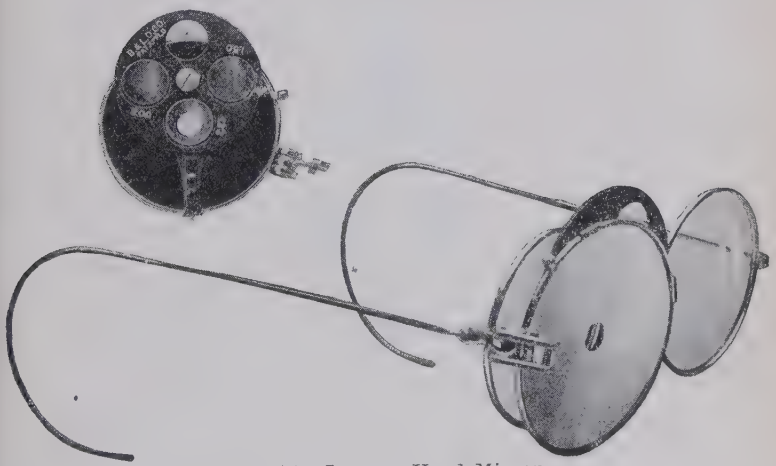

Fig. 15.—Lemere Head Mirror.

4. Battery of lenses can be attached or left off, replacing accommodative effort. The author has used it for indirect fundus examination.
5. Can be swung to one side over temple, when not in use.
6. Is easy to carry in spectacle case.

Charts for Testing Eyes. The difficulty of obtaining on the open market accurate test charts, to record distant vision, prompted E. B. Heckel[3] many years ago to have these made by hand. In this manner only could one be sure that they would be mathematically correct.

(2) Tr. Amer. Acad. Ophth. and Oto-Laryng., 1926.
(3) J. A. M. A., Aug. 6, 1927.

They were also made in sufficient variety so as to eliminate memory in making the tests. (Fig. 16.)

All of these letters, at their respective distances (200, 100, 70, 50, 40, 30, 20, 15 and 10 feet) subtend an angle of five minutes, while the component parts of the letters subtend an angle of one minute.

Fig. 16.—One of the series of charts for testing eyes. The full size card measures about eleven by twenty-one inches.

The original letters were all made within squares divided into twenty-five squares, respectively, and the letters were drawn in such a way that the component parts of the letters include the small squares.

These charts in lithographed form are now on market.

The Ear

ALBERT H. ANDREWS, M.D.

THE EAR

Hearing Tests

The Philosophy of the Older Tests of Hearing. In this article R. Sonnenschein[1] gives a sketch of the basic principles underlying the theory and practical application of the older tests.

The first group of tests include: (1) Observation of the patient; (2) Otoscopic examination; (3) Nasal, nasopharyngeal and pharyngeal examination; (4) Testing with speech (numbers whispered); and (5) Inflation with Politizer bag or by catheter.

The following fork tests are then discussed:

1. Tuning fork tests.

Range of hearing;

Lower limits from C2 (16 d. v.) upwards—*i.e.*, C1, C, c, c1, c2, c3, c5 (4096 d. v.).

Upper limits: *a.* Higher forks, c4 (2048 d. v.) and c5 (4096 d. v.); *b.* Galton whistle, preferably Edelmann-Galton whistle or Schaefer-Galton; *c.* monochord.

2. Weber test for lateralization. Fork placed on median line of vertes, forehead or root of nose.

a. Normally heard in vertex ("in the head").

b. Usually lateralized in worse hearing ear in conduction apparatus impairment. If both ears have middle ear affection sound goes to worse of the two ears.

c. Usually lateralized in the better ear if disease of perception apparatus is present in other ear. If both ears have perception impairment, sound usually lateralized in the better ear.

3. Schwabach test for duration of bone conduction in the individual as compared with the normal, usual living control, or comparing with average hearing for the particular fork employed. Fork usually placed on

(1) Laryngoscope, June, 1927.

median line of vertex or forehead; it may be sent on mastoids. Note whether bone conduction is normal, lengthened or shortened, a slight or diminution being of no significance. The age of the patient, the thickness of the hair or bones, the manner of application of the fork, firmness of contact of fork, etc., may give variation in length of bone conduction.

A definite lengthening of bone conduction means impairment of conduction apparatus (adhesions, fixation of stapes, etc.).

A definite shortening of bone conduction means involvement of the perception mechanism (inner ear or auditory nerve).

A decided change in bone conduction is in many ways the key to diagnosis and prognosis in ear disease.

4. Rinné test, for comparison of air with bone conduction in the same individual. The stem of the fork is placed on the mastoid (avoiding contact with auricle), and when no longer heard the prongs are held close to (without touching auricle or vibrisse) and parallel with the ear, and the duration of hearing by air noted.

If a negative Rinné is suspected, *e.g.*, if the Schwabach was found lengthened, test air conduction first and then bone conduction.

Normally the Rinné is positive (air conduction longer than bone). There are about eight varieties of Rinné (two forms of the positive, three varieties of the negative, two of the indefinite or plus-minus type and the so-called "infinite" negative, where there is no hearing via air, with slight hearing via bone).

5. Gellé test, for determining mobility of the foot plate of the stapes. Compressing the air in the external auditory meatus gives diminution of hearing in normal cases by pushing stapes into oval window; where fixation of stapedial foot plate is present no change in hearing occurs with increase in air pressure.

6. Stenger test, for unmasking simulation of total unilateral deafness. Two forks of exactly the same

pitch used; patient unaware that more than one fork is sounding. The fork nearer one ear drowns out sound of fork at other ear.

7. Audiometers are being used considerably in testing and with them one obtains accurate measurements of hearing in sensation units. Audiograms obtained give a graphic idea of the state of hearing which may be preserved for future reference and comparison. With properly calibrated forks provided with the "constant" of damping or decrement one is able to obtain a similar curve, but if many pitched are to be tested the process is somewhat more tedious than with the audiometer.

Resonators and other appliances should also be employed.

Three Million Deafened School Children. This report by E. P. Fowler and H. Fletcher[2] deals with the examination of school children in large groups. In this way the hearing of children in public schools can be checked without consuming too much time.

The apparatus consists of phonographic records with numbers, developed by the Bell Telephone Laboratories. In the process of recording, an attenuator was introduced into the electrical circuit in such a way that the intensity of each successive number is definitely 3 sensation units lower than the preceding one. In actual practise forty children are tested at one time. After the telephone receivers have been distributed and properly adjusted on the right ears of the children to be tested, they are told that they are going to hear numbers called, first by a woman and then by a man, who seem to be moving farther and farther away, causing the spoken numbers to become fainter and fainter. The children are instructed to write as many of these numbers as they can hear. The phonograph is then started. The first thing that they hear from the phonograph is the following: "You are going to have your hearing tested. Write the numbers which you hear

(2) J. A. M. A., Dec. 4, 1926.

in column 1." Then they hear numbers coming from the telephone receiver, the intensity of each successive number group being 3 sensation units less than that of the preceding one.

The test is given twice by a woman's voice, and then twice by a man's voice. The receivers are then changed to the left ears and the test is repeated. For testing the upper grades, a record having three-digit numbers on it is used, while for the lower grades a record having only two-digit numbers on it is used. It has been found impracticable to use this method for testing in grades below the second half of the second grade.

When the tests are completed the results are corrected against the master sheet, and the hearing loss computed. The authors believe that each school should have a quiet room for eye, ear, nose and throat examinations, and should have access to the phonograph audiometer just described (Western Electric Company, number 4-A) and a tone range audiometer (Western Electric Company, number 2-A), or their equivalents.

The authors give the following procedure of testing which they believe would be satisfactory to follow:

1. Preliminary testing in classes (groups of forty) in a quiet classroom, with the phonograph audiometer and questionnaire history, by a competent tester and an assistant.

2. Inspection after the regular school hours of the records made that day to determine those to be retested.

3. Retest of the borderline cases (about 18 per cent of the total) on the following day.

4. Tone range audiometer test of those low in hearing capacity, by same tester and assistant.

5. Careful otologic examination and diagnosis by a competent, paid otologist.

6. The recording on a prepared sheet of all the important data from the above tests for each deafened child.

7. A note to teachers through the principal, directing that front seats be given to the deafened children.

8. A note to each parent or guardian stating that the child is slightly, moderately, or markedly deafened in one or both ears, and that he should be sent to a first class ear clinic or a competent otologist to determine what can be done, if anything, to improve the hearing or prevent the progress of the disease. It should be stated that a seat near the front of the classroom will be provided for the child. The latter statement will aid in impressing them with the fact that there is really something the matter.

9. A check-up to see whether the child has been cared for as above, and the sending of a duplicate notice to parents or guardian if it has not been done.

10. Careful filing of the records, so that changes may be noted, and knowledge as to the detection of incipient and progress of promising cases gained.

11. Regular yearly testing of the whole school by the foregoing procedures.

12. The establishment of special clinics, probably as departments of our present hospitals, for studying and for handling difficult cases.

The educational treatment of the deafened children recommended by the authors is as follows:

1. Special classes for lip-reading should be provided in each school during school hours for the deafened child, which should be conducted by teachers trained to impart this knowledge. (This is now being done very efficiently in several schools.)

2. Special schools for the deaf should be provided for those having a great hearing loss. The amount of deafness requiring this special care should be determined from experience, after the first method of teaching has been put into practice.

Unfortunately, however, much of the effort expended in detecting and guiding these deafened children will be wasted because of the current lack of persistent study

and persistent treatment of ear diseases. There is no doubt that the surgical cases will receive, on the whole, excellent attention for the surgical condition; but when this is arrested, these as well as the nonsuppurative cases will largely drift and founder. Persistence in repeated examinations and care of the deafened children is essential if we are ever to arrest, improve or cure large numbers.

The League for the Hard of Hearing is striving to interest the nation in this vital matter. Many educational authorities are even now seeing its importance, and are getting ready for action; and it behooves all physicians and especially otologists to do their part, and lead, in this hitherto neglected work of the conservation of hearing. It is in the young and only in the young that much can be accomplished.

Technic for Voice Test of Hearing. D. MacFarlan[3] offers the following technic for voice tests:

1. The record sheet should contain the usual brief of age, occupation, chief complaint, family history, previous medical history and the history of the present illness. It is surprising how full and instructive even a few lines on the above topics can be.

A short note on the physical examination of the ears, nose and throat should follow. To this can be added any remarks on the outstanding general condition that may appear to be relative to the subject. For the hearing tests it is most important that the nervous stability should be noted. This should never be omitted from the record of any hearing test, since it means so much in the interpretation of the results. There should now be added some comment as to the set of the test. Thus: "Subject is alert and intelligent," "the setting was standard and quiet." (By "standard" is meant the setting that one familiarly uses.) Though this remark may mean nothing to others who read the records, it avoids lengthy notes and means much to the examiner. Again

(3) Arch. Otolaryng., January, 1927.

one may note: "The subject is ignorant and slow, test slightly disturbed by street noises and by constant interruptions;" or, "the subject is of the neurotic, nervous, erratic type; responses were alert, and the setting was quiet."

2. The hearing stimulus used should be mentioned. Thus: "Stimuli, numbers 1 to 10"; "Stimuli, test words monosyllables"; "Stimuli, simple questions".

3. "Set" of the test: The room should be quiet and as free from all distractions so far as possible; extraneous noises should be minimized and interruptions avoided. The patient should be seated preferably in the middle of the room away from the walls, and should be facing at right angles to the direction of the sound, that is, the tested ear should be turned toward the examiner. The untested ear should be stopped by the patient's moistened finger. The pressure of the finger should be gentle, not firm, and just sufficient to occlude the canal. Strong pressure affects acuity in the opposite ear.

4. The floor or baseboard should be chalked off in feet or meters distant from the patient. Hearing distance is recorded and set down in its relation to the normal hearing distance for the same stimulus. The ratio sign is used (:), not the fraction sign (/).

5. The examiner who has cultivated a monotone of intensity commensurate with the size of the room should approach the patient from the inaudible to the audible limit. He should speak or whisper as he approaches, not the same stimulus, but variations of the stimulus. There should be no effort at emphasis or inflection, but articulation of the vowels should be clear, not slurred. With the whispered or spoken voice, the use of the residual air gives a greater uniformity in the intensity or loudness of the voice.

6. A few preliminary tests should be made in order to familiarize the patient with the experiment, and in order that the examiner may strike a satisfactory mono-

tone. Some minor details of error that can be corrected by these preliminary tests are usually found.

7. Successive repetitions of the same test stimulus should be avoided and as far as possible all factors that call to any extent on "the higher auditory centers."

8. Tests should be repeated for the confirmation of results, but repetition should not extend to the point of fatigue.

9. A variety of from five to ten test words should be used for each distance before conclusions are formed as to the hearing at this distance.

10. The test should be postponed if for any reason uncontrollable mental or physical variables of extreme degree enter, for example, crying spells, stubbornness (in children), antagonism of the patient, malingering, obvious guessing, extreme confusion, distraction or fatigue, inability of the examiner to maintain a monotone or disturbing extraneous noises or interruptions.

11. The introduction of any variables in the technic is valuable information and should be noted.

Tests other than the voice test call on simple and single auditory qualities to test hearing; the forks and cylinders use single pitches of simple musical character. They always produce the same tone and have a certain initial amplitude that dies away. The whistles and the monochord are also comparatively simple, colorless stimuli with the added feature of the possible variation of the pitch. The audiometers of Iowa University (Dean and Bunch), of John Guttman and of the Riverbank Laboratories (F. W. Kranz) are instruments using simple tones that cover a wide and continuous range, giving a variation of amplitude for the various pitches. The Western Electric audiometer (Fletcher) and the foreign audiometers all use single pitches, or a series of single pitches that can be varied as to amplitude. These instruments are excellent for determining the limits of hearing for simple tones, and they actually give a perimetric picture of the hearing, but they can-

not test the hearing of speech as satisfactorily as the voice test. This is evident to any examiner who tries to draw conclusions from these tests alone as to what will be the ability to hear the voice in a given case of deafness. Patients hearing the voice well may show great error in the other tests, and the reverse also may be true. The entire reason for these discrepancies or lack of relation is not clear.

In conclusion, so many variables in the voice test have been cited that it seems that its merits must be overshadowed by its faults. The chief difficulty is in the inability to produce a dependable, standard and ponderable stimulus by voice. This is impossible, as the voice is a complex of pitches and amplitudes; thus a complex of intensities.

As a test instrument, the voice is limited to the field of 300 to 3,000 double vibrations, and the pathologic changes of hearing, so far as deafness is concerned, lie most demonstrably at hearing limits above and below this field. Other tests are better for determining the degree of deafness at the upper and lower extremes of hearing.

To obtain results of any value with the voice tests, the greatest care in technic must be exercised. This care is more important with the voice test than with any other hearing test.

It cannot be said that the test is of any great quantitative value in determining the degree of deafness, nor is it of great value in distinguishing the type of deafness, for the stimulus is uncontrollable, undependable and imponderable.

As it is impossible to fix a standard voice stimulus, it is obviously unsatisfactory to report results in terms of hearing distance. The examiner himself cannot repeat identical conditions (particularly as to voice intensity) on successive testings. No two examiners will obtain identical results. However, if voice hearing is to be

reported as to distance heard, it is imperative that the normal hearing distance be noted for the stimulus used.

When testing the more simple sensory phenomena of hearing, it is most important to use care in recognizing, in valuing, in excluding, in minimizing and in standardizing the higher mental factors such as attention, alertness, anticipation, ardor, distraction, indifference, fatigue, memory, training and general intelligence.

With care in technic, the voice can be put to its greatest use in testing speech interpretation. In this case it must be used at the interpretation threshold where hearing begins to become distinct.

It is reasonable to retain the test in spite of its variables, for as speech hearing is the most important function of the ear, and as the voice test uses as its stimulus the very thing which is most important to test, one is dealing with a direct method. Other auditory tests cannot test speech hearing as well, for they can but test simple, single auditory qualities. The voice test then would seem to resolve itself into a rough test for speech hearing distance, and into the most valuable test for speech interpretation.

The External Ear

Pre-Auricular Fistulæ. F. A. R. Stammers[4] reports six cases of pre-auricular fistulae. They were all situated in the root of the helix (Fig. 17). The six cases came from two different families (*a*—son, mother, son of mother's sister, and maternal grandfather; *b*—a daughter and her cousin).

2. Two of these fistulae had undergone occlusion of the opening with subsequent suppuration. These fistulae are not remnants of the first branchial cleft, but result from aberrant coalescence of the six tubercles which are destined to form the pinna.

(4) British J. Surg., October, 1926.

A Case of Primary Diphtheria of the Outer Ear. C. Veits[5] describes the case of a woman, aged 41, who had had a furuncle in the outer canal of the left ear which had been incised January 5, 1925. The patient again came to the clinic one week later. The area of the former abscess, which reached to the concha, was reddened and swollen. During the next days the eczema spread to the

Fig. 17.—Pre-auricular fistula in left crus helicis, with ulcer below. At the level of the lobule is a pigmented mole.

outer and posterior portion of the auricle and toward the angle of the jaw. Grayish brown-black crusts had formed; the rest of the canal was filled with a grayish white mass. After one week the corium and the cartilage at the helix and tragus were laid bare. On February 15. fetid pus was present. The operation of removing a crust led to excruciating pain and hemorrhage. Nine days later, the patient received 0.45 gm. neo-arsphenamin intravenously.

(5) Ztschr. f. Hals-, Nasen-u. Ohrenh., July 31, 1926.

In 1909, the patient had attempted to commit suicide by swallowing numerous needles, and a laparotomy had been performed at that time. The patient said that on December 30, 1924, she had scratched the ear with a needle, and that a child had pushed her which had caused the needle to enter the canal. In November, 1925, three needles could be seen in the roentgenogram. On November 24, two whole needles were removed. The one in the throat was covered by the external jugular vein; the outer end of the other was in the sternocleidomastoid muscle. The disease lasted more than six months, while cases described so far had a duration of only from two to eight weeks. The unfavorable tendency to heal was probably a consequence of angioneurosis. Three relapses occurred on the left side. Later, otitis externa developed on the other side also, with grayish white pseudomembranes and violent pain. The pain disappeared almost immediately after a dose of 2,000 units bovine diphtheria serum had been given. Within twelve days, five additional injections were given. The patient suffered from hysteria and vasoneurosis.

The author states that diphtheria of the outer ear canal develops from the middle ear, or follows an injury or another inflammation (Kraussold, Gruber, Baginsky). The infection through foreign bodies has not been described so far. Perhaps the patient, who was a carrier, had infected the needle by moistening the thread while sewing. It was difficult to influence the process therapeutically. Acriflavine was used. Diphtheria serum was applied subcutaneously. Neo-arsphenamine, permanganate of potassium and mercurial ointment were used. Acriflavine and diphtheria serum, applied locally, seemed to be ineffective. Diphtheria serum used parenterally was of surprising effectiveness, especially at its first application. The pain disappeared immediately, and most of the membrane could be removed the next day. Healthy granulations appeared, so that at first two injections appeared to control the process, but this

was not the case. As anaphylactic symptoms were feared at the next relapse, the serum was used locally but without result. An injection of a flavine dye was also without result. When the process appeared on the other ear, bovine diphtheria serum was used. The pain disappeared promptly, while the objective picture was scarcely changed. This relief from pain is caused by the serum without influencing the fever and other symptoms in diphtheria of the middle ear and of the external auditory canal, and this has also been observed by Daae. In similar cases larger doses might be recommended. A larger dosage of bovine diphtheria serum could not be obtained for the patient. Permanganate of potassium and especially mecurial ointment (Hilgenreiner) seemed to have a decidedly favorable influence on the fetid odor.

Protein-Body Therapy in Chronic Eczema of the Ear. A nonspecific milk preparation, autoserum and autovaccine were used by H. Sternberg[6] without any other therapy. Secondary infection, swelling and furunculosis disappeared. In only one patient with furunculosis did the milk preparation fail to give any results. Autoserum was also ineffective, but autovaccine cured the patient, although the eczema was not affected. The results of injection of protein bodies were negative for eczema. The treatment is highly recommended for secondary furuncles.

Intractable Forms of Dermatitis of the External Ear in Cases of Chronic Suppurative Otitis Media. F. C. Omerod[7] deals exclusively with the changes in the external ear resulting from chronic suppurative middle-ear disease of from eight to twelve years' duration. The changes in the external ear vary from a slight desquamative eszema to a massive perichondritis with deep fissures and stenosis of the meatus.

Of thirty cases, all but one showed some degree of

(6) Ztschr. f. Hals-, Nasen-u. Ohrenh., 17:200, Jan. 31, 1927
(7) J. Laryng. & Otol., 1927, xlii.

stenosis of the external meatus. In thirteen, there was eczematous excoriation, and in eleven a fissuring of the skin in or near the meatus. In twelve cases a uniform increase in thickness of the ears or massive perichondritis was noted.

The treatment consisted in the use of fluid reagents and ointments. Of the pigments used, solutions of silver nitrate in spirit of nitrous ether gave the best results, particularly in cases with massive perichondritis or fissure. Calamine or yellow oxide of mercury ointment was particularly effective.

Long-continued regular treatment resulted in clinical improvement, but no positive cures were recorded.

Common Inflammatory Affections of the Skin of the External Ear. A. M. Gray[8] discusses pyogenic infections of the skin of the external ear. The streptococcal group includes erysipelas which is characterized by intense local redness and swelling of the ear and severe constitutional symptoms. The most common streptoccocal infection is impetigo contagiosa. The simple type is characteristic. In cases secondary to purulent otitis media, the simple variety is often complicated by diffuse inflammation of the surrounding skin. In addition to mechanical removal of the crusted lesion, mild antiseptic solutions and ointment such as Lassar's paste are used. The author emphasizes the value of the *x*-rays. Roentgen treatment is advocated also for chronic inflammatory dermatoses.

Impetigo frequently occurs as red patches in the postauricular sulci.

Furunculosis of the external canal is usually the result of staphylococcal infection. General tonic measures with local incision of the mature lesion are advocated. The author concludes that autogenous or stock vaccines are not to be relied upon in these cases.

Eczema is defined as "a superficial serous inflammation of the skin which varies considerably in type in

(8) J. Laryng. & Otol., March, 1927, xlii.

relation to the intensity of the irritant applied or to the sensitiveness of the particular skin, but which has no specific characters sufficient to indicate its causation.'' Acute eczema may be caused by various chemical, physical, or parasitic agents. The primary step in the treatment is the isolation of the specific irritant. Sedative lotions should then be used. Some cases, the so-called infectious eczematoid dermatitis of Engman, are due to low grade pyogenic organisms. In chronic eczema the ear is usually red and scaly.

Seborrheic dermatitis may be limited to the ears, but typical patches are usually found on the forehead, around the nose, and on the trunk. The lesions consist of scaly eczematous circumscribed patches. Weak sulphur and salicylic acid ointment usually clears up the condition.

Psoriasis is associated as a rule with typical lesions on the extensor surface of the limbs or on the trunk. Chrysarobin, pyrogallol, or tar ointments are commonly used.

Angioneurotic edema may localize in one ear. Erythema pernio frequently attacks the helix of the ear. In the latter condition, glandular extracts, local massage, and calcium salts are beneficial. The chronic form of lupus erythematosis is frequently seen on the ears.

Herpes simplex of the ear may occur in any febrile condition. Herpes zoster is uncommon.

Lupus vulgaris may spread to the ear from the face. The primary lesion is a pinhead-sized granuloma beneath the epidermis surrounded by a zone of vascular congestion. A group of ''lupus nodules'' form a characteristic patch. These patches may ulcerate.

Primary chancres of the auricle are rare. The papular and pustular syphilide are fairly common.

Otomycosis; Report of Three Cases. P. M. Lewis[9] reports the following three cases:

Case 1.—Mrs. F., aged 40, had never had any ear trouble until four days previously, when she noticed an

(9) J. A. M. A., July 9, 1927.

itching and fulness in the right ear. Examination showed a large whitish gray mass, completely covering the membrana tympani and the lining of the bony canal wall. Strong irrigation dislodged the mass, which was like a cast of the drum membrane and inner canal wall. It was definitely a fungus growth macroscopically, so microscopic examination was not made. The ear was scrubbed out with 95 per cent alcohol and 2 per cent salicylic acid in alcohol prescribed for use at home. There were no further symptoms and no recurrences.

Case 2.—Mrs. F. M. P., aged 26, stated that the left ear had been stopped up for two weeks, and that there had been considerable itching and rather severe pain for the past two days. Examination revealed a very large, yellowish white mass which filled the inner portion of the canal and covered the membrana tympani. The same treatment as in case 1 was used with immediate relief of all symptoms. Microscopic examination showed the growth to be a mold, *Aspergillus flavus.*

Case 3.—G., a man, aged 20, stated that the right ear had felt stuffy for four weeks, had itched a great deal, and for the past week had been very painful. Examination showed a dirty grayish mass covering the drum membrane and the anterior and inferior canal wall in its inner half. The treatment used in cases 1 and 2 was employed with the same result. Microscopic examination of the mass showed *Aspergillus niger.*

J. Miller states in his report that his two patients had been using olive oil in their ears. It is the usual teaching that oils or glycerin have been used in ears which develop otomycosis. Bezold found that 75 per cent of all the patients he saw had been using them. None of the author's three patients had ever had previous ear trouble. They were all intelligent, educated people. None of them had ever used a drop of any kind of oil or glycerin in their ears. It is now the author's belief that the history of oils having been used is a mere coincidence. People have a deep-rooted conviction that

oils and glycerin are very beneficial for ear ailments, especially if there is any pain or itching. It is therefore obvious that a large percentage of patients with otomycosis will give a history of having used "sweet" oil or something of the sort in their ears.

Why these fungi lodge and grow in some ear canals is not known, but the diagnosis is extremely easy and the treatment very simple and efficacious.

The Middle Ear

Artificial Perforation of the Drum Membrane to Improve Hearing: A New Method to Create a Persistent Perforation. In the seventeenth century, Riolan recommended excision of a part of the membrane of the drum in order to cure hardness of hearing. M. Schirmunsky[1] mentions the subsequent efforts of many others to create a permanent opening in this membrane by partial resection, without success. In forty-seven patients suffering from otosclerosis, Lucae excised the whole membrane of the drum and removed the hammer and anvil fifty-three times. In twenty-eight cases improvement of hearing was noticed; in twenty-one the defect in the membrane remained permanent. In 1890 the author reported a new method to create a permanent perforation of the membrane of the drum. The quadrant of the membrane chosen for perforation is touched repeatedly with a 10 per cent cocain solution. (Later, the author mentions the use of a 20 per cent cocain solution with a little epinephrin). The membrane of the drum is then incised with an ordinary paracentesis knife, vertically or by cross-cuts. After the wound has become dry, the edges of the cut are touched with crystals of chromic acid fused to the end of a silver probe. Care must be taken not to touch the mucous membrane of the promontorium. The reaction of the membrane of the drum

(1) Ztschr. f. Hals-, Nasen-u. Ohrenh., 17:97, Dec. 18, 1926.

is insignificant. There is little pain, and it is of short duration.

The author employed the artificial perforation in a large number of cases with success. Eleven cases were observed for from two to ten years. The anatomic histologic observations of Zuckerkandl led the author to choose a spot at the umbo of the handle of the hammer where the circular fibers are absent and where the lamina propria shows only radial fibers. The object of artificial perforation is to allow sound waves to go directly to the labyrinth in cases in which the sound conduction from the membrane of the drum to the stapes is interfered with. Of the five indications of Politzer, the author considers chiefly the first two: (1) abnormal thickening and calcification of the membrane of the drum, and (2) fixation of the hammer and anvil to the walls of the tympanic cavity, either directly or by adhesions.

The noises are usually affected favorably.

The author reports eleven cases. Myringotomy was performed in order to improve the hearing, usually in patients who had become hard of hearing in consequence of suppuration of the middle ear.

Technic of Vibratory Massage of the Tympanum Through the Eustachian Tube. D. Vasilin[2] reviews the anatomy of the middle and internal ear and discusses the physiology of hearing.

External vibratory massage does not influence very much either the movements of the tympanum on account of its retraction and concavity, nor a distribution of the elevation of tension in the tympanic cavity nor the movements of the ossicles.

In a new method of giving massage, the two tubes of Delstanche are used. One tube is introduced through the nose into the eustachian orifice; when the operator has been convinced that the inflation reaches the middle ear satisfactorily, the other tube is introduced into the ex-

(2) Arch. internat. de laryngol. otol. rhinol., Sept.-Oct., 1926

ternal auditory canal, and massage is carried on for fifteen minutes.

The theoretical and practical advantages of this method are: Massage applied to the convexity of the tympanic membrane is more effective than when applied to the concavity. By this method, massage is applied directly to the ossicles and the muscles; this direct association with the electrical current may cause complete recovery of function in cases of greatly impaired hearing of the catarrhal type. The massage may be applied directly to the secondary tympanum. This method is superior to the method of Politzer, and there is less danger of causing tympanic perforation or emphysema of the mucosa.

Visualizing of the Eustachian Tube by the Roentgen Ray. Satisfactory radiograms of the eustachian tube have been made by W. Spielberg[3] by using the following technic. After the mouth and pharyngeal end of the eustachian tube has been anesthetized in the usual manner, a No. 4 silk catheter is passed through a pliable silver eustachian catheter into the eustachian tube and inserted about 3 or 4 cm. within the membraneous portion of the tube. The silver catheter thus becomes anchored in one position; from 10 to 15 drops of iodized sesame oil, 40 per cent (iodopin) solution, is then instilled drop by drop into the eustachian tube and blown into it either with a small air pump or with a soft rubber bulb attached to the end of the silk catheter.

With the aid of a diagnostic tube, as well as by the sensation of fullness experienced by the patient, the operator can tell the progress of the iodized oil as it fills the eustachian tube.

The technic employed in making roentgenograms of the eustachian tubes is essentially the same as that used in the examination of the mastoids. The patient is placed prone with the head turned on the side to be examined on a 15-degree inclined block. The pinna is

(3) Arch. Otolaryng., April, 1927.

pulled forward, and the patient's head then rests on the mastoid process. A fine focus is used, and a short cylindrical cone is adjusted to the tube stand. The focal point is found by drawing a line horizontally across the external auditory measure, and then another vertically to this at a point 1½ inches posterior to the external ear. The focal point is located 1½ inches above the horizontal line.

The results of his experiments are:

1. By employing a proper technic, roentgenograms can be made of the eustachian tube. The roentgenograms show that the eustachian tube assumes the course of an inverted S, making two curves as it leaves the tympanic cavity arching downward and forward across the space between the anterior canal wall of the bony external auditory meatus and the condyle of the mandible. Crossing the latter, it continues in its course downward for from 15 to 20 mm. and describes another slight curve downward and forward, terminating as the pharyngeal end in the pharynx.

2. The length of the tube is from 30 to 33 mm. from the mouth to the tympanic end. Its length can be increased by passing a metal filament into the tube, thus putting the membranous portion on a stretch.

3. The tympanic orifice of the eustachian tube is from 2 to 2.5 cm. higher than the pharyngeal end, but in some cases has been found to be only 1 cm. higher. The osseous portion, as well as the tympanic opening, appears as a prolongation of the anterior superior portion of the tympanic cavity. The superior wall of the tympanic cavity merges into the bony portion of the tube.

4. The bony and membranous portions can easily be differentiated from one another and their course visualized. The bony portion forms one-third and the membrane-cartilaginous portion two-thirds of the entire length of the eustachian tube. The width of the bony portion was found to vary between 2 and 3 mm.,

the width of the membranous portion between 1 and 1.5 mm.

5. Strictures or stenoses can be distinctly visualized and located.

6. The iodized oil instilled into the tube was retained only a few minutes. Both the act of swallowing and the action of the celiae cause the rapid evacuation of the foreign matter injected into the tube. This, however, was found not to be the case in patients with dilated tubes or in those in whom atrophic changes had taken place in the lining ephithelium. In one such case the roentgenograms showed the presence of iodized oil one week after the initial injection.

The Ossicles in Middle Ear Suppuration and Their Comparative Size in Children and Adults. While the malleus and incus are surprisingly resistant to caries in middle-ear suppuration, their function is often interfered with by softening or destruction of the supporting structures and in more than 50 per cent of the author's cases the larger ossicles were completely destroyed or in the terminal stages of necrosis.

J. A. Keen[4] describes operative specimens of the most common lesions and includes in his article several plates. The relationship between age and size is discussed.

The non-articulating portion of the head of the malleus is attacked most frequently, whereas the long process remains relatively intact. On the other hand, the short process of the incus is resistant and the long process frequently involved.

The author concludes that the ossicles do not vary greatly in size and form: "As far as the middle and inner ear are concerned, we may take it as an accepted and proved fact that full adult dimensions are already present at birth, and that no further growth in size takes place."

(4) J. Laryng. & Otol., March, 1927, xlii.

Latent Influenzal Otitis in Children. P. Gautier[5] discusses the frequency of otitis in children, and the difficulty in its diagnosis. He states that the recent influenzal epidemic showed that latent otitis was of common occurrence; it is easy to overlook this complication. Early and energetic treatment is important. Latent otitis is often found in infants and in older children, either alone or as a complication of some other disease, though influenza has not been described previously as one of the most frequent causes.

The author describes four cases of latent otitis in children whose ages ranged from 11 months to 8 years. In each case hearing appeared to be perfect, and there were no symptoms of otitis, but examination of the membrana tympani showed that there was otitis media, and paracentesis revealed the presence of pus, its evacuation being followed by speedy recovery. The author concludes that every case of prolonged fever, whether oscillating or remaining at a high level, without pulmonary or abdominal symptoms, should lead to an immediate examination of the ears, even when no mastoid tenderness, otorrhea, or deafness is present. Paracentesis confirms the diagnosis and gives almost immediate relief. The temperature falls quickly and, in general, the otitis is cured most rapidly when it has been recognized at the earliest moment. Latent otitis, when not detected, may persist for weeks and produce most serious symptoms. The majority of these patients suffered also from adenoids, and the author considers it most important that these should be removed in order to prevent a recurrence of otitis media, with the grave dangers of mastoiditis and meningitis.

Otitis Media in Infants. One hundred cases of acute otitis media in infants seen at the University of Iowa hospital have been studied by D. M. Lierle[6] and furnish the material for a rather extensive report. The cases

(5) Rev. Méd. de la Suisse Rom., Feb. 28, 1927.
(6) Ann. Otol., Rhin. & Laryng., September, 1927.

are divided into two general groups: acute and chronic. He offers the following series of observations:

1. Infections of the tympanum and mastoid are apparently secondary to infection in the nose and throat. A diagnosis of paranasal sinus disease was made in all but six cases of this series during the last two years. The prevalence of sinus disease is probably best explained by the variable climate. According to the report of the United States Weather Bureau, the precipitation in Iowa for May, 1926, was 4.64, and the mean average temperature was +54.6° with slight daily variations. One case of acute otitis media was seen during this month. The precipitation in January was 1.63, and the average mean temperature was +24.6°, while in February the precipitation was 1.55 and the average mean temperature was +32.0°. The number of cases of otitis media seen in infants in January was eight and in February eleven. It would appear, according to these figures, that the precipitation has very little to do with the incidence of otitis media, but that the low temperatures and the extreme changes from day to day play an important role. This is again shown, because during June, July and August, 1926, we saw only three cases in the three months, whereas in September and October, with the drop in temperature, six were observed.

2. Most of the infants come from the pediatric outpatient department. It is consequently impossible to determine the duration of the infection. Most of the cases were artificially fed. Only four were breast fed. The ages range from eighteen days to fifteen months, the mean age being five months. Two prematures were eighteen days old.

3. Ninety-two had bilateral involvement.

4. Spontaneous rupture of the drum membrane occurred in twelve cases. In eight pus was found in the external canal at the initial examination.

5. The mastoiditis may appear to be primary. Slight pathology of the drumhead, such as redness, lusterless-

ness without apparent bulging, was present in seven cases. Myringotomy usually revealed no pus or serum in the middle ear. However, on paracentesis of the posterior superior canal wall, which is usually sagging in these cases, pus was found in the mastoid antrum. It was not uncommon, in the presence of slight pathology of the drum membrane, to find a dry tympanum at the time, and within a few hours profuse serous or purulent discharge. It seems the best explanation offered is that, due to the infection, there is a marked swelling of the tissues of the tympanum. The cavity becomes obliterated, and in time the infection may extend into the mastoid antrum.

6. In the presence of hemolytic streptococcus, hemolytic staphylococcus albus and encapsulated streptococcus the infection is usually the most severe. Cultures of the mastoid antra are taken at the time of operation and from the canal following myringotomy. Those from the canal are of very little value; nearly 75 per cent were reported staphylococcus albus nonhemolytic, 2 per cent were hemolytic staphylococcus, 15 per cent were hemolytic streptococcus, 6 per cent nonhemolytic streptococcus and 2 per cent unidentified bacilli. Those from the mastoid antrum at the time of operation were very much different. Nonhemolytic straphylococcus albus was reported in 10 per cent, hemolytic staphylococcus in 10 per cent, pneumococcus in 5 per cent, hemolytic streptococcus in 45 per cent, nonhemolytic streptococcus in 28 per cent and encapsulated streptococcus in 2 per cent. The virulence of the infection proved greater where hemolytic streptococcus, pneumococcus and encapsulated streptococcus were found. One cannot always rely on the type of organisms as an index to the severity of the infection, because in several cultures, and clinically, the infection was of the most virulent type.

The usual clinical picture of acute otitis media is, as a rule, quite definite. The infant is critically ill. The onset is usually sudden. Marked dehydration may take

place in a very short period of time. There may have been food refusals for some time. The weight is stationary or there is a definite loss. A case seen at night may have apparently little dehydration, and the next day there may be a marked loss in weight with the skin loose and dry. Periods of syncopy which may prove fatal may appear more often in the subacute cases. The child appears to be in a fair condition. The attack is usually short. Marked paleness ensues, the lips are cyanotic and there is difficulty in breathing. There is usually a marked loss in weight over a short period of time. Four hundred grams in weight has been lost during twelve hours. The fever is often high, ranging between 103 and 105 degrees rectally. This is not constant, as several acute cases of this group had only a degree or two of temperature.

Diarrhea is practically always present. The stools vary from eight to twenty daily, and as a result the buttocks become excoriated. The stools are foul, green and slimy. Food refusals are very often recorded on the chart. The infant becomes nauseated and vomiting is common. The leucocyte count varies from 10,000 to 40,000 with a high percentage of polymorphonuclears. Jeans and Floyd describe an appearance of intoxication characterized by drowsiness or stupor and grayish pallor which come on simultaneously with, or following, the fever. Feeding is difficult because of loss of appetite.

The examination of the nose and throat in these acute cases is extremely interesting. A diagnosis of paranasal sinus disease was made in ninety-two cases. Pus was seen in the ethmoid regions. The nasopharynx was invariably reddened, and pus seen on the posterior pharyngeal wall. Although it was taken into consideration that the *x*-rays of the sinuses in an infant are of doubtful value, due to the difficulty in interpretation, the antra were often found blurred and infections of the antra were present upon aspiration. The adenoids

were often chronically, but rarely acutely, infected in the older infants.

The prognosis is dependent upon certain factors:

1. The duration of the infection. The earlier the treatment is instituted, the better the prognosis.

2. The presence of other systemic complications. The prognosis is grave in the presence of septicemia, pneumonia, etc. One case of this series who died was shown at autopsy to have a right lateral sinus thrombosis.

3. The virulence of the organism is a large factor in the recovery of the patient. At various times during the year the infections appear to be unusually severe, and many die in spite of all that one can do. Hemolytic and encapsulated streptococci are prevalent at these times.

Conclusions:

1. Otitis media in infants is not infrequent and may produce a syndrome of gastro-intestinal disturbances.

2. It is necessary that the otologist and pediatrist work together.

3. Acute otitis media in infants is rarely an otologic problem alone.

4. All of the cases in this series have shown some pathology of the drum membrane or sagging of the posterior superior canal wall.

5. Chronic mastoiditis may occur without apparent evidence of trouble in the middle ear.

6. Paranasal sinus disease may produce the same systemic disturbances as is found in acute otitis media, but to a less degree.

7. Paranasal sinus infection almost invariably coexists with otitis media in infants.

8. In almost every instance the treatment of the otitis media should be managed by the pediatrist.

[During the past year there has been an unusual number of latent mastoid sequelae following influenza. In several of these cases, swelling, tenderness, local pain and elevation of temperature were entirely absent, but the

transillumination and *x*-ray showed involvement and operation revealed extensive necrosis.—Ed.]

Scarlet Fever Otitis: A Report of Sixty-Six Cases. A table is presented by A. B. Lefler[7] showing that scarlet fever is the cause of chronic suppurative otitis media in from 4 to 15 per cent of all cases and in 10 per cent of all deafmutism. In the series of 66 cases, eleven are reported as not progressing as favorably as they should. In all of these cases the criticism is made that paracentesis was delayed. Lefler believes that:

Early paracentesis, with strict asepsis following, as well as at time of paracentesis, lessens the seriousness of ear complication.

Diligent attention by the ear staff to their problem in scarlet fever increases the confidence of the health officer and the pediatrician. Their influence is vital: the health officer in restraining those with discharging ears from going home to spread infection; the pediatrician in choosing the time when the patient is best fitted for mastoid operation.

Consent of parents to a mastoid operation as an emergency procedure is easily gained; but consent to an operation to cure a discharging ear when the patient has recovered from a critical illness is difficult. Anticipation of this period by the ear staff develops the interest of the parent concerning the child's ears and hearing. Consent for operation is then given when needed.

Reporting these cases to the school principals or teachers should be as much a personal matter as is possible. They should be advised that the child be sent home when he has a cold; that he be excused from attendance in severe weather; that any evidence of recurrent otitis or lessening of hearing receive prompt attention.

Segregation of scarlet fever patients in the modern contagious hospital, with better attention to the ear

(7) Ann. Otol., Rhin. & Laryng., June, 1927.

than we have reported, will definitely reduce the final ear pathology.

Diphtheria Infection of the Middle Ear and Mastoid. Two cases of diphtheritic infection of the mastoid are reported by J. B. Costen[8]. The purpose of the report is to call attention to cases in which the patients carried virulent diphtheria organisms in the middle ear and mastoid without clinical signs referable to the ear, and showed obscure but persistent general reactions.

In both of the cases reported, the complete solution of the infantile mastoid structure and replacement with organized pyogenic membrane indicated an infection of long duration. In one case the clinical course of the child for a year previous to the diagnosis of diphtheria of the mastoid, and the coincidence of the mother's pharyngeal diphtheria with the beginning of the child's vague troubles, is strong evidence that the patient had carried the diphtheria as a primary infection in the middle ear space without any signs in the nose or pharynx or symptoms referable to the ear.

It is to be noted that the infection in this patient with an active virulent organism, which it is reasonable to assume was present from the onset and not recognized, did not overwhelm the patient, and he was not extremely toxic at any time. The only thing suggestive of diphtheria was the failure of the wound to close, and profuse wound secretion.

Costen draws the following conclusions:

1. The symptomatology of diphtheria of the middle ear is so atypical that it probably accounts for the conviction that it is a rare occurrence. A contributory fact is that although almost every surgeon sends out a swab of the wound for culture at operation, it is not grown on special media unless requested.

2. The extent of destruction in the middle ear and mastoid is much greater than the severity of symptoms would indicate.

(8) Arch. Otolaryng, Februray, 1927.

3. The classification of the strain of Klebs-Loffler organism as to virulence depends on the biologic test of guinea-pig inoculation.

Chronic Otitis Media in the Tuberculous. Of one hundred-forty-five patients examined by Francis J. Lussmann and Raphael A. Bendove[9] twenty-three or about 15 per cent were found to suffer from chronic suppurative otitis media. Of these cases, approximately 80 per cent showed a unilateral involvement, and about 20 per cent presented a bilateral otorrhea. Smears from only three cases revealed acid-fast bacilli; these cases pursued a rather severe clinical course, and the sputum showed innumerable tubercle bacilli. As the severity of the otitis media subsided gradually under heliotherapy, the smears failed to reveal tubercle bacilli.

The impression was gained, therefore, that, first, laboratory tests for determining the acid-fast character of the otorrhea are of value only when they are made during an acute exacerbation; and second, in cases of open pulmonary tuberculosis, the expectorated material might incidently be brought to the middle ear through the eustachian tube; but such material does not necessarily bring about a recrudescence of the otitis media and does not influence its clinical course. They conclude that a clinical diagnosis of chronic tuberculous otitis media can best be made from the insidious and usually painless onset, the profuse intermittent creamy discharge, at times fetid and bloody in character, the rapid impairment of hearing and, frequently, a bilateral involvement.

They have tried many of the therapeutics suggested, such as zinc ionization, iodin, anilin dyes, mercurochrome-220 soluble, vaccine, tuberculin and other methods, but none of these methods are as efficacious as ultraviolet light therapy.

From the study of this series of patients with chronic otitis media treated with local ultraviolet ray, they

(9) Arch. Otolaryng., August, 1927.

conclude that the beneficial effect is derived just as much from the solar rays as from the quartz and mercury vapor lamp, but the modes of application of these two methods differ somewhat, due to the different concentration in the rays. The quartz and vapor mercury lamp is rich in ultraviolet rays, which constitute approximately 25 per cent of the entire radiation, whereas the ultraviolet light of the solar rays amounts to only about 1 per cent, and must be much more concentrated when used therapeutically.

In applying local heliotherapy to the diseased part of the middle ear, we used a concave shaped reflector and an ear mirror made of aluminum or nickel, held in the same position as for an ordinary examination of the ear; the reflected sunlight insures a greater concentration of the ultraviolet rays. When the quartz lamp was used, the rays were passed directly through the ear mirror, since a reflector was not necessary to concentrate the already rich ultraviolet rays of the quartz lamp.

The lesion was exposed to the ultraviolet rays daily, for one minute in the beginning, the time being increased gradually to about thirty minutes in a period of from one to five months. The following changes were observed in most of the cases: the creamy discharge changed its color, became scanty and less fetid, and ceased eventually; the mucous membrane, which was ulcerated, congested and uneven, turned pale red, dry and smooth; the thin margin of the perforation developed reactive granulation tissue, with a tendency to close the perforation, and in five cases the drum closed up completely. However, a complete return to health was rather the exception than the rule.

In seven cases, hearing improved remarkably; the smallest increase in hearing was about 1 meter, and the highest 3 meters, averaging about 1.8 meters for the whispered voice.

In six cases the courses were not changed by the treat-

ment; these patients gave a history of having had "ear trouble" for about ten years. In such cases, the diseased mucous membrane apparently had lost all its ability to give rise to granulation tissue, and even the local stimulation by ultraviolet ray could not bring about the formation of new tissue.

The following bacteriologic changes in the discharge were noticed during the course of treatment. In those cases in which acid-fast bacilli were found, the reactions became negative within one month after treatment was begun and have remained so. The diplococci and the bacilli were first to disappear from all the discharges; only a pure strain of staphylococcus albus persisted for a long time. In many cases the discharge was sterile after two or three applications of ultraviolet treatment.

A word of caution is necessary, for too intense radiation might do more harm than good. Two patients, subjected early to a prolonged exposure, showed a marked reactivation of the chronic otitis media, and the treatment had to be abandoned. Intense radiation causes a melting away of the diseased tissues, whereas mild slow radiation tends to increase granulation, fibrosis and epithelization. This holds true of artificial light treatment, as well as of direct heliotherapy.

Tuberculosis of the Middle Ear, with Especial Reference to Heliotherapy. The effect of heliotherapy in the treatment of tuberculous otitis media is discussed and recommended by S. J. Chapman[1].

In considering the general aspects of tuberculosis he states that usually there is no way of determining definitely the route of infection. The form of nourishment in children apparently plays an important role in some localities. In McCart's series 75 per cent of the children, whose nourishment was noted, were fed on unboiled cow's milk, and he feels that the infection in children is usually milkborne, the bovine type being present.

(1) Ann. Otol., Rhin. & Laryng., September, 1927.

The author's cases in children have been among those who have been infected by tuberculous mothers.

As a rule tuberculous otitis media, in adults, begins insidiously, and the first evidence of its presence may be aural discharge. Adults are very apt to have some symptom which makes them think there is something wrong with the ear, but this is often so slight that they fail to mention it until a discharge is noted. Pain is a rare symptom and is seldom, if ever, present unless we are dealing with a mixed infection. Some writers lay a great deal of stress on multiple perforations, but this has been the exception in my cases rather than the rule. Some of these patients have not been seen at the onset and have had a fairly large perforation at the time of first examination. It is possible that these patients had multiple perforations which coalesced. The inflammation of the drum is usually low grade throughout, with very little redness, and the cone of light may occasionally be seen after spontaneous perforation. Usually granulations are to be seen in the middle ear a few weeks after the onset. These have a light pink color in contrast to the more definitely red color seen in the ordinary types of infection. At the onset the discharge is seropurulent and is apt to be scant. Later this becomes somewhat thicker and more frankly purulent. Mastoid tenderness is rare in adults, but may occur in the presence of a mixed infection. The course is apt to be mild and chronic. We see the more acute type in children, and in these patients there is frequently mastoid involvement, associated with a cervical adenitis. Facial paralysis is a fairly common complication. In McCart's series it was present in 17 of the 46 children, but in none of the adults. Spencer states that it occurs in approximately 50 per cent of the cases. Labyrinthitis and meningitis occur, but less frequently.

The diagnosis is made from the characteristic onset, the middle ear findings, the chronicity, the presence of an adjacent or remote tuberculous focus, the finding of

bacilli in the aural discharge, by smear or guinea-pig inoculation, and by pathologic examination or examination of excised tissue. Smears of the pus very rarely show tubercle bacilli. They are more often found in scrapings from the middle ear or mastoid. The findings of giant cells should not be relied on, as they can be found in simple inflammatory tissue. Guinea-pig inoculation is very reliable, but at times the pig dies from the mixed infection.

In addition to other forms of treatment the author finds heliotherapy of definite value and is worthy of a thorough trial in the chronic cases, except when the pulmonary condition is quite active with a moderate elevation of temperature. In such instances the lung condition is of prime importance and should receive first consideration. It is not customary to use local or general heliotherapy on febrile cases. Complete rest in bed will lower the temperature in a comparatively short time in favorable cases. The patient is then in condition to receive more benefit from heliotherapy with less danger to pulmonary lesion.

The treatment consists of reflected sunlight by means of a modified solar laryngoscope. This instrument was originally devised for the treatment of laryngeal tuberculosis and is now in general use for that purpose. Many others have used direct sunlight and recommend it, but the author has seen no reference in the literature to the use of reflected sunlight. There are several advantages to the latter, along with one or two disadvantages which may be mentioned. With a little practice the patient can learn to see the tympanic membrane quite well and can determine whether the sun's rays are reaching the middle ear or are simply shining on the canal wall. By looking in the ear daily he can discover crusting which may be preventing free drainage. Also, he takes a keener and more intelligent interest in his condition because he can see it, watch its progress, and feel that he is doing something definite

toward effecting a cure. One disadvantage is that the mirrors do not reflect all the sun's rays. This does not appear to be a serious objection, as those reflected are effective in tuberculous laryngitis. The cost of the instrument is at times a consideration.

The patient is directed to take a half minute exposure once or twice daily and increase a half minute a day up to fifteen or twenty minutes. Cases have been noted that were almost dry in which heliotherapy had to be discontinued temporarily for one reason or another during a period of ten days or two weeks. Frequently the discharge would increase markedly during this time and decrease a few days after resumption of sunlight. With some patients, progressing favorably, the middle ear became dry without healing of the perforation, and in others there was a complete healing with closure of the perforation.

Chronic Middle Ear Deafness. G. S. Williamson[2] reports an analysis of data acquired from a study of 51 out-patients at the Central London Throat, Nose, and Ear Hospital suffering from chronic deafness of the type commonly known as "chronic middle-ear catarrh"; only idiopathic deafness was included. The patients were subjected to a thorough examination of the cardiac, respiratory, digestive, urinary, neuro-muscular, genital, and hemopoietic systems. Out of the 51 cases 7 were found to present signs of established disease—namely, mitral disease of the heart (3 cases), Graves' disease (3 cases), tuberculosis (1 case). The tests on the remaining 44 showed with one exception (the cardio-respiratory balance) the patients to be within the normal of average people at their age limits. All the patients showed a decided tendency to tachycardia, and had easily disturbed cardio-respiratory balance.

The author's conclusion from these cases was that the history of the deafness began at puberty or earlier, and he suggests that the marked dullness and apathy of

(2) Brit. M. J., June 18 1927.

many of these persons are due to their deafness, or at least their low auditory acuity while at school. Another positive fact noted was that in each of the cases the patient had a peculiar aspect depending upon the size and shape of the nose (pinchbeck). The 51 cases included only 5 males, but the author does not regard this as representing any real sex incidence of the complaint. The male, being under greater compulsion to adapt himself, probably ignores his deafness, and, having a larger choice of occupation, selects employment not dependent on auditory acuity.

In the discussion G. J. Jenkins stated that he himself was unable to recognize, pathologically or clinically, the condition known as "progressive middle-ear deafness," sometimes described as "chronic middle-ear deafness," or even termed "dry middle-ear catarrh." The terminology, in his opinion, was wrong and misleading. All are familiar with the textbook description of the disease under this name, with the detailed accounts of the active local treatment and general management of the patient. The pathology was in most books purely speculative. The symptoms and signs were usually roughly and indefinitely indicated, and so far as they went, were the same as an imperfectly described otosclerosis syndrome. He believed that if a complete modern examination had been made in these cases on which this terminology was founded, the diagnosis would have been one of otosclerosis. In his opinion, pure middle-ear changes, including fixation of the stapes, would give only pure obstruction signs, and if any symptoms such as internal-ear deafness or those specially associated with otosclerosis were present the labyrinth should then be regarded as affected. He had not known progressive middle-ear deafness, in the sense implied in the title of this discussion, that could be attributed to middle-ear changes only.

A medical man who had been a patient, introduced by N. Barnett, also spoke. He said that he had noticed deafness as a student when using the stethoscope, and it

became worse. Four years ago an operation on turbinates was done, with improvement for a time. In September, 1925, the left ear became completely deaf, and he was advised to give up practice, as nothing could be done for his hearing. An examination in December, 1925, showed a marked deflection of the nasal septum with an adhesive remnant of the right middle turbinate. There were buried septic tonsils and retracted and inflamed tympanic membranes. Submucous resection of cartilage and bone of nasal septum, which was found to be fractured, was done, diseased and adherent turbinates removed, and ultraviolet rays, general and localized for throat were administered. Subsequently oto-massage with ionization over mastoid and vaporization through the eustachian catheter and the tympanum with hot iodin, camphor, and carbolic vapor was carried out. On testing in February and March, 1926, there was improvement for all tests, and hearing for conversation and whispered voice was practically normal. Since then there had been further improvement, and he was now able to carry out all professional examinations with ease. He added that in the country village where he practiced there were thirty people who were deaf, and of these he had treated eighteen, on the line of treatment he had himself undergone, with success in every case.

[It is the consensus of opinion that genuine otosclerosis (rarifying osteitis of the labyrinthine capsule) never has been, and probably never will be, materially benefited by treatment. From the marked improvement resulting from treatment of cases of so-called catarrhal deafness it is apparent that there are two distinct pathologic processes. From the changes which take place in the appearance of the membrane tympani and the handle of the malleus as a result of treatment, it is apparent also, that we are still in need of some term, which can be applied to the pathology resulting from eustachian obstruction and to vasomotor changes in the middle ear.—Ed.]

Chronic Otitis Media in 1911-1921, at the University Ear Clinic in Frankfurt on the Main. Stern[3] states that during the years 1911 to 1921, 5,380 patients suffering from chronic middle ear suppuration (71.3 per cent) were observed, compared with 2,160 patients (28.7 per cent) who suffered from acute middle ear suppuration. In consequence of the war, the number of patients was larger in the years from 1914 to 1919 on account of such factors as injuries to the ear and undernourishment. There were three and one-half times as many male as female patients. Most cases occurred during the second and third decades, while in acute otitis media most cases occur during childhood. With the exception of infectious diseases, in 3.7 per cent of cases, the cause of chronic otitis media is difficult to establish. It must be assumed that the disease will be chronic from the beginning, although it must be admitted that in the development of mesotympanal disease, changes in the nasopharynx play an important rôle. In 0.65 per cent, tuberculosis could be shown; in 59.9 per cent, disease of the nasopharynx, of the nose and of the nasal accessory cavities were found. Chronic otitis media is classified as mesotympanal in 56 and epitympanal in 27.8 per cent of cases. Both forms were present in 7.8 per cent. In 8.4 per cent, the localization of the perforation was not mentioned.

The symptoms were discharge, then headache and pain in the ear, followed by difficulty in hearing. In 54 per cent of the patients sound conduction was impaired and in 6.7 per cent sound perception. Both were impaired in 36.1 per cent. Vestibular hypoexcitability was present in 19.6 per cent, vestibular hyperexcitability in 6.9 per cent. Three and a half per cent reacted differently calorically and after turning.

With seven exceptions, leading to a mastoid operation, the mesotympanal middle ear suppuration was treated conservatively. Of the epitympanal cases, eighty-seven

(3) Ztschr. f. Hals-, Nasen- u. Ohrench., Sept. 22, 1926.

patients (18.1 per cent) were treated conservatively: 3,913 (81.9 per cent) were treated surgically—of these, 75.1 per cent underwent radical operations and 24.9 per cent attico-antrotomies. Forty-seven mesotympanal and fifty-one epitympanal suppurations were associated with mastoiditis, which in seven mesotympanal and in all epitympanal cases led to an operation. Thirty-one times a facial paresis was noticed, twenty-one times before and ten times after the operation. In forty patients an extradural abscess was found during the operation. Seventy-five per cent of these were cured. In sixty-one patients, a labyrinthitis developed. Of these thirty-two had a fistula of the semicircular canal, and of these eighteen had a symptom of fistula. A complete labyrinth operation was performed on eighteen patients, a partial operation on one patient. Six (31.6 per cent) died; thirteen (68.4 per cent) were cured. Of those who had not been operated on, ten (23.8 per cent) died; all others (72.2 per cent) were cured.

In six patients a sinus thrombosis was found; five of these patients (83.3 per cent) died of further ear complications. Seven abscesses of the brain were observed, four of the cerebrum and three of the cerebellum. Three patients suffering from abscesses of the brain died. In seven patients, a meningitis serosa was present. These patients recovered.

In sixteen patients a suppurative meningitis was found. Six of these patients recovered. In all, twenty-three patients died, seventeen on account of an ear disease.

Mastoiditis and Intracranial Complications

The Clinical Value of Roentgenography of the Temporal Bone. P. L. Magnien[4] states that from the point of view of roentgen examination the temporal bone presents three parts, the petrous pyramid, the mastoid,

(4) Arch. internat. de laryngol., 1926, xxxii.

and the squamous portion. Each of these parts requires a different roentgen technic. Ferreri's study of the embryo shows that a center of ossification for the petrous pyramid develops about the third month, and that after the fourth month the chief parts of the internal ear can be seen. Pneumatization of the mastoid does not appear in the child before the eighth year of age.

The mastoid and the base of the petrous pyramid may be studied together. They may be studied with an oblique sagittal incidence, an oblique profile incidence, and a vertex-chin or chin-vertex incidence. The oblique profile incidence is used for the squamous portion and the positions of Stenwers and Hirtz for the tip of the petrous portion. Roentgen examination of the squamous portion reveals a special form of mastoiditis, called temporal mastoiditis, which is particularly severe on account of its extent and complications, and shows the necessary extent of the mastoidectomy indicated in such cases.

Roentgen study of the mastoid seems to confirm the theory of Reverchon and Worms that a solid mastoid is always the result of an old infection. A normal mastoid is either pneumatic or diploic. In the diploic form the solid partitions between the cells are broader than in the pneumatic form but the cells are still present. A comparative study of the normal and diseased mastoid in the same subject shows that the normal mastoid is pneumatic.

In acute otitis and mastoiditis there are three stages of simple inflammation. In the first stage, there is a veil of greater or less density covering the mastoid cells, and in the second, decalcification with decreased density of bone. In the third, there is a haziness of the whole region and the structure of the mastoid has disappeared entirely. In chronic otitis or mastoiditis the normal mastoid is still alveolar in structure while the diseased side shows eburnation and atrophy. A comparison should be made of plates with a different incidence to determine

the exact topography of the lesions. This examination is of great value in showing latent chronic mastoiditis.

Roentgen examination of the petrous pyramid gives valuable information not only in cases of traumatism but also in those of cerebellopontine tumors and tumors of the auditory nerve.

The fracture lines that can be shown most readily are the perpendicular and oblique ones. For parallel fractures the position of Hirtz or of Deutsch and Mayer should be used. In cases of otolabyrinthine lesions from traumatism a negative roentgen examination shows that there is no fracture, a finding of importance from the medico-legal point of view in industrial accidents.

Cases of cerebellopontine tumors show, in addition to dilatation of the internal auditory foramen, porosity of the bone, rarefaction of bone tissue within the petrous pyramid, atypical pneumatization of the tip, and haziness of the periphery of the petrous pyramid.

The lateral sinus is normally invisible. In a pathological mastoid it can be seen as a clear tract. The pathogenic lesion found in Gradenigo's syndrome is osteitis of the tip of the petrous pyramid; it is shown by clear spots at the tip or by amputation of the tip.

The eustachian tube has been studied experimentally by Portmann, who determined the direction of the tube.

Roentgenography is of value also in localizing projectiles and showing the best surgical route for their removal.

The evolution of a cavity after curettage may be followed up by the insufflation of subnitrate of bismuth and lipiodol. Stereoroentgenography is particularly useful in the interpretation of the findings.

Systemic Otogenous Infections. The type of mastoidal disease which produces a systemic infection of bacterial nature is that characterized by the primary involvement of the small vessels in the mastoid process. It is caused by the entrance of a hemolytic organism, usually the streptococcus hemolyticus, into the lumina of the mu-

cosal vessels. This immediately results in a multiplicity of infected thrombi. The infection in this instance is located in the circulating venous blood and not in the cell spaces. Consequently the cells are not subjected to pressure necrosis and their walls are not destroyed by the disease. The disease here is manifested by an intense engorgement of the cell lining and by a hemorrhagic exudate into the cell spaces. It is from these phenomena that the condition derives its name of the hemorrhagic type of acute mastoiditis. Roentgenography does not aid one in diagnosing this type of mastoiditis. The cells are never destroyed and therefore appear intact, on an *x*-ray plate, at any time during the course of the disease. In the coalescent mastoiditis gradual destruction of the cells can be seen.

After the diagnosis of this type of mastoidal disease has been made, S. J. Kopetzky[5] believes the hemoglobin and red cells should be estimated daily. Operation is indicated as soon as the lesion is recognized. Early operation will succeed in eradicating all the infected thrombi in the mastoid venules and thus prevent further extension of the infection into the sinus. Where the simple mastoidectomy has been sufficient to eradicate the disease, the sepsis stops promptly and the reduction of hemoglobin and red cells ceases. On the other hand, the failure of the surgery to remove all the thrombi is marked by a continuation of the sepsis and by a progressive diminution in the hemoglobin and the red cells. The latter finding furnishes the most valuable guide as to the extent of the thrombosis. After simple mastoidectomy, a continuation of the reduction speaks for involvement of the larger venous channels, and surgery on the sinus and jugular vein is then indicated.

In the general treatment of otitic systemic infections, the author has obtained the best results from the following procedure. After the blood vessel surgery has been

(5) New York State J. Med., Oct. 15, 1926.

performed, the daily blood examinations are continued. Where the hemoglobin percentage continues to fall despite the sinus surgery and reaches a point below half of normal, he employs transfusion of whole blood by the direct method. The amount varies with the individual patient.

The author has had very little success with any of the serums, vaccines or dye products in his cases of otitic sepsis. Transfusion, intelligently used, as a supportive measure, coupled with the outdoor treatment and typhoid diet, furnishes the best method of treating these cases after operation to remove the septic focus in the temporal bone.

The Diseased Mastoid as a Source of Focal Infection. In the past few years H. Dintenfass[6] has been impressed by the fact that several of his patients who were suffering from some systemic disturbance as well as a diseased mastoid experienced a complete recovery of both conditions shortly after the mastoid was drained. This demonstrated the possibility of the mastoid being a source of focal infection.

Focal infection has been defined as being a systemic or local disease due to infectious micro-organisms carried into the blood or lymph stream from a focus of infection and it has been customary to regard the teeth, tonsils, the sinuses of the face, the appendix, the gallbladder and the prostate as the probable sources. The mastoid, however, has never been seriously considered by the practitioner of medicine as being an important factor in the remote pathological changes which take form in the various disease conditions met with today.

The term focal infection embraces the exposure of the susceptible patient to pathogenic organisms which possess varying degrees of virulence; such as the Streptococcus hemolyticus, viridans and mucosus, Micrococcus catarrhalis, Bacillus mucosus capsulatus, Bacillus pyocyaneus, Staphylococcus aureus and albus.

(6) M. J. and Record, May 4, 1927.

These pathogenic agents gain access to the mastoid after the involvement of the middle ear, although sometimes mastoid infections occur which are apparently primary in origin. Otorrhea therefore may or may not be present, depending entirely upon the walling off of the aditus ad antrum.

The dissemination of the organisms may be hematogenous or lymphogenous. In the first the micro-organisms of the infected mastoid reach the blood stream through the surrounding capillaries or through the lateral sinus and its venous tributaries, the bacteria, like emboli, being carried in the blood stream to the smallest blood vessels in the body. If the invading micro-organisms are small in number and of low virulence the defenses of the body overcome any harmful result of their presence. However, if they are virulent and in sufficient number they may excite characteristic reactions in the tissues.

In the lymphogenous type the bacteria pass from the mastoid through the lymph channels to the lymph nodes. Kretz has shown that this lymph node invasion may serve as a source of protection against further systemic infection by holding the infectious micro-organisms in a tissue environment which renders them latent and for a time harmless to the patient.

The source of infection may be either an acute or a chronic mastoid condition. An acute focus is of recent origin and usually, although not necessarily, is manifested by local inflammation in the mastoid area. A chronic focus is of long duration and may or may not be symptomless.

It is the symptomless type of either acute or chronic variety which offers the greatest problem to the practitioner of medicine in diagnosing the etiology of obscure and hidden maladies.

Three illustrative cases are reported by the author and from the experience of these he comes to the following conclusion:

1. In making use of the increased facilities for diagnosis, a wide distribution of diseases which can be traced to mastoid origin will be demonstrated. Roentgenology is one of the safest diagnostic guides in disclosing the presence of mastoid disease.

2. In cases of mastoid involvement where the inflammatory manifestations have subsided, recovery should not always be considered complete since there still may be present a collection of pus which may produce no local symptoms and yet be acting as a source of focal infection. This is well shown in the author's first case.

3. The character of bone present explains why focal infection in this region is so often overlooked. In the hard, compact acellular type there is very little tenderness or other local symptoms. In the pneumatic variety of bone where the cortex is not so thick and the pus is not so deeply located there is apt to be more local manifestations and less likelihood of their remaining unrecognized. In each of the three cases described the compact type of bone was found.

Indications for and Technic of the Early Operation in Acute Mastoiditis. According to H. Neumann[7] the time for a mastoid operation is before there are any complications and when the process in the mastoid is developed to a degree that spontaneous resolution is improbable. The surgeon should be able to decide that the operative intervention is less dangerous than the disease itself. Indications may be absolute or relative. Probability of intracranial complication may be considered an absolute indication. Relative indications are those whose importance depends on the duration of the disease, such as pain, tenderness, profuse secretion, sinking of the canal wall, papilliform elevations, which bespeak anatomicopathologic conditions early in the course, different from those seen when these symptoms develop later. The age of the patient, his constitution and the etiologic factors influence the changes in the mastoid as

(7) Ztschr. f. Hals-, Naser- u. Ohrenh., Oct. 6, 1926.

much as does its anatomic construction. Clinical experience helps in judging virulence and resistance. For instance, the different course of inflammation of the ear in scarlet fever and measles as compared with the course of inflammation resulting from ordinary colds, and the variations in different epidemics are known.

In the majority of cases the indications are not urgent, and on the basis of clinical experience it is customary not to undertake an operation within the first ten days or two weeks of the onset of the otitis media. A delay of a few days allows the infective process to quiet down and become walled off, making the operation technically easier. On the other hand, there is increasing risk of complications. The author quotes statistics to show that, in general, complications increase with the duration of the otitis. In 104 cases in Neumann's clinic, sixteen patients were operated on early, that is, before they had had the disease two weeks. The author states that, with the ordinary technic used in operation on the mastoid, experience has shown that early operation may fail to control the spread of infection and may lead to complications or at least to a second operation. At best, the healing process is longer, and some authors state that persistent fistula is more frequent.

The author states that these objections are overcome by the technic followed in his clinic, where the operation is carried out according to a definite system. After opening into the antrum, the root of the zygoma is reamed out until compact bone is reached; the retrofacial group of cells (if not presenting) are sought out and opened as widely as possible; then the tip cells, the retrosinus and peribulbar cells are removed down to the sinus plate. Then the petrosal angle is carefully sought out and cleaned out down to the hard inner plate. The cells at the tegmen are cleaned out, and here it is to be remembered that there may be a double deck of bone with cells between. These cells are exenterated, even when they are empty, and appear normal. Of course, this leaves a

large operative defect, and in forty-seven of the author's cases the dura or sinuses were uncovered, but without any ill effect. Therefore he believes that it is better to have this exposure than to leave doubtful bone. Since this technic has been followed, there have been no secondary operations and no complications.

[There seems to be a direct relation between the thoroughness of the operation and recurrences following operation for acute mastoiditis. If the technic of Neumann is followed and the wound drained, rather than packed, there should be no recurrence and little deformity.—Ed.]

The Incidence of Otitis in 15,000 Acute Exanthemata, with a Report of the Method of Handling Scarlet Fever Otitis Mastoiditis at the Philadelphia Hospital for Contagious Diseases. F. V. Gowen[8] states that myringotomy is repeated as often as indicated. Suction is applied daily to the eustachian tube by means of a catheter and pump. By this method antiseptic solutions can be placed in the auditory canal and sucked through a perforated drum into the tympanum and out through the eustachian tube.

Adenoids are removed routinely as soon as this procedure will not adversely influence the course of the initial disease, which is about the third week. The tonsils are not removed routinely, but are removed when showing indications for removal.

Rapid destruction of the drum was not seen in all these hundreds of cases. The authors also believe that if the mastoid is opened as soon as it is tender and infiltrated, widespread destruction of bone will not be found.

The mastoid operations were done in the latter six months of the years 1922, 1923, 1924, and part of the latter six months of 1925. The total number of scarlet fever patients handled was 3,028. Of these, 278 devel-

(8) Laryngoscope, November, 1926.

oped otitis, and of these 23 were operated upon for mastoiditis.

The total number of consecutive mastoid operations were 23; cures, 21; sinus thrombosis, not any; facial palsies, 0; brain abscess, 0; reoperations, 0; deaths, 2. The total number of unoperated surgical mastoiditis, were 0. One death was due to pneumonia fourteen days after the operation. This child also had the rickets. The other was due to streptococci meningitis.

As mentioned in an earlier paper on ear complications, the author found that out of a total of 10,086 scarlet fever patients there were 1,063 who developed otitis, and of these, 210 a definite surgical mastoiditis. The percentage of noted cases is 10 per cent otitis, and 2 per cent mastoiditis.

Now, the author gives additional information—

Of 839 measles patients, 93 developed otitis and of these, 6 had surgical mastoiditis; about 10 per cent otitis, and .8 per cent mastoiditis.

Of 172 pertussis patients, 9 had otitis and none mastoiditis; about 4 per cent otitis.

Of 100 chickenpox patients, none had otitis and none had mastoiditis;

Of 188 smallpox patients, 4 had otitis and none mastoiditis. All the 4 were children. The total number of children having smallpox was 45.

When the original disease became complicated by another acute exanthem, the percentage of otitis became greatly increased.

A Double Pneumatic Mastoid. According to a definition of inflammation the case that G. E. Adkins[9] reports might be classed as a mastoiditis, but according to the common way of thinking of inflammation (always attended by an infection) it might be classed as a mastoidalgia, for certainly the cardinal symptoms of inflammation (calor, rubor, dolor, tumor and functio-perver-

(9) New Orleans, M. and S. J., Feb. 12, 1927.

tis) were all present in the case, but minus the infection.

E. McD., age 11 years, was brought to the author for a swollen and painful right ear, with a history of frequent attacks accompanied by swelling and tenderness over the mastoid portion.

There was no history of ear ache and no discharge. The external markings were those of a typical mas toiditis, swollen, very tender to direct pressure over the mastoid bone with slight redness.

There was no tenderness of the auricle, and inspection of the canal and membrane-tympani showed an uninflamed canal and a normal drum head. The author agreed with the family that the case presented marked signs of an acute mastoid, but that one could not call it such or operate without some signs of a middle ear involvement. They immediately stated that they had been told just this by another physician on two occasions.

With the application of ice cap and moderate purgation—the condition subsided greatly for a few weeks—only to repeat the cycle, when the ice cap was prescribed again. The condition slowly subsided again to return a few weeks later.

At the third visit the author suggested opening the mastoid, and the mastoid was opened.

On unroofing the mastoid only large clean cells were found. The antrum was clean, and with slight pressure a soft probe was passed into the middle ear. The mastoid was closed without drainage, because there was no infection.

Feeling that he had done no good, and the child being in good condition, the writer decided to remove the tonsils and adenoids. This was done and a rapid recovery followed, the patient leaving the hospital on the third day. The patient has not had a recurrence of the trouble on this side.

About two years later the patient was brought back

with the same condition on the left side. Again the author could not be convinced of the necessity of an operation, and let them return home. A few days later he was called by the physician and told that the child was in great pain.

The child was sent to the hospital and the left mastoid opened under the same conditions for which the right was opened just two years before. The findings were the same and the results equally as satisfactory, from the standpoint of recovery and complete relief of the condition.

A Mastoid Suction-Wiper. M. J. Mandelbaum[1] describes this instrument (Fig. 18) which he has found very useful. The author feels that it is of special bene-



Fig. 18.—Mastoid suction-wiper attached to index finger of right hand by means of spring-clip circular band (D). It may be worn on the middle finger. Note that index finger and thumb are free to grasp other instruments.

fit in those cases where considerable free pus wells up into the wound. The suction-wiper also catches loose granulations and minute bone particles. In practise both the operator and the first assistant carry the device as indicated in the figure.

The After-Treatment and Results of the Simple and Radical Mastoid Operations. From his experience G. J. Jenkins[2] believes that even in selected cases, drainage from the lower part of the mastoid wound—following the

(1) Amer. J. Surg., January, 1927.
(2) Brit. M. J., Dec. 18, 1926.

Schwartze operation—is most effective, and the healing is as rapid and is more under control; moreover, the dressing of the wound is less painful. The advocates of meatal drainage allow themselves to be biased too much by the pleasant appearance of a healed posterior incision, and are not sufficiently influenced by the sometimes unpleasant effects of meatal drainage.

The author discusses the variety of treatments of the wound by drainage through the mastoid incision. The problem will vary with the conditions. At one extreme there is a small smooth-walled cavity, of the dense mastoid, and at the other the large irregular cavity with tracks in various directions, and rough irregular bony walls. Sometimes the cavity is necessarily deep even at the edges, and at other times it is shallow. No two cavities are alike, and the appropriate treatment for each type must be considered. The author does not think hard and fast rules can be drawn up for the adoption of any particular method; the operator must be influenced by the conditions present, and, apart from the extreme variations mentioned, there must be a difference of opinion in certain cases. The form of the cavity is not the only factor, as most operators would take into account the acuteness of the infection and the character of the pus, and also the general condition of the patient.

The author describes his usual practice. He syringes out all wounds, first with hydrogen peroxide (10 vols.) to remove finer particles of bone or tissue which may have escaped notice, and subsequently with some bland sterile lotion; all the walls are then lightly smeared over with sterile fine iodoform prepared as follows: iodoform in fine powder is soaked in absolute alcohol; the excess of alcohol is run off and the iodoform used as a paste. When there is a small well defined cavity, such as a simple gutter in the anterior part of the mastoid, it is the writer's custom to stitch up the upper part of the incision, and to drain from the lower part of the wound. Two-inch ribbon gauze impregnated with iodoform is

loosely packed in the part of the cavity below the antrum; there is a certain amount of room for the blood clot to form in contact with the walls of the cavity. The gauze is there merely to maintain an exit for septic exudate. At the subsequent dressing, about the third day, a similar gauze dressing, perhaps a little smaller, is placed in the wound, and fresh clot usually forms which sometimes organizes very quickly. It is often advisable, even for such a light dressing as this, to administer gas. Two or three rubber tubes in the place of the ribbon gauze make an equally satisfactory drainage system. The process of healing is commonly uneventful, and the resulting scar is not in any way objectionable.

When the wound is very large it is the author's custom in most cases to leave the whole of the incision open and to pack lightly all parts of the wound with iodoform gauze. Such a large packing necessitates gas anesthesia for the first dressing on the third or fourth day.

[It should not be forgotten that a considerable percentage of patients seem to possess an idiosyncrasy for iodoform and that in most cases the wound will get along as well or better by the use of plain gauze.—Ed.]

After-Treatment and Results of Simple and Radical Mastoid Operations. In regard to the technic of the meatal plastic, J. S. Fraser[3] favors Körner's method. He also advocates the primary skin graft. The modified operation is rather less likely than the radical to yield a dry ear.

Apart from inefficient operation the writer enumerates the following causes of failure:

(1) Failure to close the Eustachian tube and to get rid of the tubal air cells. Many of these cases occur in children; they are really cases of tubo-tympanic catarrh or suppuration, and are not suited for the radical mastoid operation. In such cases one should treat the nose and nasopharynx, try vaccine therapy, syringe out the

(3) Brit. M. J., Dec. 18, 1926.

tube either through the Eustachian catheter or from the external meatus by means of a bulbous-ended syringe, followed by inflation and injection of silver nitrate, argyrol or collargol. The author has had no experience of artificial closure of the tube by means of bone splinters, or skin flaps and catgut. He always tells patients and their doctors that he cannot promise a perfectly dry ear after the radical mastoid operation. However, since the introduction of Marriages's skin-grafting method the results as regards closure of the tube have been much better. In cases in which the radical operation has been performed Brühl, who does not believe in closing the tube, recommends drying out the cavity with hot air, probably by means of a dental appliance. He also mentions the application of trichloracetic or lactic acid to the tubal region and exposure to real and artificial sunlight.

(2) A faulty state of the patient's general health. During the war, when operating on young and otherwise healthy men, it was remarkable how well the radical mastoid cavity healed—much more quickly than in ordinary hospital cases.

(3) Narrowness of the external meatus and want of care of the operation cavity lead to lack of success.

A New and Simple Plastic-Flap Method in the Radical Mastoid Operation. An incision is made in the posterior meatal wall in a direction parallel to its bony axis, as in the Panse method, but instead of stopping at the concho-meatal junction, as Panse does, it is prolonged into the concha for a distance of one centimeter (depending upon the size of the ear). The right-angle, or cross incision, of Panse is purposely omitted. A superior and inferior flap is produced. H. Dintenfass[4] states that this resembles the Stacké incision except that it is longer, Stacké stopping at the auricle. If there is much redundant subcutaneous tissue it is cut away, but an effort is made not to be too radi-

(4) Atlantic M. J., April, 1927.

cal here because of the danger of interfering with the blood supply of the skin remaining. The upper flap is anchored in the region of the attic vault by means of a silkworm-gut suture which goes through the temporal muscle and the skin. The lower one is attached to the

Fig. 19.—The formation of the superior and inferior flap kept in position by the silkworm-gut sutures.

sternomastoid aponeurosis over the facial spur by another silkworm-gut suture which also takes in the skin. The knots are not included in the mastoid cavity, being tied externally. (Fig. 19.) These sutures are left in for ten days. The postauricular wound is closed by interrupted catgut.

The extension of the incision into the concha prevents the occurrence of a small meatal opening, and insures adequate exposure for dressing and drainage. By omitting the right-angle incision, traumatization of the flap is to a great extent eliminated, thereby enhancing the growth of epithelium in the bony cavity.

The method is not only simple, but has the added advantage of being very quickly performed—an important item in a long and debilitating operation. Of course it must be remembered that the success of all flap methods depends considerably on the thoroughness with which the bone is exenterated. An improperly performed radical mastoid operation would naturally impede the epidermatization of the bony cavity. An open and infected eustachian tube would also bring the method into disrepute.

The Ultimate Treatment of a Radical Mastoid Operation. In reporting three cases G. B. McAuliffe[5] does not contend that the radical mastoid operation is unnecessary, but that in many instances it can be avoided. The patient should have a square deal. If the operation is done for the purpose of preventing intracranial sequelæ it is absolutely the only surgical method of accomplishing it. But the patient should be informed that the treatment does not cease a month after the operation; that it may be necessary to look after the ear for years. If the operation is done for the cure of chronic otorrhea, no promise should be held out for a permanent cure. No promise should be made that the hearing will improve. The operation will give him practically a dead ear in the majority of cases. Furthermore, the surgeon should feel the necessity of a rigid follow-up procedure until the patient is as well as the operator can make him. He should not throw the case, after doing the operation, into the scrap heap of experience.

There is still too much *ipse dixit* in medicine and Aristotelian obedience does not make progress. Ears

(5) M. J. and Record, Oct. 20, 1926.

that are foul should be cleansed. If squamous epithelium cannot stand this it is surely not worth much as protection. The recurrences of the discharge are due to sepsis more than mere moisture. Therefore mild antisepsis with due regard to the integrity of the epithelium covering will preserve rather than destroy the epithelium. Drying the cavity can be easily done and the old practice of boric acid insufflations, provided the patient or the ear shows no intolerance to the drug, will care for the residual moisture and serve to exclude possible external aerial infections. It is a difficult matter to convert a mucous cavity into an invaginated skin cavity.

It may seem that the views stated above are very pessimistic, but the author is only stating what he sees. It is a distinct surprise to see a perfect radical mastoid operation. If the operation fulfilled the indications, there would not be so many modified radical operations advocated. This acknowledges the weak points of the procedure. Aurists have yet to see a better mode of attacking the disease—one that will not practically destroy the end organ of audition: one that will give a better cosmetic effect: one that will not leave the patient with an open cavity subject to every external insult. The principle of the operation is correct. Therefore, the ultimate treatment should interest those who lightly decide on this procedure for the cure of a chronic discharge which may never eventuate in intracranial complications.

Sinus Thrombosis; Cerebellar Abscess, Meningitis. Recovery after Opening the Cisterna Pontis. Blau[6] reports that a patient entered the hospital with stiff neck, general hyperesthesia, somnolence, vomiting, vertigo and headache. The otoscopic picture was that of suppurating cholesteatoma. Kernig's sign was positive; the labyrinth reacted. A radical mastoid operation was performed, with removal from the sinus of a suppurating thrombus and excision of the wall into the healthy

(6) Ztschr. f. Hals-, Nasen- u. Ohrenh., November, 1927.

region, uncovering of the middle and posterior fossa. Twenty cc. of cloudy spinal fluid was withdrawn. A colloidal suspension of silver was injected intravenously and methenamine was given by mouth. Increasing stiffness of the neck led to further lumbar punctures, which finally showed occasional gram-positive diplococci, but these were sterile on culture. Several days later the lumbar puncture was dry; therefore, a block was present.

Further exposure of the dura mediad of the sinus, uncovered a small bean-sized abscess of the cerebellum; further lifting of the dura along the pyramid released a teaspoonful of foul pus from the region of the saccus endolymphaticus. Finally, the cisterna pontis was reached and incised with an outflow of a large amount of fluid, which was at first cloudy, and later clear. A gauze drain was inserted. There was prompt improvement, but on the fifth day there was a marked rise in temperature; the drain was pressed out of the cisterna; a probe was inserted with an outflow of some clear fluid. Recovery was uneventful.

Although trypaflavine and methenamine and other medications were used, the prompt improvement after drainage of the cisterna was too definite to allow any doubts as to its efficiency.

Otitic Meningitis. This report by W. P. Eagleton[7] is based on thirty-three consecutive cases of meningitis, with ten operative and one spontaneous recovery. Ten patients were not operated on because they were in a terminal stage when first seen. Thirteen postmortems were obtained from the twenty-two deaths. All cases presented the clinical picture of meningitis; and the condition found at operation warranted the diagnosis of septic meningitis, which if not surgically attacked would have ended fatally.

The present conception of the surgical treatment of meningitis is based on the postulates that: (1) the pia-

(7) J. A. M. A., Nov. 6, 1926.

arachnoid membranes contain the protective mechanism of the brain against infection, being similar to the peritoneum in structure and function; (2) the anatomic structure of the subarachnoid spaces, their small meshes and larger basal cisterna, are well adapted to the purpose; and (3) the arachnoid, being of low genetic origin and capable of rapid proliferation, is thus enabled to wall off infection both from without and from within the brain.

If these contentions are true, the surgical treatment should largely resolve itself into a study of the normal pathways of the cerebrospinal fluid spaces.

Clinically, meningitis of otitic origin in a large proportion of cases passes through three stages; first, the stage of invasion of the subarachnoid meshes, during which general meningeal symptoms of greater or lesser intensity are present—elevated temperature, headache, slight stiff neck (if the base is involved), vomiting, variations in pulse, and dilated veins at the fundus, associated with a high cell count and increased globulin in the lumbar fluid.

The removal of the primary focus of infection by a mastoid operation during the stage of invasion is frequently followed by the disappearance of all meningeal symptoms (at least for a time); because the inflammatory process has entered the second stage, that of pia-arachnoid localization. During this period the lumbar fluid may be of increased or normal pressure, but with a low cell count.

The limited infection, after a variable period, passes into the third stage, terminal general leptomeningitis.

If during the second stage, or even early in the third stage, the localized collection of cerebrospinal fluid is evacuated through the route of infection, the septic process may be controlled. When, however, micro-organisms become diffused through the subarachnoid meshes, no operative treatment is of avail.

From an operative standpoint the cases of suppura-

tive meningitis, at an early stage, must be divided according to the region of protective reaction involved.

1. Posterior fossa cases, which must be subdivided into:

A. Labyrinth cases:
   (*a*) From infection through the internal auditory meatus.
   (*b*) By way of the ductus endolymphaticus.
   (*c*) From caries of the posterior semicircular canal.
B. Cases from caries of the petrous pyramid without labyrinthitis—Trautman's triangle, etc.
C. Cases secondary to thrombophlebitis of the lateral sinus.

2. Middle fossa cases:
   (*a*) Secondary to caries of the tegmen, apical cells, superior semicircular canal.
   (*b*) From thrombophlebitis of the small vein.
   (*c*) Associated with osteomyelitis of the squamous.

In any of the foregoing the operative discovery of the causative pathologic lesion will determine the area of the cerebrospinal fluid system to be drained.

Surgically, the vestibule of the labyrinth should be regarded as an outpost of the meninges. Consequently, in attacking meningitis from infection through the labyrinth at an early stage, it must be determined whether the path of invasion was (*a*) through the internal auditory meatus, or (*b*) following a caries of the petrous pyramid by way of the ductus endolymphaticus or the posterior semicircular canal; for if the internal auditory meatus is the route, the cisterna interpeduncularis must be opened; while in either of the latter, incision of the dura just internal to the lateral sinus may be all that is necessary.

In posterior fossa cases from localized caries of the petrous pyramid (Trautman's triangle, etc.) with a functioning labyrinth, incision of the dura posterior

to the petrous pyramid will evacuate pus or infected cerebrospinal fluid.

In meningitis following or associated with cerebellar abscess the author has found that the cisterna magna is enormously distended with an infected fluid, the evacuation of which may give almost instantaneous relief from the pressure as well as the meningeal symptoms.

Of the ten recoveries, four were posterior fossa cases; two with labyrinth infection, and two without.

Meningitis with primary involvement of the middle fossa may be due to caries of the tegmen or, more frequently, to a septic thrombophlebitis of a small vein which retrogrades through the bone and then enters the dura. The latter condition may be demonstrable during operation if the dura is stripped, millimeter by millimeter, from the superior surface of the petrous.

When it reaches the meninges, the infection is at first limited to the region above the tegmen but rapidly extends to the cisterna interpeduncularis, the opening of which will generally evacuate considerable fluid containing micro-organisms.

The early symptoms of middle fossa cases are: pain behind the eye, slight irregular temperature, external ocular paralysis, and irritability to light, with slight stiff neck and transiently slow pulse, associated possibly with hemianoptic indentations of the visual fields. The lumbar fluid is clear, with pressure slightly increased with or without an increased cell count.

Diagnosis of early meningitis can be made only by attention to the minutiae of the different symptoms—the appearance of the patient, his slight restlessness, occasional vomiting, the location and character of the pain, the irregularities of the pulse, the occasional slow pulse, the slight deviations in the temperature, the disproportion between the temperature and the pulse (a slow pulse with a normal or slightly elevated temperature), the hemianoptic indentations of the visual field (which may be transient), the external ocular paralysis

—the same as the abdominal surgeon recognizes appendicitis long before general peritonitis develops. In exceptional cases the surgeon may, by a careful study of the symptoms alone, be enabled early to differentiate the middle from the posterior fossa cases; but outside of the labyrinth and lateral sinus thrombosis cases, the diagnosis of the exact site of the meningeal exudate may depend chiefly on the operative observations (the location of thrombosed veins, dural adhesions, thickenings, granulations, necrosis or fistula).

Absence of reactability to the cold caloric test in the upright and recumbent positions of both sides with good hearing occurs in diffuse terminal leptomeningitis.

Absence of reactability to the cold caloric test of the opposite side to the lesion in the upright but present in the horizontal position signifies pressure; and when associated with a reduction of 50 per cent of the induced nystagmus to turning, it points to an exudate in the meninges.

In septic meningitis, operation should be done while the inflammation is limited to an area adjacent to the primary focus of infection or an adjoining basal cisterna. It is during the period of apparent quiesence when there are slight signs of meningeal involvement that surgery offers a fair prospect of recovery.

There is no doubt that nature frequently succeeds in spontaneously overcoming the infection in many cases, especially if the increased intracranial pressure is relieved by repeated lumbar punctures. The post-mortem in two cases showed spontaneous recovery with localized adhesions, death having resulted subsequently from other causes.

The ventricles are not invaded until the terminal stage; surgery is now useless, although irrigation (of the ventricles) may in the near future save cases, especially if associated with intraventricular introduction of a specific medication (Kolmer).

There are three distinct pathologic conditions in men-

ingitis which are amenable to surgery, during an early stage, while it is still localized: 1. An excess of infective fluid with or without exudate within the meshes of the arachnoid. 2. Necrosis of the cerebral cortex with excessive exudate. The first simply requires evacuation through a small dural opening; the latter, a large dural opening, which is apt to be followed by brain herniation. 3. Meningeal exudate into the subdural space secondary to a brain abscess or a complicating sphenoid or accessory sinus suppuration. Its relief calls for extensive incision of the dura without injury to the underlying pia-arachnoid.

There is no surgical panacea for terminal septic leptomeningitis, such as subarachnoid irrigation. No one surgical procedure is uniformly successful even in the early stage. The surgeon must diagnose the exact site while the infection is limited, and then surgically attack it. How this is to be accomplished must depend on each case.

Principles of Surgical Treatment.—1. Eradication of the primary focus of infection.

2. Evacuation of the infected fluid in the basal cisterna by small dural openings, associated with drainage by punctures in the occipito-atloid and lumbar regions; or in cerebral necrosis or subdural space exudate, evacuation by a large dural incision.

3. Parts put at rest by ligation of the common or internal carotid.

After-Treatment.—Repeated lumbar punctures associated with transfusions from an immunized donor in order to increase the immunity of the cerebrospinal fluid by osmosis of the immunizing contents of the blood into the cerebrospinal fluid system.

Subarachnoid Irrigation.—In the early stages, the author has given up attempts to wash through and through because of the danger of disturbing the delicate adhesions. However, a modified Ringer's solution may be used to replace the evacuted septic fluid, associated

with puncture needles in the occipito-atloid and lumbar regions, provided the fluid is introduced without pressure; otherwise injury may be done.

When the process is well advanced irrigation has a place but must be performed very carefully. As yet the writer has no definite plan how to select the cases for irrigation of the ventricles, although a recent experience would suggest that an infected ventricular fluid might thus be combated.

Putting the parts at rest by preliminary ligation of the common or internal carotid artery is of the greatest value—not only because it lessens the hemorrhage of the operation, but especially because the ligation mechanically removes the pounding of the artery in its passage through the basal cisterna. That ligation of the common carotid has a distinct influence on lessening the increased intracranial pressure is demonstrated by the immediate fall of the intra-ocular pressure, especially of the side ligated.

Pathology of the Ear

The Significance and Value of Microscopic Investigation of Middle Ear Suppuration in Serial Sections. Ruff[8] believes that general otologic experience teaches that endocranial complications during a chronic suppuration of the middle ear rarely occur except in the suppuration with an epitympanal perforation, that is complicated with cholesteatoma. The simple form of chronic suppuration of the middle ear with a tympanal perforation is considered to be without danger, because apparently it never ends fatally.

Statistics of investigations by Scheibe, Schlittler and Hofmann, which covered a large amount of material, confirm this view. Of seventy-three deaths caused by ear trouble in Bezold's clinic in Munich (1881-1910), thirty-seven had been caused by cholesteatoma, whereas

(8) Ztschr. f. Hals-, Nasen- u. Ohrenh., Nov. 8, 1926.

the simple chronic suppuration of the middle ear caused only one death. Of fifty-eight deaths in Siebenmann's clinic in Basel (1898-1917), twenty-three were caused by cholesteatoma. During twenty years, death has never been observed in a simple chronic suppuration of the middle ear without cholesteatoma.

Recently Uffenorde, Engelhardt and Hofmann have reported cases of a simple tympanic chronic suppuration of the middle ear which ended fatally. Uffenorde's first case, however, was doubtless an acute exacerbation of a chronic suppuration of the middle ear. The other withstands any criticism. The epitympanum was separated from the mesotympanum by formation of granulation tissue and of new bone, especially on the physiologically narrowed spot where the chorda tympani passes between the hammer and anvil. A retention of pus occurred in the aditus and in the antrum, the tegmen antri melted, and an abscess of the temporal lobe resulted. The infrequent occurrence of such a retention during a simple chronic middle ear suppuration is due to the fact that the swelling of the mucous membrane of the middle ear is not pronounced, and that drainage from the aditus and antrum is good. An empyema cannot develop because there are few peripheral pneumatic cells.

In Engelhardt's patient, the mechanism of propagation is not clear. There was no retention. The patient had influenza. Microscopic examination of sections, in Hofmann's patient, proved that a cholesteatoma was the cause of a sinus thrombosis and meningitis. Clinical differentiation between the two forms of chronic suppuration of the middle ear is sometimes impossible without a histologic examination. It is equally difficult to differentiate between the acute and chronic form. A cholesteatoma with acute exacerbation can be confused with an acute suppuration of the middle ear. Two cases in point are cited. The author stresses the necessity for a histologic examination of cross-sections, if far-reaching and practical conclusions are to be made concerning the

dangers of the various forms of suppuration of the middle ear.

Contributions to the Clinical Signs and Histology of Malignant Tumors of the Temporal Bone. Malignant tumors of the temporal bone which involve the organ of hearing may be primary tumors or tumors in the surrounding tissue which have penetrated into the temporal bone. Primary and secondary tumors of this nature are recognized by abolition or decrease in function of the acoustic and static organs, which occurring simultaneously with other clinical symptoms, make exact localization possible. The microscopic picture frequently shows a peculiarity, as tumors are observed which occur rarely in the organ of hearing or elsewhere.

Four cases are reported in detail by C. Ruf[9]:

(1) A case of myxofibrochondroendotheliosarcoma of the left temporal and sphenoidal bone, in which the patient, a man, aged 49, was treated with the roentgen rays following a diagnosis of tumor of the brain.

(2) A case of spindle cell sarcoma emanating from the posterior wall of the right osseous meatus in a man, aged 45. Surgical removal was followed by treatment with radium and the roentgen rays. The patient was living three months after the operation, without a recurrence of the tumor.

(3) A case of endothelioma of the sheath of the acoustic nerve with extension to the left temporal bone, in a woman, aged 60. The mucoperiosteum of the middle ear was intact. The tumor originated from the middle cranial fossa and penetrated into the recessus epitympanicus and the other middle ear cavities after destroying the osseous tegmen tympani.

(4) A case of primary squamous epithelium carcinoma of the outer meatus which penetrated into the cavities of the middle ear and thence into the temporal bone. The patient, a woman, aged 40, underwent an

(9) Ztschr. f. Hals-, Nasen- u. Ohrenh., 17:274, Jan. 31, 1927.

operation on May 8, 1925, and died on Jan. 22, 1926, of marantic atrophy.

Erosion of the Petrous Bone by Acoustic Nerve Tumor. Three cases of acoustic nerve tumor are reported by E. E. Towne[1], who states that these tumors are usually diagnosed without difficulty in advanced stages, because of the typical chronologic sequence of symptoms due to their origin from the eighth nerve. The first symptom is tinnitus, followed by deafness of the involved side. After a time, these are followed by signs of cerebellar incoordination due to pressure of the growing tumor in the cerebellapontile angle; by palsy of the fifth and seventh nerves, which are stretched over the tumor, and, finally, by symptoms of internal hydrocephalus due to pressure on the aqueduct of Sylvius. The interval between the onset of auditory symptoms and the appearance of the signs which make the diagnosis, usually is prolonged. In Cushing's latest tabulation of his material, the record duration of auditory symptoms in forty-six cases varied from six months to seventeen years, and averaged five years before surgical treatment was instituted. During this interval the diagnosis of acoustic nerve tumor may be suspected, but cannot be confirmed, until the adjacent cranial nerves and the cerebellum are involved.

It is obviously most desirable that earlier diagnosis should be made, so that the tumor may be operated on while it is still small, and while the patient is in good condition. The tumors almost invariably arise from the peripheral portion of the eighth nerve in the internal auditory canal, and erode the petrous bone as they grow.

In summarizing he states that tumors of the eighth nerve arise in the internal auditory canal and erode the petrous bone. There is a long interval, averaging about five years, between the onset of the initial auditory symptoms and the appearance of the signs which make

(1) Arch Otolaryng., December, 1926.

the diagnosis certain. The signs consist of palsy of the fifth and seventh nerves, cerebellar ataxia and internal hydrocephalus. During this interval the diagnosis cannot be made, because tinnitus and nerve deafness may be due to other causes. Previous attempts to show the erosion of the petrous bones in roentgenograms with lateral projection have been unsatisfactory. In all three cases of verified acoustic nerve tumor examined roentgenographically with the occipital projection described in this paper, extensive erosions of the petrous bone on the side of the tumor have been shown clearly. It seems probable that the use of this technic during the period when only auditory symptoms are present may lead to earlier diagnosis and surgical treatment. It should certainly be valuable as confirmatory evidence in the diagnosis of more advanced acoustic tumors.

Peculiarities and Possibilities of Surgical Removal of Neuromas of the Acoustic Nerve. E. Heymann[2] enters thoroughly into the discussion of the characteristics of these tumors. Of sixteen patients operated on, seven (43.7 per cent) lived. In 1923 four patients lived; in 1925 the four patients died because the author thought that the tumors were benign, and left parts of them at the anterior portion of the pons. He also states that he operated according to the imperfect method of Cushing. Death always resulted from respiratory paralysis. The author strongly recommends the occipital route and decries the translabyrinthian method, for various reasons.

He lays great stress on the fact that, next to prevention of hemorrhage, the greatest possible care and delicacy during the operation is the supreme law of extirpation of tumors. Even change of position, change of beds, transportation from one house to another may result in death. Also touching the tumors or the surface of the brain, the puncture of the brain or of the ventricle with a fine hollow needle, or a slight hemorrhage may

(2) Ztschr. f. Hals-, Nasen- u. Ohrenh. 17:109, Dec. 18, 1926

suddenly change the pressure in the brain of the patient suffering from a tumor of the brain, so that death may ensue.

Paralysis of the vessels occurs, the brain swells, and paralysis of respiration and of the heart sets in.

The Internal Ear

Models of the Labyrinth. Models of the labyrinth (King's College Hospital patterns, Fig. 20) have been made for purposes of investigating labyrinthine diseases and for teaching students. They are double natural size, and are made of Wood's fusible metal, which is sufficiently strong for ordinary purposes; the ampullary

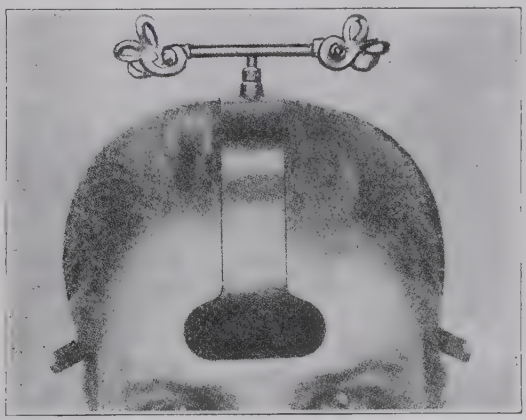

Fig. 20.—Model of labyrinth.

ends are painted in different colors in order to show them up. It is not difficult to make reproductions of the semicircular canals and cochlea from one petrous bone, and it is also easy to make models of the labyrinth if accuracy is not desired.

But the intention of A. H. Cheatle and V. E. Negus[3] has been to produce a model which would be properly

(3) Lancet, Apr. 2, 1927.

orientated. The method used was to fix a hollow tube between the internal auditory meatus of a dry skull, and to hold this hollow tube in place by means of a rigid frame, which had bars clamped on to the side of the skull in such a way that the lower edge of each bar coincided with the Frankfort plane—that is to say, the upper margin of the bony external auditory meatus and the lowest point of the orbit. Metal was run through the foramen ovale of one side to fill the cochlea and semicircular canals of that side, and to pass across the hollow tube to the opposite labyrinth which was also filled, the hollow tube being rigidly held in place by cement. The next step was to remove the bone and to extract the complete model in one piece. The casting presented considerable technical difficulties, which were overcome. Enlargements were then made to double size, not by a modeling machine as has been hoped, but by free-hand work. The models were made in silver.

Having secured the enlarged model, it was then necessary to arrange for reproduction in mass. This work was done successfully by Gerrard, who made piece moulds and cast the two labyrinths together in Wood's metal. The original frame was made by Mayer and Phelps, and they have made head frames with a pointer to lie parallel with the Frankfort plane in such a way that when the frame is on the head the labyrinth lies in correct orientation in all respects. The patient's head can then be put into any position and the exact relations of each of the canals are seen; rotation and caloric tests can be carried out with the frame in position. It must be remembered that there may be slight variations in the inclination of the canals in individual skulls.

The whole apparatus of enlarged models and head frame can be obtained from Mayer and Phelps, 59, New Cavendish-street, London, W. 1.

Is the Exenteration of the Labyrinth Justifiable in the Absence of Labyrinthine Suppuration? A Case

Report. In discussing the case in point, G. W. Mackenzie[4] concludes that:

1. The condition of the ear at the time the patient was referred by Dr. Gay was not that of middle ear suppuration of the acute form, as was supposed, for the otoscopic examination revealed a large heart-shaped perforation characteristic of the chronic form; besides, there was a cholesteatoma found at the operation, which was too extensive to be accounted for in a case of middle ear suppuration of only four months' duration. In other words, the case when first seen must have been one of chronic middle ear suppuration. The cholesteatoma extended in a median direction toward the posterior semicircular canal, leaving, however, the canal intact.

2. The vertigo experienced by the patient prior to the time she was first seen by the writer and that which she experienced for the next six years must have been due, taking every factor in the case into consideration, to the one and same cause, to-wit: congestive attacks of the inner ear, the result of seepage of bacterial toxins from the middle ear.

For instance, the character (rhythmic) and the direction (toward the affected side) of the spontaneous nystagmus, associated with the vertiginous attacks, establishes first the diagnosis of an irritative condition in the inner ear. The only thinkable pathologic lesion capable of producing this condition is a congestion, for all other types of lesions, including serous labyrinthitis, produce a nystagmus in the opposite direction—away from the side of the lesion. Besides, in the case of a destructive lesion it is not possible for a spontaneous nystagmus to be again directed toward the affected side in the case of labyrinthine disease pure and simple. Furthermore, the labyrinthine tests contradicted the existence of a destructive lesion and confirmed those of an irritative one.

(4) Laryngoscope, July, 1927.

3. The findings at the time of the first operation, May 7, 1919, revealed enough pathology in the temporal bone to warrant the procedure. Unfortunately the extension of the cholesteatoma and especially its matrix were such as to make it impossible for one to remove it all without opening the inner ear and thereby sacrificing the vestibular function and very likely the hearing also on that side. In cases of this kind it generally becomes necessary to make the sacrifice, eventually, in order to spare the patient's comfort, if not his life.

4. There are two possibilities in the case of recurring attacks of congestion of the inner ear secondary to middle ear suppuration:

A. *gradual* loss of function from metaplasia of the neuro-epithelium;

B. *sudden* loss of function from acute suppurative labyrinthitis.

This latter, more serious, outcome is fortunately rather rare. This is most likely to happen when the middle ear infection assumes an increased severity from insufficient drainage and ventilation. When danger of this kind threatened, the patient would develop an increase in the intensity of the vertigo and headache. On such occasions she would report and submit to thorough cleansing of the ear, which was followed by prompt improvement in all the symptoms.

5. Headache in the presence of middle ear suppuration should always be looked upon with suspicion, since it is a symptom common to all intracranial complications of otitic origin. The inner ear contains so many preformed ways for the spread of middle ear infection to the intracranial structures that it may, in a way, be classed among them. In the presence of an acute diffuse suppuration of the inner ear there is more or less headache from a complicating serous meningitis. In this case the inner ear was not invaded by the infecting organisms, but by their toxins. Therefore, the above explana-

tion does not account for the patient's headache. The repetition of headaches that occurred simultaneously with the vertigenous attacks were merely coincidental and due evidently to meningeal irritation from the same general cause, namely, increased toxicity of the bacterial toxins from retention and stagnation.

6. The average individual would probably elect to have a slight remnant of hearing destroyed on one side where the fellow ear is normal in preference to the continuance of a symptom that had incapacitated him for six years. The patient at this writing is comfortable, free of vertigo and happy with the results. The writer feels that if he had it all to go over again he would act exactly as he did; that is, operate conservatively the first time and allow the patient to decide later whether he wished to have an operation performed on the inner ear to spare him the continuance of an unbearable vertigo.

Propulsion Vertigo. In cases of vertigo the physician is frequently confronted with the anamnesis that "the floor gives way under me," "I must grasp something" or "I fall forward." A case reported by D. Griessmann[5] is that of N. N., aged 38, with vasomotor disturbances. The patient suffered from paroxysmal tachycardia, as he said, on account of overwork. The inner organs, the nervous system and the fundi of the eyes were normal. There was pronounced dermographia and inclination to soft defecation. The strongly alkaline urine contained much calcium phosphate. Several times, while asleep, or on awakening, the patient suffered from attacks of tachycardia which lasted for ten minutes. Violent nervous after-effects had been present, severe and painful tension in the head, a strong pressure toward both ears and a feeling of fullness in them. There were no noises and no diminution of hearing, but the patient had the sensation that the whole body was flying forward. These sudden attacks lasted only for a moment. When the

(5) Ztschr. f. Hals-, Nasen- u. Ohrenh., Feb. 22, 1927.

patient was lying on the right side, a forward propulsion was felt; when he was lying on his back, an upward propulsion was noticed.

The propulsion occurred only three times during three days. The equal influence on both labyrinths was caused by vasomotor disturbances. Such vasomotor phenomena occur frequently in neurasthenic and neurotic persons, without organic disease. In the case reported, the strong alkalinity of the urine and the great secretion of calcium pointed to a shifting of ions in the chemical processes in the body.

The therapy of so-called functional vasomotor disturbances of the vestibulary apparatus is discussed comparatively little in textbooks. The ice-cold feet of the patient should be warmed with applications of hot water bottles. Nicotine, coffee and tea should be forbidden during the periods of the attack. A glass of light red wine, at noon and in the evening, has proved to be of merit on account of the deviation of the blood into the dilated vessels of the skin. Diluted hydrochloric acid after meals is recommended to correct the strong alkalinity of the urine and the phosphoruria. For the vasomotor attacks of dizziness, sedatives and mild narcotics are indicated (carbromal, U. S. P., monobromisovalerylurea and small doses of phenobarbital). After the acute symptoms have disappeared, the author prescribes primary sodium phosphate (primary sodium phosphate, 50 Gm., syrup of raspberry, 50cc., and distilled water to make 500 cc.). A tablespoonful of this should be taken in the morning. Psychotherapy should be considered, because the mind is affected by these attacks of dizziness.

Some Additional Cases of Vestibular Disturbance. C. O. Nylen[6] reports sixteen additional cases of vertigo dependent on the position of the head. Five were due to peripheral and eleven to central disorders. Cases 1 and 2 were due to inflammation in the middle ear; cases

(6) Acta oto-laryng., 9:325, 1926.

3 and 4 to degenerative changes and case 5 was toxic (cocain).

In the second group, cases 9 to 16 were found in connection with brain tumors, whereas case 6 was due to arteriosclerosis, case 7 to cerebral syphilis and case 8 to multiple sclerosis.

In five, nystagmus was present only when the head was inclined backward and somewhat to the side (the position, according to Borries, in which the labyrinth receives its greatest stimulation). The others all showed a nystagmus when the head was in a forward position, when it was turned to one side or the other or when it was inclined backward. It appeared more often with the head toward the side and was usually horizontal-rotatory. The central lesions often showed a vertical nystagmus.

Past pointing was not marked in any subject. When it appeared, it was found to be greatest in the positions causing the highest intensity of nystagmus. The falling reaction was irregular, but in the cases of peripheral lesions tended to be in the opposite direction from the nystagmus. Four subjects carried the head in a fixed position and developed vertigo when this was changed. The position assumed was: the face turned away from and the head bent toward the side of the lesion. This occurred in certain cases of brain tumor. The caloric reaction was normal in ten cases, reduced in some, but absent in only one case.

Seven subjects were rotated; four gave normal reactions. Two patients with cerebellar tumor failed to show reactions from the side of the tumor. The patient with multiple sclerosis reacted only in certain positions. In general, a subjective sensation of vertigo developed in the positions showing nystagmus. One patient with a vertical nystagmus downward complained of feeling as if he were flying upward. He grasped objects in order to keep himself "down on the earth."

The hearing was reduced in the five patients with peri-

pheral lesions on account of local conditions. With three exceptions, the hearing was not greatly decreased in the other subjects.

Influence of Vision on the Vestibular Turning and After-Nystagmus. From his study J. Ohm[7] comes to the following conclusions:

1. In the turning experiment in the dark a purely vestibular nystagmus occurs in jerks in the direction of turning. It is followed by a strong after-nystagmus of long duration, in the opposite direction.

2. In the light, with uncovered eyes, pendulum-like nystagmus occurs which is of greater amplitude and frequency. It is a mixed nystagmus of an optico-vestibulary nature, which the author named an opticovestibulary turning nystagmus. The term "railroad nystagmus" (Bárány) is supplanted by the term "optic turning nystagmus." Scarcely any after-nystagmus follows when the conditions of the experiments of the author are observed. The state of excitation caused by turning is almost instantaneously suppressed by vision.

3. If strong convex or frosted glasses are placed over the eyes, an intermediate stage between the nystagmus in the light and in the dark is found, and the after-nystagmus becomes stronger. The vestibular component is more pronounced when frosted glasses are used instead of strongly convex ones. In one instance psychic interferences also seemed to be present.

Labyrinthitis, a Complication of Middle-Ear Suppuration: A Clinical and Pathological Study. A. L. Turner and J. S. Fraser[8] report their experience with labyrinthitis at the Royal Infirmary, Edinburgh, during a period of nineteen years.

A statistical study of 10,673 cases of middle-ear suppuration showed that labyrinthitis was found in 0.7 per cent of the acute cases, 1.6 per cent of the chronic cases, and 1.4 per cent of the total number. In 1905, Fried-

(7) Ztschr. f. Hals-, Nasen- u. Ohrenh., 17:259, Jan. 31, 1927.
(8) J. Laryng. & Otol., 1927, xlii.

rich stated that a labyrinth complication developed in one of every 100 cases of middle-ear disease.

Of 150 cases of labyrinthine disease, 64 per cent were those of males. In more than two thirds of the cases the condition occurred during the first four decades of life. These figures are consistent with the sex and age incidence of chronic middle-ear suppuration.

The authors give a classification of labyrinthitis based on clinical and pathological data and a subdivision indicating its association with acute and chronic middle-ear suppuration.

Among the most common etiological factors leading to acute or subacute otitis media with subsequent labyrinthitis are common colds, influenza, and scarlet fever. In cases of chronic suppuration, three factors are important: (1) the duration of the middle-ear discharge, (2) cholesteatoma, and (3) aural polypi.

In twenty-one cases of labyrinthitis complicating acute and subacute otitis, the onset of labyrinthine symptoms occurred at periods ranging from two days in the acute stage to three months in the subacute stage. In chronic middle-ear suppuration, the labyrinth may become involved at any period in the history of the discharge. Cholesteatoma was found in 63 per cent of cases of chronic suppuration in which exact information was obtained. A polypus occurred in fifty-two of 129 cases complicated by a labyrinthine affection. The authors emphasize the danger of removing polypi with the snare unless functional examination of the labyrinth is negative.

In the cases studied by the authors, various pathological conditions were found in the capsules of the labyrinth. Both acute and chronic cases of otorrhea were included in the study. Softening of the bone, erosions, and fistulæ occurred in a large percentage of the cases. In six cases, a patent oval window without any other associated lesions was discovered. Facial paralysis was noted in 8 per cent of the 150 cases. Cholesteatoma was

present in 62 per cent of those of chronic otorrhea with a change in the labyrinth capsule.

In the second section of the article the clinical aspects of 102 cases of labyrinthitis without intracranial complications are considered. Representative types are dealt with in detail.

In thirty-eight cases of circumscribed labyrinthitis associated with chronic middle-ear suppuration, the region of the lateral canal was involved. The severity and duration of the labyrinth attacks varied. Latent and active periods alternated. As a rule, the middle-ear type of deafness with considerable loss of hearing was present. Spontaneous nystagmus may be present or absent. Its duration varies. The fistula sign was obtained in eighteen of the twenty-four cases studied. A typical case is reported.

The diffuse acute manifest type of labyrinthitis was found in fifteen cases. Twelve of these were purulent in character and three were serous. Symptoms due to the disturbance of the static labyrinth predominated but complaint may be made of tinnitus or increased deafness. The attack is initiated by sudden vertigo and disturbance in equilibration. Nausea and vomiting accompany or follow these symptoms. During the early stages, there is a well-marked horizontal and rotary nystagmus to the sound side. In acute serous labyrinthitis, headache is not complained of, but in the uncomplicated purulent type, occipital headache is usually present. Fever was noted in the initial stages of four cases of purulent labyrinthitis. In the serous type, there is usually no elevation in the temperature. Functional examination of the ear is necessary to determine the exact type of diffuse labyrinthitis. The term "serous" is used to designate cases in which a remnant of hearing remains.

Three cases with complete clinical data are reported to illustrate the two types of acute diffuse labyrinthitis.

As the acute stage subsides and the manifest symp-

toms disappear, the pathological process becomes both chronic and latent. The condition is known as chronic (latent) purulent labyrinthitis. Thirty-seven such cases were recognized. Recognition of the purulent focus is of importance as operative interference may result in meningitis.

The spontaneous cure of the purulent process results from organization with fibrous tissue and new bone. This condition was observed six months after the onset of the acute stage. When ossification of the diseased labyrinth is complete, the sound labyrinth assumes a compensatory function. The clinical diagnosis of the healed functionless labyrinth is based on the relative duration of the after-nystagmus obtained by rotating the patient to the right and to the left.

Neurolabyrinthitis of Focal Infection in a Case with a Plus-Four Wassermann. In this interesting case, reported by G. W. Mackenzie,[9] the diagnosis of neurolabyrinthitis was established on the strength of the history and findings, particularly the latter. The impairment of hearing was distinctly of the perceptive type: The patient claims to have heard his own voice as though it was far away, and when he spoke his voice was rather loud, just the contrary to that found in the conductive type of deafness. Furthermore, the Weber was referred to the better-hearing ear; the bone conduction was shortened; there was diminution of hearing for low, middle and *high* tones by air conduction.

The vestibular nerve was involved with the cochlear, as evidenced by the history of vertigo, the diminution of after-turning nystagmus to both sides, more especially to the affected (left) side, the negative caloric reaction, and the typical galvanic findings of vestibular nerve involvement, to-wit: Absence of reaction on the affected (left) side, with preservation of reaction on the other (right) side.

In this case there were two etiologic factors present,

(9) Laryngoscope, December, 1926.

either of which is capable of producing neuro-labyrinthitis. They were syphilis and focal infection. In the case of syphilis, the tendency of the affection is to be bilateral; whereas, in focal infection the tendency is toward unilateral involvement. A knowledge of these facts led the writer to suspect the neuro-labyrinthitis in this case to be of focal infection origin rather than syphilitic; however, it did not allow him to ignore the syphilis or to relax its treatment.

The characteristic blood findings clinched the diagnosis of focal infection. It has been the writer's experience, in cases of focal infection, to find the total white blood cell count ranging from 10,500 to 16,000 with a small lymphocyte count somewhere between 30 and 38 per cent. Even more conclusive were the blood findings on three consecutive days (March 18-19-20); the first count was made just before extraction of the last four infected teeth; the second count was made the day after, and the third count the second day after the extractions. There was nothing else done at this same time to influence the blood findings, nor did the character of the Wassermann change in any way.

The improvement in the blood findings marked a definite change for the better: (*a*) general sense of well being; (*b*) increase in body weight; (*c*) cessation of vertigo; and (*d*) rapid improvement in hearing.

Concerning the left vestibular *nerve* which was completely out of function at the height of his trouble, as indicated by its negative conductivity (reactability) to galvanism, it improved sufficiently, after a few months. to be again responsive, but not so the vestibular *labyrinth,* which failed to react to cold water (caloric test).

The lack of improvement in his Wassermann, though unfortunate in a way, served a scientific purpose, and allowed an opportunity to study the comparative effects of syphilis and focal infection under the most favorable circumstances. Had the syphilis played the least etiologic role in the neuro-labyrinthitis, such marked improve-

ment in every respect could hardly have been expected without a concomitant improvement in the Wassermann.

The Management of Internal Ear Infections. Report of Six Cases. In the first case seen by J. M. Smith[1], despite active signs of labyrinthitis, a normal spinal fluid and an active labyrinth contraindicated a labyrinth operation. Thorough removal of the surrounding infection resulted in a prompt recovery.

In the second and third cases, both labyrinths were dead, the infection was successfully walled off from the meninges, with normal spinal fluids. In view of the fact that the necrotic areas involving the internal ear were apparently filled with healthy granulations, labyrinth operations were not performed, and they promptly recovered.

In the fourth case, there was a diffuse meningitis from the beginning. It is interesting to note the marked improvement following the drainage of the spinal fluid through the cochlea, also the fact that free streptococci were demonstrable in the clear spinal fluid with a normal cell count.

In the fifth case, the spontaneous rotatory vertical and horizontal nystagmus, unchanged in erect or prone position, following both hot and cold caloric tests, indicated brain lesion from the beginning, probably an encephalitis.

In the sixth case, recovery followed a labyrinth operation, despite the fact that there was a cloudy spinal fluid with 18,100 cells present.

Miscellaneous Conditions

Microscope for the Ear, Magnifying from Ten to Fifty Times. So far the membrane of the drum has been inspected either in its natural size, or with a magnification of from two to five times. Greater magnifications allow a better diagnosis. Old and recent perfora-

(1) Laryngoscope, June, 1927.

tions, fine scars versus defects, transudation lines and other conditions can be recognized with certainty. The various degrees of tension are easily visible, also the current of the blood in the capillaries and veins. Several instruments have been devised by others.

E. Lenscher's[2] apparatus and the technic are described in detail. The speculum and the microscope are not solidly connected, but allow a space of 5 cm. between them. The membrane of the drum is magnified from ten to fifty times. The patient is not made uncomfortable. All parts that can be inspected by ordinary inspection are made visible. The apparatus allows:

1. A magnification from ten to fifty times with ordinary light.
2. A magnification from ten to fifty times with light free from red rays.
3. Observation of processes of vibration through the Siegle speculum in a magnification from ten to fifty times.
4. Binocular observation.
5. Simultaneous observation of the magnified picture by two observers.
6. Measurements of the visible portion of the ear in three dimensions.

Tic Douloureux Cured by Mastoidectomy. A case of tic douloureux is reported by H. S. Wieder[3] apparently cured by a mastoidectomy. The patient had suffered for several years from mastoid tenderness and a full feeling in the right ear. Later pain developed in the face which other measures had not relieved.

Examination of the right ear showed acute congestion and dullness of the tympanic membrane with redness of the long handle of the malleus. The external canal was somewhat congested and tender. The left ear appeared normal. The nose showed a deflection of the septum high up on the right and low down on the left.

(2) Ztschr. f. Hals-, Nasen-u Ohrenh., Feb. 22, 1927.
(3) Arch. Otolaryng., April, 1927.

There was no discharge, and transillumination did not reveal any abnormal condition. The nasopharynx was red and congested, but there was no secretion. The tonsils were of moderate size with large crypts, which at the time of examination did not contain debris; however, they frequently contained debris, which the patient herself expressed.

After several weeks of treatment, the subjective and objective signs in the ear disappeared, with the exception of the tenderness over the right mastoid and the tendency of the facial neuralgia to recur oftener and to be more severe.

It was decided to perform an exploratory mastoidectomy in an effort to relieve the tenderness over the mastoid and possibly also the facial pain.

The lateral sinus was exposed, and the area that appeared as an area of absorption in the roentgenogram proved to be a large space without contents, lined with thin epithelium overlying and behind the lateral sinus. The walls of this space were smooth, and it resembled a large cell, but whether it was purely developmental it is impossible to state. The remainder of the mastoid was rather diploic in type, without any pathologic appearance, with the possible exception of a moderate congestion of all the bone. The wound was sutured above, and the cavity was drained. The patient left the hospital in eight days, and was discharged from care with the wound entirely healed within three weeks.

Since the operation, which was performed three years ago, the patient has never had a recurrence of the pain in any branch of the fifth nerve, and does not feel any tenderness over the mastoid, so that she can sleep on her right side for the first time in twelve years, can wear tight hats and can use the telephone with the right ear in a normal manner. She has tested herself by riding in a high wind in an open automobile, and has gone through numerous storms without the slightest discomfort. She never has any further drooping of the

right upper eyelid, and so noticeable was the change that it was remarked by some of her friends who did not know she had had an operation. Her hearing is about the same as before the operation, being slightly subnormal in the right ear, and she still suffers from a slight roaring when she has a cold in her head, but it is transitory.

There are two possible explanations of the symptoms manifested by the fifth nerve in this case. One is that they were due to direct disturbance with the function of the trunk of the nerve through interference with its circulation as it passes over the apex of the petrous portion of the temporal bone, thereby affecting the gasserian ganglion. A similar condition is frequently observed in the case of the sixth nerve in Gradenigo's syndrome. This is the generally accepted explanation for these types of irritation involving the gasserian ganglion, the sixth and ninth nerves, and other parts, namely, a localized meningitis at the apex of the petrous bone or at least a marked congestion with the presence of toxins.

The other explanation is that the symptoms were due to reflex peripheral irritation of a stimulus such as is obtained by irritation of the auricular branch of the tenth nerve (Arnold's), by tickling the external auditory canal. Coughing is produced to get rid of the irritant, presumably in the larynx. Another striking manifestation of the same phenomena is the frequent production of asthma by ethmoidal or other irritation.

The latter explanation appears to be worthy of consideration in the present case, because of the absence of a gross pathologic condition in the mastoid sufficient to explain involvement as deep as the apex of the petrous bone, and especially because of the duration of the condition and the localized tenderness of apparently neuritic origin, without a marked pathologic condition in the bone. The whole question of facial involvement in this case could more easily have been traced to the teeth and

to the inflammation following the injections of alcohol, were it not for the fact that all facial symptoms were so completely relieved by the mastoidectomy.

Explanation for the Symptom of Paracusis Willisi. In an attempt to determine the cause of the symptom called "paracusis Willisi," G. E. Shambaugh[4] suggests two possible explanations. The first is that extraneous sounds in some way actually increase the acuteness of the response in the hearing mechanism. The other is that the symptom of paracusis is occasioned by the fact that in a noise the person with normal hearing suffers a handicap in hearing because of the confusion created by these extraneous sounds, and involuntarily, therefore, raises his voice. The person with obstructive deafness, protected from the confusion of extraneous sounds, sometimes readily hears the raised voice in such surroundings even better than the person with normal hearing.

As regards the first proposition, namely, that the ability to hear is actually increased in a noise because of the stimulation of the hearing mechanism, two hypotheses have been advanced. One is that in cases of deafness caused by rigidity of the conducting mechanism the extraneous sounds temporarily overcome this rigidity, thus making it possible to hear the spoken voice better. This seems to have been expressed first by Buck. It was later voiced by Politzer.

The other hyopthesis is that extraneous sounds, by stimulating the end-organ of hearing, in some way produce temporarily an increased sensibility of this mechanism, and for this reason a person hears better in a noisy place. This idea was expressed by Urbantschitz.

Neither of these hypotheses makes a strong appeal. In the first place, the idea that the conduction of sound impulses is so improved by extraneous noises as to make it possible for a deafened person to hear the voice better than a normal person does not seem probable when one remembers that the cases in which paracusis is most

(4) Arch. Otolaryng., September, 1927.

conspicuous are those in which the patient suffers from bony ankylosis of the stapes, a condition which is not appreciably loosened up by any method.

The second hypothesis, namely, that in the presence of extraneous sounds the nerve itself, which is the sound-perceiving mechanism in the labyrinth, becomes hypersensitive, thus rendering it possible for the deafened person to hear the voice better, is also hard to accept. This voice should also be heard better. This, however, does not appear to be the case. Moreover, if this hypothesis were the true explanation for paracusis, there does not appear to be any reason why its phenomenon should be restricted to but one type of deafness, namely, that resulting from rigidity of the conducting mechanism; one should expect it as well in cases of partial nerve deafness and also in persons with normal hearing.

There is left the possibility that the second explanation may be the true one, namely, that the increased ability to hear the voice in a noisy place is only apparent.

After conducting a series of experiments with the audiometer he arrives at the following conclusions:

1. A person with normal hearing in the midst of extraneous sounds experiences diminished hearing throughout the tone range. This diminished hearing is greater for the lower tones.

2. A defect in hearing which is the result of stapes fixation is not improved in the presence of extraneous sounds. The differences noted showed rather an increase in the defect.

3. A person with normal hearing who uses the open-piece while riding on the train suffers a defect in hearing for the audiometer, fully as great in the lower and middle tone ranges as that of the person with advanced deafness which is the result of otosclerosis.

4. The symptom of paracusis Willisi is not produced because the deafened person hears better in noisy surroundings, but is dependent on the increased difficulty

of hearing which the person with normal hearing experiences in the presence of a noise. The increased difficulty in hearing for all tones, including the voice, which the normal person experiences in the presence of noise results in an effort, more or less unconscious, to raise his voice sufficiently to overcome this handicap. The person who is deaf because of fixation does not experience an increased handicap in the presence of extraneous sounds, since his deafness for the low tones effectually shuts out most of these extraneous noises. In noisy surroundings, therefore, the actual handicap experienced from obstructive deafness may even be less than that experienced by the normal person, because of the confusion created by extraneous sounds. This explains why a deafened person will often hear the voice better than one with normal hearing, for example, while riding on the train.

Fragilitas Ossium and Deafness. J. J. Shugrue, R. Rockwood and E. E. Anderson[5] report four cases of blue sclerotics, brittle bones and deafness; three illustrate the symptoms and signs of the disease and one the familial transmission. The cases are characterized by blue sclerotics, early and continued occurrence of fracture, because of the fragile type of the bones, and sometimes the development in early youth of progressive deafness.

The disease is hereditary and a patient may have one, two or all symptoms. Children afflicted with the blue sclerotics alone usually die in infancy. When the blue sclerotics are first manifest in adolescence they are associated with brittle bones, and later deafness may supervene. The disease is uncommon. It is progressive, although concomitant with longevity.

The Nature of Progressive Deafness. The term "progressive deafness" as used by S. J. Kopetzky[6]. signifies any deafness that is progressively getting worse;

(5) Arch. Int. Med., January, 1927.
(6) Arch. Otolaryng., May, 1927.

consequently, it embraces all types of deafness as they are ordinarily classified.

Ordinarily, cases of deafness are divided into two groups, the distinction being made by the use of the various tests for hearing. The response to these tests determines the part of the tone scale in which most of the hearing is lost. According to this determination, one group is designated as being affected in the lower scale and another in the high scale. The former is said to be due to an interference with the conduction apparatus and deafness of this type is called *conduction deafness.* The other is considered as resulting from an impairment of the receptive organ or its central connections and is therefore termed *perceptive deafness.* Most investigators and clinicians have discarded the terms *catarrhal* and *nerve* deafness as being unscientific, nondescriptive and misleading.

In the examination of sixty-three patients showing increased impairment in both the upper and lower tone ranges he finds the following outstanding features:

1. Eighty-eight per cent of the patients said that their deafness was progressive.

2. Sixty per cent gave a definite history of deafness in other blood relatives.

3. One hundred per cent had increased bone conduction.

4. One hundred per cent showed a raised lower tone limit.

5. Forty per cent of the patients were examined by an internist, and all showed a chronic metabolic disease elsewhere in the body.

6. One hundred per cent showed a disturbed calcium metabolism; 84 per cent had a decreased blood calcium, while 16 per cent had an increased blood calcium.

7. Seventy-six per cent showed an increase in the blood uric acid.

The author believes that:

1. Progressive deafness is not a distinct entity.
2. In most instances progressive deafness is a local manifestation of a general metabolic disorder.
3. The present classification of defense is a hindrance to investigation and research in that it offers both a hypothesis and a conclusion.

Endocrine Hypofunction in Ear Disease. In a period of the past fifteen years much of the structure and point of view of physiology and functional pathology has been revised and reconstructed on the basis of the probable influence of the internal secretions. The greatest diversity of symptoms, seemingly unrelated and not explainable except by means of endocrinology, are encountered in dysfunction of the thyroid gland. It is at once obvious that the controlling factor may be either chemical or nervous in origin. In other words, the internal secretions may produce their own control by chemical balancing, or the control may be from the central nervous system. This is perhaps the explanation why hypofunction is more often seen as a sequel to an illness, worry and similar harmful processes than as an apparent spontaneous incidence. The great majority are those cases in which the hypothyroidism is one of lesser degree and in which many of the grosser signs and symptoms are not in evidence.

Every day brings fresh evidence of the vital influence that the functions of the glands of internal secretion have upon the general bodily and mental health. It is justifiable according to D. W. Drury[7], to assume that the strain inseparable from modern civilized life is likewise able to produce endocrine imbalance, although the causative factor must operate over long periods of time. The prevalence of infections of various kinds, and the frequency with which an individual living under modern conditions succumbs to a chill or other disorder not definitely diagnosed, are factors which have to be reck-

(7) Boston M. & S. J., Aug. 4, 1927.

oned with when considering the etiology of cases of hypofunction. Many of the signs, therefore, are so slight as to require the most minute study and the most careful observation for even tentative evaluation. Thus the family history is very important, while in younger people it may be even necessary to examine the parents. This should not be construed as implying direct transmissibility. Constitutional tendencies are, however, important.

These complex involvements account for many of the cases of general debility and run-down conditions, which certainly form one of the most numerous groups met with in practice. The similarity in general appearance of cases of well marked hypothyroidism and senility has frequently been noted, in both the psychic and physical features of the two conditions. The characteristic mentality of the aged, with the loss of memory, tendency to somnolence and lack of grasp of difficult or complex matters, has its counterpart in that of marked hypofunction. The impaired hearing, tinnitus and vertigo, dry and scanty hair, and arteriosclerosis, of the one are likewise characteristic of the other. There is a pathological old age, setting in prematurely or associated with distinct accentuation of the cachexia. A moderate normal mental activity is necessary to the prolongation of life, the importance of excessive emotional and psychic activity in causing senile changes will probably be doubted by none.

In special practice the changes are most interesting and worthy of notation. The characteristic swelling invades the mucous membranes, the membrane of the mouth assuming a whitish color, while that of the larynx leads to alterations of the voice. These cases do not have a resonant voice for singing. The swelling of tonsils and uvula makes nasal breathing very difficult, if not almost impossible. Nasal operations do not benefit individuals when the nose is involved. The patients breathe with the mouth open and usually snore. This fact may

have a direct bearing on the seeming frequency of cavities in the teeth, especially at the gum line. The Eustachian tube and the tympanic cavity usually become involved by the swelling, causing a diminution of hearing, especially in the normal speech area. The tinnitus of these cases may be explained by infiltration of the eighth nerve, and the author has observed, also, that many times these cases complained of hallucinations of hearing, which is probably explained by loss of vascular tone and imperfect circulation. Vertigo and loss of equilibrium on slight provocation are sometimes met with. In the most marked cases of hypofunction, especially in young children, changes in the contour of the auricle are noted, while the external canal is narrowed and the skin very much thicker than normally found. Oftentimes the joint of the jaw is markedly relaxed by the stretching of the ligamentous structures, and this symptom is often seen in the other joints of the body. They are often termed "double-jointed" people. The adenoid material is often more boggy and certainly has more fluid in its content. Removal of the growth is helpful, but it is not always sufficient to give entire relief. In these cases several operators will have a hand in rotation, due to the fact that the difficulty of breathing is from the swollen mucous membrane. Here thyroid medication is indicated rather than surgery.

Emphasis should be laid on the fact, however, that thyroid medication is indicated only in those cases where thyroid failure has been demonstrated. In the author's cases a diagnosis of thyroid malfunction was established before medication was initiated. It is a specific replacement therapy, not a general panacea. In his own series, the author has a group of pituitary cases, diagnosed as such and exhibiting improvement with the extract of the anterior lobe, that parallel the thyroid group here discussed. A non-specific endocrine therapy would have been wholly ineffective in either of these groups. This fact has been demonstrated to the point of conviction.

Is There an Endocrine Factor in Otosclerosis? H. L. Warwick and H. M. Stevenson[8] raise the question as to whether a change in calcium metabolism due to endocrine disturbance may not be the cause of the formation of new bone in otosclerosis. The anterior lobe of the pituitary and the thyroid gland control calcium metabolism. The ovarian secretion inhibits both the thyroid and pituitary, and thus indirectly influences calcium metabolism. In pregnancy, the action of the ovary is depressed and its inhibitory action is removed. Hence the acromegaly of pregnancy. Hypertrophy of the pituitary occurs in pregnancy. Thus when the ovaries are depressed there results a secondary hyperfunctioning of the pituitary and an increased calcium assimilation.

Osteomalacia of pregnancy occurs when the supply of calcium needed for increased calcium metabolism is insufficient. The bony skeleton is called on to yield calcium. The osteomalacia and otosclerosis are alike in many respects. After pregnancy, when the need for much calcium has been removed, the hyperfunctioning pituitary keeps the calcium at a high level for weeks. Most of the excess is excreted but some may be deposited, as in otosclerosis. Otosclerosis becomes worse with each pregnancy. Calcium deposits are prone to occur in cartilage. Embryonic islands of cartilage occur in the footplate of the stapes and about the fenestra ovalis, the point of election of otosclerosis. It seems reasonable to the authors to suppose that the high level of blood calcium during pregnancy, due to the uninhibited action of the thyroid and the pituitary, may result in new bone formation in the embryonic cartilage islands in the labyrinthine capsule.

Progressive Deafness; Endocrine Malfunction as an Important Etiological Factor. Thirty-one cases of progressive noninfectious deafness (otosclerosis) in which the metabolism studies were made are reported by C. H.

(8) Acta oto-laryng., 9:317, 1926.

Lawrence[9]. Of these 22, or 70.9 per cent, showed definite evidence of metabolic disturbances.

2. The nature of these disturbances indicates that their origin lies in endocrine malfunctions.

3. The unfavorable effect of pregnancy upon deafness of this type may be explained upon the basis of its influence on metabolism *via* the endocrine apparatus.

4. The auditory apparatus is peculiarly sensitive to systemic conditions, either because of its developmental characteristics, or in certain individuals, of an inherited lowered resistance.

5. Treatment of the metabolic derangement associated with the deafness by administration of an extract of the endocrine gland at fault resulted in improvement of hearing in 14 out of 19 cases—73.6 per cent.

6. This paper is intended as a preliminary report. Convincing evidence can be adduced only after the study of a much larger series of cases. Such a study is now in progress at the Evans Memorial.

Vertigo and Deafness Associated with Hypothyroidism. In reporting a series of 24 cases R. C. Moehlig[1] states that, given a case of vertigo, with or without vomiting or fainting spells, ringing and buzzing in the ear, lessened or absent hearing, low or normal blood pressure, and a low metabolic rate, in the absence of striking hypothyroid signs, one is justified in the conclusion that he is dealing with a unique and characteristic symptom complex heretofore not appreciated as a clinical entity, and that the exhibition of thyroid in these cases may be expected to result in marked relief or complete cure.

Some of the conditions with which this syndrome may be confused are cerebello-pontile tumors, migraine, labyrinthitis, and syphilis. In the tumor cases, differentia-

(9) Laryngoscope, November, 1926.
(1) Endocrinology, May, 1927.

tion of a well developed case should offer no trouble, as there are present headache, choked disks (missing at times, of course), nystagmus and involvement of other cranial nerves. The basal metabolism is not affected. In early cases confusion is quite possible, but the therapeutic test is also helpful.

Differentiation from migraine offers less difficulty. While migraine symptoms are similar to the syndrome mentioned, nevertheless there is present headache, which the individuals afflicted with this vertigo do not usually have. Likewise, there is no difficulty in the hearing, nor is there any disturbance in the basal metabolism and a familial tendency is often present.

The Ear, Nose and Throat in Its Relation to General Medicine. In discussing the relation of general diseases to the ear, nose and throat, A. H. Rubenstein[2] directs attention to vertigo as an important factor. It is now generally conceded that the ear is a most important organ in the maintenance of equilibrium. Quite true, vision and muscle sense are important factors, yet the kinetic static function of the labyrinth is of paramount importance. The triad of vision, muscle sense and kinetic static sensation, allows us to make estimations of orientation and locomotion, estimate the rate of motion, of weight, and to realize our posture and our position. With these facts in mind, the symptomatic complaint of vertigo will be discussed.

It is not stated amiss that the average practitioner is at the very most only guessing at the clinical significance of this complaint. So often is it spoken of in such indefinite terms as gastric, or intestinal, vertigo, or due to refractive errors, or a nephritic, or neurasthenic or hysterical state. None of these per se are capable of causing vertigo. Every vertigo, be the etiology what it is, is caused by some stimulation affecting the labyrinth or the brain centers. Vertigo is caused by organic lesions of these centers or toxemic stimulation.

(2) Ann. Otol., Rhin. & Laryng., June, 1927.

The definite specific reactions which follow the stimulation of these centers by means of such tests as the Barany, the caloric and the galvanic reactions, include or exclude involvement of the labyrinth, the tracts to the brain centers and centers proper, with such certainty that no diagnosis of vertigo is complete without them. It is not meant to be implied that all cases with this complaint can be diagnosed by means of these functional tests, yet by their exclusion can a definite diagnosis be more easily arrived at.

Some Neurologic Complications of the Ear, Nose and Throat. Many cases of toxic vertigo have been observed by T. H. Weisenburg[3]. In one instance, a physician, who is a nose, throat and ear specialist in a neighboring town, experienced a dizziness which was so extreme that he had to give up his practice. The vestibular tests indicated a cerebellar tumor. My examination did not verify this. Everything that could be thought of was tried, and as he was an ex-major in the service, the patient was looking forward to a life of invalidism under the supervision of the Veterans' Bureau. He was an excessive cigaret smoker. One day he developed a bad cold and was compelled to stop smoking for a few days. To his surprise, he noticed that he did not feel dizzy. From that time on he has not had an attack, although smoking a cigaret will always bring one on.

In another patient, a clergyman, the dizziness was finally removed by the excision of both tonsils and some bad teeth. In him also, the vestibular tests indicated the possibility of cerebellar lesion. In a third patient, a physician practicing in one of the Philadelphia suburbs, the dizziness finally ceased after colonic irrigations. Here also the vestibular tests indicated cerebellar tumor.

(3) Arch. Otolaryng., June, 1927.

Disturbances of Production of Rhythm in Deaf-Mute Children. From his experiences O. Bénesi[4] concludes as follows:

1. Twenty-four deaf-mutes, aged from 8 to 15 years, were examined for their ability to reproduce optic, tactile and kinesthetic rhythms.

2. Only six children were able to make approximately correct optic and tactile reproductions. One child gave a false reproduction of tactile rhythm.

3. The optic test gave the poorest results; the tactile gave better results, and the kinesthetic the best.

4. Control experiments on normal and feebleminded children proved that they responded well to the tasks imposed.

5. Among deaf-mutes who reproduce rhythms, subjects with preserved labyrinth function were in the majority. They also formed the majority in the group of subjects able to reproduce the same rhythms.

6. Such an unequivocal influence of the absence or presence of the cochlear function cannot be shown.

7. The author believes, therefore, that the vestibular nerve plays an important rôle in the physiologic mechanism of voluntary rhythm. The experiments prove that it is probable that the labyrinthian influence on rhythm depends on the otoliths.

A Method of Removing the Organ of Hearing from the Cadaver Without Cosmetic Defect. Von Gyergyay[5] describes a trephine of appropriate size which is placed on the planum mastoideum, with the axis in the direction of the antrum, toward the tips of the roots of the first and second molar teeth of the opposite side, and set in motion. The resulting excision includes the antrum with cellulae mastoidiae, the membrana tympani and tympanum, the medial portion of the external canal, the labyrinth, the eustachian tube and part of the naso-

(4) Ztschr. f. Hals-, Nasen- u. Ohrenh., 16:7, July 31, 1926.
(5) Ibid., November, 1926.

pharynx, in one piece, well isolated from the other tissues.

The Problem of Bone Conduction: Theoretical Considerations. H. Herzog[6], formerly a follower of Bezold's theory that conduction of sound purely by bone does not exist, has changed his view. Small mirrors were fastened at various places on the conduction apparatus and on the temporal bone, transferring photographically to a kymograph the vibrations induced by a tuning fork. These experiments did not support the Bezold theory of exclusively craniotympanal conduction, but rather strongly indicated direct transmission of an appreciable volume of vibrations from the bony walls of the labyrinth to the perilymph. Therefore, two sets of vibrations are transmitted to the sensory epithelium: those directly from the bony walls of the labyrinth and those transmitted via the membrana tympani, ossicular chain and footplate of the stapes (the active movement of the stapes). It was found that the latter are slightly delayed; therefore a slight difference in phase exists. This difference in phase is believed to cause a damping and, therefore, a lessening of hearing by bone is brought about by the ossicular chain. If the chain is fixed, the vibrations direct from the bony wall are unhindered and strengthened and the stimulus to the sense organ is increased (increased bone conduction; lateralization).

Another test is described as follows: The ends of a U tube filled with water are closed by membranes. On one of the membranes is set a "tappet" to imitate the stapes footplate. It was found that the more the movement of the "stapes" was limited, the more strongly the vibrations of a tuning fork against the tube were perceived at the "round window."

Scientific Fundamentals of the Correction of Defects in Hearing. Bruenings[7] believes it is necessary to differentiate a qualitative and quantitative loss of hearing,

(6) Ztschr. f. Hals-, Nasen- u. Ohrenh., October, 1926.
(7) Ibid., October 6, 1926.

whether the defect is of mechanical or of nervous origin, and any instrument designed to correct loss of hearing must be able to overcome either, or both, of these difficulties. Mere increase in intensity of sound is not sufficient for the understanding of speech. It may do for the hearing of music, although much of the quality of tones is lost. A microphone with a disturbing fundamental tone or adventitious sounds (carbon particle vibrations) cannot reproduce properly the sounds of speech whose vowels and consonants lie in partial tone groups (the Helmholtz formants). The deaf person, whose deafness may be for either high or low tones, often hears sound well enough, but cannot distinguish the words; that is, he cannot understand speech, because he is incapable of perceiving the principal partial tones of the vowels and consonants.

By means of an acoustic projection apparatus, which accurately reproduces and amplifies sounds with their overtones in proportion, so that the timbre is properly preserved, the author demonstrates his thesis (the instrument is capable of varying the intensity of any part of the scale) by the following experiments:

The tone of a so-called electric piano is throttled by means of a series of filters so as to eliminate a group of overtones; the result is a softer, flutelike quality.

The fundamental tones are throttled, resulting in an overtone of rich timbre, resembling the tone of the oboe.

A tuning fork is struck with metal, the overtones are throttled, and the result is the soft tone like that produced when the fork is struck by the rubber hammer. Incidentally, this instrument shows that the weighted Edelmann forks are not entirely without overtones.

Other experiments were made with the violin, showing that considerable loss of high tones is necessary before it is heard as a flutelike sound; with the telephone bell, showing the effect of labyrinth deafness (loss of high tones) and with an automobile horn, showing the

changed tone as perceived in conduction deafness (loss of low tones).

Further tests were made with human voices, two sopranos, an alto, a tenor, a baritone and a bass, showing that the formants (principal partial tones) for the vowel "a" and the vowel "e" were practically the same for all the voices, thus proving by a scientific test what Helmholtz had intuitively perceived.

Tests were also shown with selected lists of words, with both deep masculine and high feminine voices, throttling from 5,000 cycles up. This test showed a change in timbre and difficult hearing for "i" and "e." Throttling from 3,000 on, caused errors in hearing to creep in.

In everyday life deaf persons learn to use secondary psychologic, acoustic and optic aids to understanding.

The loss of hearing for speech is much less when low tones are throttled 300 cycles downward, as the formants lie mostly in higher registers, and can be compensated more easily by raising the voice. So deafness of the middle ear type is more a problem of intensity. As whispered speech is lacking in fundamental tone, and consists largely of the formants, it is far more difficult to understand than conversational tones.

These tests explain the inefficacy of the present aids to hearing, and point the way for research. A scientific correction based on accurate analysis of the hearing will be the focus of otologic research in the near future. "We find ourselves at the cradle of a new otologic era."

The author says that otology is now able to produce, even if only with laboratory apparatus, something comparable to the work of modern ophthalmology.

Credit for this advance is given to a considerable number of investigators, both in physics and in otology, whose recent rapid increment is due to new knowledge of transformation of electric energy into acoustic properties, the radio development of high frequency technic and the discovery of the electron tube amplifiers.

Treatment of Deafness by Auditory Re-education with an Acoustic Tube. G. de Parrel[8] describes a method of treating chronic deafness by auditory re-educative exercises carried out by the aid of a special acoustic tube, which consists of a flat earpiece, covered with fine linen, which is applied to the ear, a flexible tube, and a washable mouthpiece into which the person carrying out the vocal exercises speaks.

The first exercises consist in going up and down the scales with all the different vowels, later several vowels are joined together and then rhythmic phrases are spoken or sung. The person who carries out the exercises should preferably have had his voice trained for singing, or at least should have a certain degree of vocal suppleness. The vocal exercises not only stimulate the sense of hearing, but the sounds cause a sensation in the ear of vibrations—a form of oto-massage. The improvement in hearing may be attributed to a combination of the two.

The Electrophonoide Treatment of Deafness. The electrophonoide method rests upon a thoroughly rational basis. It is founded primarily upon the work of Itard and Urbantschitsch, the latter of whom, after experiments carried out with infinite patience, showed practically that continued stimulation by the human voice could restore hearing by a process of re-education. Unfortunately, no human voice exists that can do the work and survive. No voice has range enough or strength enough to carry on such a treatment without completely breaking down. It remained for Zünd-Burguet to contrive and perfect an apparatus which reproduces the sounds of the human voice in all their varieties of pitch, intensity and timbre, and to conduct them to the ear without alteration or impairment by added foreign sounds. The sound-waves thus obtained act as a true physiological stimulus to the ear, so that it is the most ideal form of massage obtainable, its amplitude being

(8) Rev. de laryngol, July 15, 1926.

perfectly adapted to the organ under treatment. It can readily be seen how completely it differs from the ordinary otomasseurs, such as those of Delstanche and others, in which the vibrations mechanically produced are of an amplitude enormous compared with those of voice sounds.

The effect upon the ear of these physiological stimuli is a vaso-motor one. They cause, M. Yearsley[9] believes, an active hyperemia of the hearing organ, evidenced by the blush observed about the handle of the malleus and drum membrane, and the feeling of comfortable warmth experienced by the patient after application. As the treatment is given daily for about five minutes for some thirty or fifty sittings, this repeated active hyperemia results in a great improvement in nutrition. It is no exaggeration to say that adhesions become loosened and finally disappear, hearing improving and tinnitus being abolished or relieved as a consequence. In the case of old chronic suppurations, ulcerations heal and the otorrhea dries up. The hyperemia is not confined to the middle-ear, but extends to the external ear and labyrinth. Thus, increased secretion of wax is to be noticed in the meatus hitherto dry, and hearing is improved in cases of presbycusis. Further, the stimulation appears to affect the organism generally, patients experiencing a marked sense of well-being during the treatment. In post-suppurative, and especially in post-catarrhal deafness, the effects upon the hearing are good, often remarkable.

The symptom of hearing better in a noise (*Paracusis Willisi*), hitherto regarded as a hopeless sign, becomes rather an indication for treatment, and the resulting improvement is, as a rule, permanent. It must be pointed out that the Zünd-Burguet method is not a miracle, but a treatment. It has no place where hearing has never been, or is irreparably destroyed, nor has it any effect upon cases of syphilitic deafness. In successful

(9) Practitioner, November, 1926.

cases the results are inversely as the age of the patient and the duration of the lesion causing the deafness. Unless there is an appreciable improvement by the close of the first fifteen sittings, it is useless to continue. The amount of improvement noted is, however, no criterion of the final result, small beginnings sometimes leading to great endings. Tests are made, therefore, after the fifteenth sitting, not for the purpose of ascertaining what progress has been made, but rather to discover whether the patient has reacted. In most cases, from thirty to fifty sittings, which may be divided into two batches of thirty and twenty with from four to six weeks interval between them, are sufficient. In obstinate cases, once an initial improvement has been manifested, final results depend largely upon persistence and patience on the part of both patient and otologist. Relapses, when they occur, are due to neglect to remedy the original cause of the deafness. Thus, repeated colds due to nasal abnormalities will surely cause relapse unless these are corrected at the outset.

In the gradual failure of nerve acuity with the advance of years, the author has found the electrophonoide method to give excellent results in the, at present, limited number of cases in which he has used it.

Diathermy in the Treatment of Deafness. Believing that about 90 per cent of deafness is caused by obstruction of the eustachian tube, M. Coelst[1] has devised a method of treating these strictures by the topical application of a high-frequency current in the form of diathermocoagulation, which is the form of diathermy ordinarily used for surgical purposes. As a preliminary, the pharyngeal orifice is examined with the salpingoscope, and the length and diameter of the stenosis is ascertained by the passage of bougies. A eustachian catheter of insulating material is necessary—the author employs one made of ebonite—and a bougie of spring-steel about 0.3 mm. in diameter tipped with a small but-

(1) Bruxelles-Méd., July 3, 1927.

ton of solder. The nose and eustachian orifice are anesthetised by applications of stovain-adrenalin solution, and the indifferent electrode is applied to the lower part of the corresponding ear. The steel bougie is passed through the stricture and a current of 350 milliampères is turned on; after 3 seconds the bougie is slowly withdrawn through the stenosed portion of the tube during a further 6 or 7 seconds, after which the current is turned off. The ensuing reaction makes the patient deafer for a fortnight, after which he should have a further catheterisation.

The author says that the characteristics of the cicatricial tissue resulting from diathermy are suppleness, absence of retraction, and lack of any tendency to produce granulations or adhesions. He has treated 15 cases by this method, in all of which there had been no benefit from other forms of treatment. Two of the patients were lost sight of; but in all the remaining 13 the patency of the eustachian tube was re-established, this being confirmed after six months in seven of them, and after a shorter time in the remaining six. In 11 cases there was a very marked improvement of hearing, and the author claims that none was made worse; vertigo disappeared in one case and tinnitus ceased in three cases. Although all aurists will not agree that eustachian obstruction is the cause of 90 per cent of deafness, it is at any rate a fruitful source of this affection. If this method can be shown, on a large number of patients and with a greater lapse of time, to cure eustachian strictures and to be reasonably free from danger, a considerable advance will have been made in the treatment of a very common and distressing disability.

A Case of Unilateral Deafness Following Radiotherapy. J. Moeller[2] reports the case of a man, aged 74, who had complained for years of a slight impairment of hearing. On April 19 and June 8, 1920, he was treated at the Institute of Radiotherapy in Copenhagen

(2) Arch. internat. de laryngol., November, 1926.

for an epithelioma on the right side of the nose. He was seen by the aurist on August 4, when he gave a history of distressing vertigo and nausea following the first treatment, and a severe tinnitus. He thought that he had been completely deaf in the right ear for fifteen days. Examination showed that the drum heads were normal. Bone and air conduction in the left ear were practically normal; in the right ear, doubtful. The patient said that he heard the forks, Galton whistle, monochord, etc., with the left ear. Rotation to the right showed nystagmus to the left, 25 seconds. Rotation to the left showed nystagmus to the right, 5 seconds. Caloric test, cold, of the right ear, 25 to 30 seconds, showed marked nystagmus to the left, 2 minutes and 30 seconds.

The author believes that the patient may have had an old catarrhal condition of the right ear, as his history indicated; however, he thinks that the radiations caused a complete abolition of the function of the acoustic ear, but that there was a regressive course, as far as the function of the static ear was concerned. The author cites the experiments of Marx, who exposed pigeons to radiations. A histologic examination of the pigeons six months later showed a destruction of the crista, macula and the organ of Corti. The author believes that radiations to regions near the ears must be regarded as dangerous to the labyrinth.

The Nose and Throat

GEORGE E. SHAMBAUGH, M. D.

THE NOSE AND THROAT

General Considerations

Training in Otolaryngology. G. M. Coates[1] emphasizes that as the establishment of longer, full-time, systematic courses of graduate instruction under university auspices becomes more general, and as the certificate of the American Board of Otolaryngology becomes more generally recognized as indicating competence in the practice of the specialty, the old short time courses may be expected to disappear gradually and our standing as otolaryngologists to improve. Much otolaryngologic work will, of necessity, continue to be done by general practitioners and so-called specialists who have not had sufficient instruction and training; but the amount so done should become less and less as the years go by.

Shambaugh protests against the training of interns in operative technic without giving instruction in the basic branches of anatomy, physiology, pathology and diagnosis as applied to otolaryngology. The author is in entire accord with this view. The intern naturally is anxious to acquire what surgical skill he may and welcomes the chance to do tonsillectomies and septum operations, and there is great temptation thus to reward a faithful and hard-working intern. One must remember, however, that by being good natured in this respect he is adding to the very class that we are trying, by means of our work for higher education of the specialist and by the examination of our board, to eliminate. By contributing to the enlargement of this class of untrained specialists we are not safeguarding the best interests of the sick patient or the reputation of our specialty.

[One should never lose sight of the fact that by far the most important part in the training for special

(1) J. A. M. A., July 30, 1927.

work is that part which has to do with the building up of a background of clinical experience, to render one capable of making a proper diagnosis and of recognizing the indications for operative treatment. It is a much simpler problem to train one to do operative work. The old time, short postgraduate courses were instrumental in training too many men in the surgery of the nose and throat, who had no appreciation of when this surgery should be done.—Ed.]

Observations on the Reaction of Normal Nasal Mucous Membrane. D. R. Heetderks[2] reviews the literature on this subject thoroughly. In his own experiments ten persons in each of the first six decades of life were examined. The condition of the nose was determined for varying degrees of temperature and moisture.

The author's experiments showed that the nose has three definite functions other than olfaction: to warm, moisten, and filter the inspired air. The mechanism is the mucous membrane, the available surface of which is increased by turbinal turgescence. The nose reacts differently under various environmental conditions and at different ages.

Most noses show a fairly definite cycle of reaction. The following symptoms need not be due to pathologic conditions and can readily be examined as physiologic responses: Nasal obstruction in hot dry rooms, the watery nasal discharge in cold weather and during adolescence, the dropping back into the throat of secretions, often containing débris, and obstruction of the nose on the dependent side.

Effect of Camphor, Eucalyptol and Menthol on the Vascular State of the Mucous Membrane. Using the nasal plethysmographic arrangement described by Tatum, N. Fox[3] carried out a series of clinical experi-

(2) Am. J. M. Sc., August, 1927.
(3) Laryngoscope, August, 1927.

ments with these drugs. The recorded results show the following:

1. Menthol acts locally as an irritant to the nasal mucosa in dilutions as low as 0.5 per cent.

2. Eucalyptol and camphor have little, if any, local action on the nasal mucosa in percentages up to 5 per cent.

3. The action of menthol is purely local, producing a sensation of patency, due presumably to the stimulation of the temperature end organs, even though the concomitant resistance to air passages is actually increased.

[Clinical experience would hardly be in accord with the results of this investigation. Menthol in weak solution of oil, sprayed into a nose where the swelling of the mucosa, the result of an acute rhinitis, produces annoying symptoms of nasal obstruction, will almost invariably relieve the annoying symptom of nasal obstruction. If the apparatus used in these experiments fails to verify these conclusions, one would be justified in questioning the usefulness of the apparatus.—Ed.]

A Manifestation of Uremia in the Pharynx, Larynx, Trachea and Bronchi. Eleven cases showing a peculiar doughlike coating on the mucous membrane of the hypopharynx, larynx, trachea or bronchi have been observed by M. C. Myerson[7].

This phenomenon appears during the stage of the onset of uremia in those cases in which it makes its appearance.

It may occur in the oral cavity, pharynx, larynx, trachea or bronchi. It may occur in only one or all of these structures. The esophagus is also probably involved in some instances, but was not investigated.

When seen early, this coating is diagnostic of an impending uremia.

The presence of this coating in the trachea and bronchi may lead to physical signs which are mistaken for those of bronchopneumonia.

(7) J. A. M. A., Aug. 27, 1927.

No doubt tracheotomies have been performed because of the presence of a laryngeal or tracheal coating.

Vaccinotherapy in Otolaryngology. J. Daland[9] believes that it is all important to remember that the basic treatment of chronic infective tonsillitis is its complete surgical removal. Dental or sinus infection frequently coexists with chronic infective tonsillitis. If a vaccine is employed and an infected tonsil or remnant or other foci of infection remain, the beneficial influence of vaccinotherapy must necessarily be transitory, as the toxins or bacteria or both are continuously or intermittently entering the circulation.

In determining when vaccinotherapy is indicated, and the therapeutic results, the patient as well as the disease should be given full consideration.

Vaccinotherapy is of decided value, and in certain cases may save life. Failure of vaccinotherapy may be due: (1) To the bacteria or the strain selected for making the vaccine differing from that from which the patient is suffering; (2) because the vaccine is improperly prepared or unduly exposed to heat; (3) the dose or interval not having been accurately adjusted, or (4) the presence of an undetected focus of infection.

Hypersusceptibility to a small dose of autogenous vaccine may be due to an undetected focus of infection.

Streptococci in a secondary focus of infection, such as the joints, gallbladder or endocardium, may be so modified by the new environment that a vaccine made from the primary focus may be useless. The environment of the bacteria in the crypts of tonsils and the periapical regions of teeth differs markedly from that in the sinus or mastoid; while in the former the streptococcus hemolyticus or viridans predominates, in the latter it is the staphylococcus aureus or albus.

A healthy young adult, whose tonsil has been infected for a few years, usually makes a rapid recovery after

(9) Ann. Otol. Rhin. and Laryng., June, 1927.

tonsillectomy without a vaccine, although a vaccine would accelerate recovery.

Vaccinotherapy is especially valuable after tonsillectomy in those advanced in years, debilitated, anemic, emaciated or suffering from complications, such as diabetes, syphilis, tuberculosis, hepatic cirrhosis or advanced cardiovascular or renal disease, and vaccinotherapy may be of value by increasing the resistance of a patient who is a bad surgical risk and requires a tonsillectomy.

Anemia, leucopenia or lymphocytosis indicates that toxins or bacteria or both are being absorbed into the circulation and that immunity has been diminished or lost. This blood picture disappears permanently after the removal of all foci of infection and only temporarily if any focus is overlooked.

It is important to determine the identity and at times the pathogenicity of the bacteria in the crypts of tonsils causing systemic disease. If these bacteria grow freely in the patient's blood it indicates susceptibility, and vice versa.

The superficial parts of the tonsillar fossæ and throat normally contain streptococci, staphylococci and other micro-organisms. These bacteria may play no part in the production of symptoms.

In securing material from an infected tonsil for a culture or a vaccine, a platinum loop should be gently inserted into the mouth of a crypt and slowly passed to the bottom, as the materials in this region contain pathogenic bacteria. This material, promptly placed upon suitable culture medium, soon shows colonies of the predominating bacterium, which is usually the streptococcus hemolyticus or the streptococcus viridans, and occasionally these bacteria coexist. Sometimes the staphylococcus aureus, hemolyticus, the pneumococcus or some other organism is the one causing disease. Occasionally streptococci in one tonsil may differ from those obtained from a crypt in the other tonsil, or a streptococcus hemo-

lyticus may, after several months, be converted into a viridans.

Tonsillar crypts are sometimes sealed by adhesive inflammation, so as to prevent material being secured from the bottom of the crypt, so that a negative culture does not prove that a tonsil is not infected. Infra- and retrotonsillar abscesses cannot be diagnosed by culture.

It is important that the vaccine should be made with as few transplants as possible, as the streptococcus tends to lose its specificity and pathogenicity by many transplants or by long exposure to the air or heat.

It is well known that many normal mouths contain streptococci incapable of producing serious disease, and it is equally well known that the streptococcus of scarlet fever differs in its action upon the body from the streptococcus of erysipelas or measles or the streptococcus recovered from an infected tonsil. It is also generally admitted that the streptococcus hemolyticus or viridans retains its pathogenicity and specificity, if grown in the absence of oxygen. It is, therefore, easy to understand how important it is not only to properly obtain materials for culture but also to rapidly secure a sufficient growth with as few transplants as possible in making a vaccine.

In view of the extraordinary difference in selectivity and pathogenicity of various strains of streptococci, the making of a vaccine that exactly meets the needs of the patient necessitates unusual skill.

Undiagnosed Cough. From a study of two hundred patients W. C. Voorsanger and F. Firestone[2] come to the following conclusions:

1. Tuberculous lesions have not been demonstrated in guinea-pigs from inoculations of sputum free from tubercle baccili as determined by the smear method.

2. Infectious bronchitis and asthma must be recognized as a disease since it was found in 37 per cent. of the series. Its main etiologic factor is influenza.

(2) J. A. M. A., Oct. 1, 1927.

3. The prevailing organisms found in the infectious group are *Micrococcus catarrhalis, Streptococcus nonhemolyticus, Streptococcus hemolyticus* alpha and beta, *Streptococcus viridans* and secondary invaders, such as gram-positive diplococci and staphylococci.

4. The infectious group is amenable to treatment with an autogenous vaccine, approximately 10 per cent. of patients immunized having remained free of symptoms after two years.

5. Thirty-eight per cent. of the series with peribronchial and hilum thickening, enlarged bronchial rootglands or even fibrotic infiltrations in the lungs, particularly if basal, are in an undiagnosed group and must be given further study. Patients in this group must be considered as future subjects for either tuberculosis or bronchiectasis.

6. Careful physical and roentgen ray examination and sputum culture is recommended in all patients with cough persisting more than six weeks.

7. Beginning bronchitides should be studied as carefully as beginning tuberculosis. Such measures as injection of iodized oil and diagnostic pneumothorax followed by roentgenograms are of inestimable value in differentiating various pulmonary nontuberculous conditions.

Tissue Hydration and Its Relation to Susceptibility and Immunity, as Shown by Skin Tests in Asthma, Chronic Sinusitis and Other Infections. In addition to well recognized qualifications parasites must be capable of freeing water in the tissues. W. B. Wherry[3] suggests that interaction between the parasite and the host leads to the production of amines in susceptible individuals and that the resulting hydration of the tissues favors the growth of the parasite.

Such interaction occurs when heat-killed bacteria are injected intradermally into human beings. The response varies with the species of bacteria and with the

(3) J. Infect. Dis., September, 1927.

individual. The production of local urticaria, or this followed by immediate congestion, is taken to indicate susceptibility; when the whole process is greatly aggravated the next day, the reaction is taken to indicate sensitivity. Antigens so selected and given by the desensitization method yield excellent therapeutic results due to the production of opsonins and of a lessened tendency to tissue hydration.

The author reports a series of cases of asthma and chronic sinusitis treated by a vaccine made from bacteria to which the patient showed sensitivity.

Diathermy for the Common Cold. H. Bordier[4] describes a method of treating acute coryza by diathermy. The proposal was first made by Dr. Tsinoukas, of Athens, and the treatment aims at producing heat in the nasal fossæ sufficient to stop the excessive secretion of the mucous glands. Tsinoukas made use of two large Hegar's dilators (No. 26), applying them to the skin on each side of the nose. He claimed that even with a small current (200-300 milliampères) the most acute coryza could be stopped almost at once, so that after about 25 minutes the patient was cured; he could breathe freely, he ceased to sneeze, there was no discharge from the nose, and little by little any pain in the frontal sinuses disappeared. The best results were obtained if diathermy was used at the very beginning of the cold.

The author records the same success, but sought to devise more convenient apparatus. For the Hegar's dilators he first substituted spoon-shaped electrodes fixed to insulating handles; the patient comfortably seated in an armchair, held these handles for himself and applied them to the nasofacial angle. He now uses a nasal bipolar electrode. It consists of two metal plates, 1 mm. in thickness, fixed to the arms of a V made of an insulating substance, a joint at the base permitting adjustment of the plates to any nose. A terminal on each plate receives the electric wire, which should be supple and light.

(4) Paris méd., June 11, 1927.

Lastly, an elastic band round the head immobilises the apparatus once it is in place.

The advantage of the author's model is that it can be used without the patient's active help. The amount of current is increased until the patient remarks a sharp sensation of heat within the nose. It is to be noted that if the coryza is confined to one side of the nose, that is the side on which most heat will be felt, a fact which is explained by the higher tension of the current in the region of the diseased mucosa, following more abundant secretion from it. As the application continues with this amount of current, the sensation of heat becomes more and more painful, and current has to be diminished.

Cure of the coryza is indicated when the patient finds it difficult to bear the treatment. Afterwards, the transformation is complete, and no symptom of the cold remains, except a nasal intonation of the voice, persisting for a few hours, and due to congestion of the nasal fossæ. In most cases a single sitting is enough to cure the cold, but the result is better and more complete if the patient submits to two or three.

Focal Infection in its Relation to Medical Problems: Its Uses and Abuses. F. A. Faught[1] emphasizes the necessity of a thorough search for foci of infection as a prerequisite to the successful treatment of many cases.

The discovery of the relation of focal infection to many previously so-called constitutional diseases and degenerative processes is one of the great recent advances in medicine.

The opinion is expressed that the value of the removal of focal infection in the treatment of disease rather than being overdone is only just beginning to be appreciated.

Attention is called to the failure of some specialists, particularly dentists and rhinolaryngologists, to appreciate that a devastating focal infection may be present in the absence of demonstrable pus.

(1) Am. J. M. Sc., November, 1926.

Periodic health examination is valuable as a means of discovering unsuspected foci of infection.

Overconfidence as to the end-results of the removal of foci infection in the constitutionally defective individual must be guarded against.

The value of preparation and use of autogenous bacterins is discussed by the author and a method of preparing them and their administration is given.

Cases are cited to demonstrate:

1. The importance of the complete removal of all foci of infection.
2. The danger of multiple extraction of teeth.
3. The close relation of focal infection to gastro-intestinal diseases.
4. The influence of focal infection upon the thyroid gland and two cases reported which demonstrate that focal infection may influence the normal activity of the thyroid gland in either direction.

[There is no advancement in recent years that has created so much of a stir as the work of Dr. Billings on focal infection. It is not easy to evaluate clinical observations bearing on this subject. Because a person having rheumatic symptoms recovers after having unoffending tonsils and harmless teeth removed cannot be accepted as a result of these meddlesome operations, but mental processes are such that many people accept such evidence as conclusive. I knew a judge once who carried a rabbit's foot because he had recovered from an attack of rheumatism while doing this stunt and it seemed to him a complete conviction that the rabbit's foot was responsible. It may be a long time yet before we reach stabilized conclusions in this tremendously important problem of focal disease in systemic infection.—Ed.]

Diseases of the Upper Respiratory Tract in Relation to the Etiology and Treatment of Bronchial Asthma. The diseases of the upper respiratory tract which S. S.

Leopold and G. Fetterolf[2] have found present in many cases of asthma, and those which they consider of direct etiologic relationship are: (1) Infection of the paranasal sinuses, chiefly of ethmoids, sphenoids, and maxillaries, often associated with the presence of nasal polypi; (2) hypertrophy of the turbinated bodies, particularly of the middle turbinates, unilateral or bilateral, in firm contact, especially in their posterior portion, with the nasal septum.

Mullin's experimental work would seem to offer a logical explanation for the occurrence of bronchial asthma from infection of the paranasal sinuses. This author followed the course of a suspension of India ink from the maxillary sinus, downward along the lymph channels in the neck and into the chest. Irritation of the nasal ganglion, producing a reflex through the cervical sympathetic nerve, and thence through the vasomotor fibers of the bronchi, may explain the production of bronchial asthma from the presence of obstructive nasal lesions. In substantiation of this view, two patients have been observed in whom the passage of a nasopharyngoscope immediately produced an asthmatic paroxysm.

The present report comprises a group of 24 patients. In addition to disease of the upper respiratory tract, ten cases exhibited definite evidence of allergy (42 per cent.). All cases were operated and the after results followed in detail.

It is not to be expected that this small group of cases is of value from a statistical standpoint. However, certain general statements may be permitted.

Of the group, five expressed the opinion that they were cured; four have been free of recurrence from one and one-half to three years; twelve were improved; and seven unimproved.

Of the five considering themselves cured, four were of the reflex nasal type, three had bilateral turbinate hypertrophy, one had unilateral hypertrophy with septal

(2) Atlantic M. J., February, 1927.

contact. The remaining case, which is well at the end of two years, had bilateral turbinate hypertrophy and bilateral ethmoiditis.

Of the twelve patients improved, eight had obstructive nasal lesions; of these, two also had sinus disease. One had nasal polypi, and the remaining three in this group had extensive multiple sinus infections.

Of the cases unimproved, all but one had extensive disease of the paranasal sinuses. The remaining case had nasal polypi—suggestive evidence at least of sinus infection.

Summarizing these results, it may be said that patients with the reflex nasal type of asthma (unilateral or bilateral turbinate hypertrophy with septal contact), where this condition exists without concomitant disease of the paranasal sinuses, can confidently expect to be cured or greatly relieved by appropriate nasal surgery.

Those whose asthma is the result of infection of the paranasal sinuses have a much less favorable prognosis. Almost always the sinus infection is multiple, and usually the spheno-ethmoid cells are diseased. These facts mean multiple operations and difficult surgery, taxing to the limit the fortitude of the patient and the skill of the rhinologist.

Ethmoiditis with hyperplasia of the lining mucosa, the commonest form of sinus infection provocative of asthma, is extraordinarily difficult to cure, even by the most radical surgery consistent with the safety and welfare of the patient.

The authors are in accord with Mullin, who believes that when the sinuses are involved by hyperplastic processes, one cannot expect that any prolonged amelioration of asthmatic symptoms will follow any other treatment than the surgical removal of the hyperplastic tissue, with this reservation: that there is no known method of surgery capable of removing all hyperplastic tissue, especially when the spheno-ethmoid sinuses are extensively involved.

[This is a very timely discussion of one of the important clinical problems in rhinology. That asthma may be affected by nasal conditions and relieved by operative treatment is a clinically established fact but this relationship is not universal. The situation is something analagous to that of hay fever and abnormalities in the nose. The victim of hay fever, with the nose badly obstructed from other causes, may experience considerable relief having such obstructions properly corrected, but is not relieved of having hay fever. The hyperplastic ethmoid condition is the only nasal condition which is most frequently associated with asthmatic symptoms. Infection of the sinuses, ordinary suppurative sinusitis, is very rarely present in the asthmatic. The correction of the hyperplastic ethmoiditis surgically often relieves the asthma but it is rather exceptional that one is able to eradicate this process by operative interference. Usually there is recurrence in spite of the most thorough operations feasible and with the recurrence the asthma gets troublesome. Because of the favorable results occasionally encountered in such cases, rhinologists have often been over-hopeful about benefiting asthma in correcting anatomical variations, such as irregularities of the septum.—Ed.]

Relation of Asthma to Nose and Throat Surgery. A. Sterling's[3] personal experience is based on the analysis and thorough study of three hundred cases of bronchial asthma. Out of the three hundred cases, 129 patients, or 43 per cent., had trouble with the nose and throat which were considered by the patients, as well as by the family physicians, to be the causes of the asthmatic syndrome. The nature of the operative work done on the 129 patients was as follows:

Submucous resections	20
Tonsil and adenoid operations	45
Sinus operations and drainage	10

(3) M. J. & Record, Mar. 2, 1927.

Polyp operations (Seven patients had one or more polyp operations, two of these had five operations at about five or six month intervals).	24
Turbinate operations	8
Spur operations	8

This makes a total of 115 operations performed on 129 patients. Only three patients stated that they were free from asthma for two years following the operative intervention—two after polyp operations and one after a sinus drainage. In all the rest the operative work had no effect whatever upon the asthmatic paroxysms.

Although it may sound paradoxical, still it is a fact, that among those who have been operated on, there were some who had difficulty in breathing on account of nasal obstruction, but who did not have asthma until shortly after undergoing nasal operations. These patients have attributed their oncoming asthmatic trouble to the operation.

Of the 129 patients, 35, or 25 per cent., were positive to different pollens and to animal emanations. Some of them were positive to both. The nasal disturbance in all cases improved after the patients underwent proper desensitization treatments.

Of the remaining 94 patients, about 55 improved under general treatment, such as, hygiene and improvement in their mode of life, change of occupation with the addition of autogenous vaccine treatment. Fifteen of them had to undergo some cauterization either by electric cautery or by trichloroacetic acid, or a 10 per cent. silver nitrate, with additional autogenous vaccine treatment. The rest, 24 patients, gave up hope of getting improvement.

From a fairly large experience in the treatment of asthma, the author is impressed that nose and throat operations do not always stop asthmatic paroxysms, and the patients should be so informed. These operations sometimes do make the patient more comfortable, but

when it comes to assuring the patient that his asthmatic paroxysms will be stopped by the operative intervention, a physician should be guarded in making promises.

Nasal operations in vasomotor disturbances are practically a failure, unless measures are undertaken to improve the general health and the nervous system of the patient. In the inflammatory type, operations are many times helpful and perhaps may give the patient more relief and freedom in breathing, but it does not influence the eventual outcome of the asthmatic paroxysms, except in a few instances, unless desensitization treatment is also carried out.

[One might gather by a perusal of this work by Sterling that he sets out just as though he were doing pioneer work on the relations between nose and throat and asthma, that is, by carrying out an operation in every possible case and reaches the conclusion which one could easily gather from a perusal of the literature that most of these operations are without results. One wonders how many practitioners proceed in this way, ignoring or ignorant of the experience of rhinologists in the past. If every man practicing otolaryngology feels that he is authorized to try every operative suggestion, the public seems to be getting very little benefit from the previous experience.—Ed.]

House Dust in the Etiology of Bronchial Asthma and of Hay Fever. As a result of this study A. H. Rowe[4] concludes the following:

1. It has been shown that 42 per cent. of a series of 162 patients with asthma gave reactions to house dust extracts, and that 20 patients with perennial hay-fever also gave such reactions.

2. Dust reactions have been obtained in all age groups with the scratch test.

3. A large number of patients have a characteristic history of dust sensitization.

(4) Arch. Int. Med., Apr. 15, 1927.

4. The necessity of testing with a large number of stock and autogenous dust extracts is demonstrated.

5. Dust reactions may depend on one substance or on a summation of lesser reactions to several substances, such as animal emanations, orris root, pollens, and various fabric dusts, and that the possibility of an unknown specific substance in house dust is unlikely.

6. The data collected show that reactions to dust rarely occur without one or more other reactions to proteins commonly used in testing.

7. Desensitization to house dust extracts which give definite reactions in the patient is probably advisable in cases in which a marked history of dust sensitization is present.

A Rhinologic Study of Bronchial Asthma. Review of the literature by V. L. Bishop[5] has shown increasing development, during the past decade, in the study and treatment of the exciting cause of bronchial asthma.

Assuming asthma to be a symptom and never a disease, and for each case an underlying basis, the nature of which is unknown, recent studies of the exciting causes have developed distinct types, classifiable into two main groups: extrinsic, where the cause is outside the body, and intrinsic, where the cause is within the body. The intrinsic has been further divided into bacterial and reflex groups.

Extrinsic asthmas are not within the function of the rhinologist for study or treatment.

Intrinsic asthmas, comprising from 50 to 60 per cent. of all asthma cases, have been shown to depend largely upon lesions of the respiratory tract for exciting causes. The bacterial group, with foci in tonsils, teeth or bronchi, has been much written about by recent investigators, is quite generally understood, and has seemed to admit of little further discussion. The reflex group, perhaps less understood, has seemed to warrant a rather detailed review of the nerve reflexes involved, as offering the

(5) Ann. Otol. Rhin. and Laryng., June, 1927.

most logical explanation of a certain type of bronchial asthma that has repeatedly been observed to promptly and permanently disappear following the correction of causative sources of irritation within the nares, notably in hyperplastic ethmoiditis.

Rhinologic treatment of asthma has been productive of results directly, as it has been confined to intrinsic cases. Whether directed to the removal of foci of infection in the nose, throat and bronchi in bacterial asthma, or to the correction of nasal defects in reflex asthma, the results obtained have compared favorably with those reported from any other form of treatment. Results, such as herein reported, of 40 per cent. completely relieved, 56 per cent. improved, and only 4 per cent. unimproved, would seem to warrant the serious consideration, by rhinologists, of this problem of affording some measure of relief to the ever increasing number of patients afflicted with this distressing condition.

The Indications for Surgery in the Treatment of Hay Fever and Asthma. A decision as to the proper place of surgery in the treatment of hay fever and asthma should be based upon a consideration of the constitutional factors and nasal lesions underlying the symptoms of the individual patient.

Seasonal and perennial hay fever, uncomplicated by nasal lesions, are non-surgical diseases. A careful search will usually be rewarded by finding the protein offenders responsible for the symptoms.

Where protein sensitization can be demonstrated, no dependence should be placed on nasal surgery unless desensitization fails to relieve the symptoms.

S. H. Hurwitz* believes that infections of the upper and lower respiratory tract are important factors in the development of hay fever and asthma. Infection is the only demonstrable cause of symptoms in a large number of asthmatic patients nonsensitive to proteins on repeated tests.

(*) California and West. Med., August, 1927.

Where an infective focus in the nose, throat, or sinuses exists, appropriate surgical measures are justified to secure proper ventilation and drainage, regardless of whether the infection is coincidental or secondary to nasal allergy.

Frequently the allergic state is coexistent with nasal infection. Better results in these patients can be attained by desensitization combined with surgical treatment. In the diagnosis and treatment of this group the best interests of the patient will be served by the closest cooperation between the allergist, internist, and rhinologist.

In bacterial asthma surgical treatment is indicated only when an infective focus in the nose and throat drains bacteria-laden secretions into the larynx or trachea. Corrective surgical measures in such instances will help to improve the general health and vitality of the patient and make more valuable the results of general hygiene and vaccination.

Surgery has no place in the treatment of the patient with asthmatic bronchitis in whom no nasal anomalies or infections are demonstrable. Where it is carried out good results will rarely be obtained, and failure will only cause surgery to fall into disrepute.

The importance of the nasal reflex factor in asthma is as yet not well established. That it does play some part in causing symptoms is shown by the good results which at times follow the inhibition of this reflex by surgical means.

Nose and Throat Observations in Examination of Patients with Bronchial Asthma. In this series of cases P. S. Stout[6] found 20 per cent. of the patients had antritis; 16 per cent. had ethmoiditis, and 10 per cent. had frontal sinusitis. Of course many of these patients had two or more of these groups of sinuses infected.

That there is some relation between the infections of the cranial air cells and bronchitis is well established,

(6) J. A. M. A., Sept. 10, 1927.

but how much these infections influence the attacks of bronchial asthma is still a moot question.

The author found that 30 per cent. of the patients with bronchial asthma had one or more dark sinuses by transillumination, and 26 per cent. showed the same condition by roentgen ray. It might be noted that there was only 4 per cent. difference between transillumination and roentgen ray. Many of these patients did not give skin reactions and further study of many of the patients showing only slight or no skin reactions will probably reveal some focus of infection or abnormality as the cause of repeated attacks of bronchial asthma.

Of the infectious cases the author was able to follow up 77 per cent. In 15 per cent. there was no improvement; in 22 per cent. slight improvement; in 42 per cent. moderate improvement, and in 22 per cent. marked improvement.

The age of the patients ranged from 6 years to 60, and they were of both sexes.

Thus a goodly number received some benefit from the treatments, which consisted of:

1. Washing infected antrums under local anesthesia.
2. The use of suction (negative pressure), which has been a great help in diagnosis as well as treatment, especially in obscure ethmoidal and sphenoidal sinusitis cases.
3. Colloidal silver preparations in solution used as nasal packs, which were found quite beneficial.
4. Removal of anterior ends and occasionally posterior ends of turbinates in ethmoiditis, and sometimes more radical sinus operations on the antrums, found necessary to give relief and clear up purulent discharge.

Some of these patients were also referred to the Bronchoscopic Clinic for treatment. Infection of the sphenoid sinuses is more common than is generally supposed. With more accurate methods of diagnosis, including the roentgen ray, an increasing number are being found.

Of the patients studied, 24 per cent. had polyps in the nasal fossae. These polyps are frequently associated with sinus disease; they should be removed and the sinusitis treated. Great relief is experienced after their removal, and there is frequently a lessening of the attacks of asthma. In the cases in which they were removed, there was no improvement in 15 per cent.; slight improvement in 31 per cent.; moderate improvement in 43 per cent. and marked improvement in 11 per cent.

Polypoid degeneration of the mucous membrane of the nose and antrums is fairly common in bronchial asthma patients and, if excessive, should be removed. Further study of this condition will be made. The author would warn against too radical removal of tissue from the nose. A few cases of atrophic rhinitis (ozena) seen, were probably due to the removal of too much tissue from the nasal fossae.

Deviated septums and turbinates pressing against the septums are frequently seen, and whenever the patient's condition warrants it the septum should be straightened (submucous resection). Turbinates impinging against the septum must either be treated with the cautery or partly removed.

It would seem that any chronic diseased condition of the body would aggravate the attacks of bronchial asthma, but curiously enough the author has not found the beneficial results from the removal of diseased tonsils that might naturally be expected. About 60 per cent. of the patients had diseased tonsils at the time of examination. The author was able to follow up 77 per cent. of these. In 12 per cent. there was no improvement; in 23 per cent. slight improvement; in 45 per cent. moderate improvement, and in 20 per cent. marked improvement.

Of the 35 per cent. who had the tonsils removed the writer was able to follow up 80 per cent. In 12 per cent. there was no improvement; in 22 per cent. slight

improvement; in 34 per cent. moderate improvement, and in 32 per cent. marked improvement. In the final analysis, the difference in the results is not startling, but it is somewhat in favor of the removal of diseased tonsils.

Many patients have foul mouths. The author found 8 per cent. of the patients with positive roentgen ray pictures of diseased roots. Needless extraction of teeth is to be deplored, but in all patients with bronchial asthma the teeth should be carefully studied and infections cleared up. Gold crowns and bridge work should be carefully inspected by a capable dentist.

There were only a few patients that showed any ear involvement. Further study of these patients will be made. The conditions found were chronic suppurative otitis media, polyps in the external canal, and mastoid tenderness.

The Use of Ephedrin in Bronchial Asthma and Hay Fever. In a series of fifty-nine cases of asthma and eleven cases of hay fever studied by S. S. Leopold and T. G. Miller[7], it was found that:

1. Ephedrin produced complete temporary relief in 56 per cent. of the cases of asthma and 63 per cent. of the cases of hay fever.

2. In asthma the best results were obtained in the allergic and reflex nasal cases (84 and 100 per cent., respectively), and least satisfactory results were obtained in the infectious group, although even in this series a sufficient number obtained complete temporary relief (38 per cent.) to justify its trial.

3. Of all the patients with nasal obstructions (three reflex nasal cases and nineteen allergic ones), 86 per cent. were completely relieved.

4. In addition to producing bronchial dilatation, ephedrin orally administered produces contraction of the nasal mucous membrane.

5. The oral administration of ephedrin in cases of

(7) J. A. M. A., June 4, 1927.

hay fever has advantages over its local application in the nose in that the local irritating effects can thus be avoided and in that, for the patient, it is a simpler method of administration.

Uses of Ephedrin in Rhinology. According to C. C. Merkel[8] ephedrin is an alkaloid and the active principle of the Chinese plant ma huang. Chemically, the drug. compared with epinephrin, contains an extra methyl radical and an absence of a phenolic hydroxi group. The drug may be obtained in the alkaloidal, chloride and sulphate forms. There are three varieties of the plant —American, Chinese and German. The author has used the Chinese variety and considers the chloride the most satisfactory. The strengths of solution used were 1, 2, 3, and 5 per cent. The solution keeps well at room temperature and a 3 per cent. solution is not decomposed by boiling.

Ephedrin was used by the author as: (1) spray; (2) topical application; (3) a cotton pack. A pack left in situ for three minutes causes no more contraction. The drug was used both in infants and adults. From his experience with the solution the author concludes that:

1. Ephedrin is a safe drug in the treatment of nasal disorders.

2. Its advantages over epinephrin are its quicker and more sustained action and the absence of secondary relaxation.

3. Its use is justified to produce ventilation and drainage of the nose and accessory sinuses.

4. It is stable and no tolerance develops following its use.

The Therapeutic Value of Ephedrin in Rhino-Laryngology. S. Taylor[4] sums up his experience with this drug as follows:

(8) Laryngoscope, March, 1927.
(4) Texas State J. Med., August, 1927.

1. Ephedrin hydrochloride relaxes the bronchial musculature and raises the blood pressure.

2. It is effective in overcoming congestion of the nasal mucous membrane.

3. It is more advantageous than epinephrin, in that its action is more permanent; it does not irritate, and it can be administered orally.

4. It is a valuable adjunct in the relief of hay fever.

5. It will stop the great majority of cases of asthma when given orally.

6. It is also valuable in the treatment of acute coryza and sinusitis.

7. Ephedrin is not a curative drug, but it is very effective in alleviating the attacks of hay fever, and it will certainly prove of benefit to a suffering asthmatic.

Ephedrin and Cocain Synergy. In experiments carried out by E. L. Ross[5] cocain was slowly introduced into the circulation of dogs; the minimal lethal dose was established, and the rise in blood pressure determined. Under the same conditions, cocain and ephedrin were injected and the same factors measured. Still another group of animals was given ephedrin, and after the action had subsided, cocain and ephedrin were injected as in the second series of tests. The minimal lethal dose was determined for cocain and for cocain and ephedrin injected intraperitoneally into cats that had not been anesthetized. The conclusions are as follows:

1. Ephedrin and cocain do not act synergistically on the blood pressure like epinephrin and cocain.

2. Ephedrin does not increase, but decreases the toxicity of cocain.

Tutocain: A Local Anesthetic in Rhino-laryngology. From his experimental and clinical studies with tutocain, O. D. Cunningham[6] arrives at the following conclusions:

(5) Arch. of Otolaryng., June, 1927.
(6) Laryngoscope, November, 1926.

A. Animal experimentation with tutocain, as compared with cocain and novocain, shows:

1. It is 4.5 times less toxic than cocain.
2. It is 2.7 times more toxic than novocain.
3. It is approximately three-fifths more powerful than cocain for surface anesthesia.
4. The toxic symptoms are essentially those of cocain and novocain.

B. Comparative clinical use of tutocain shows:

1. A 5 per cent. solution in 1:10,000 adrenalin is a satisfactory substitute for 10 per cent. cocain for the surface anesthesia in the removal of tonsils.
2. A one-fifth per cent. solution is a satisfactory substitute for .5 per cent. novocain for infiltration in the removal of tonsils.
3. A 5 per cent. solution in 1:10,000 adrenalin is a satisfactory substitute for flake cocain and adrenalin in most intranasal operations.
4. It is less satisfactory than cocain flakes and adrenalin for submucous resections because of the tendency to bleed.
5. It is somewhat slower than cocain and novocain in producing equivalent anesthesia.
6. It is superior to cocain in its relative freedom from toxic by-effects.

Stovain in Otorhinolaryngology. For about a year F. Muecke[7] has been testing stovain as a local anesthetic for operations on the nose, throat, and ear, in accordance with the request of the Cocain Research Committee. On the whole it has proved very satisfactory indeed.

In 50 cases of cauterization with the electric wire anesthesia with 5 per cent. stovain was employed. The operation was quite painless; the drug produced less vasoconstriction than cocain; there were practically no systemic effects and no toxic symptoms, and there were less after-effects than with cocain, which gives a certain

(7) Brit. M. J., Sept. 25, 1926.

feeling of "cold" afterwards. For cauterization stovain had all the good qualities of cocain without the bad ones.

In fifteen turbinal operations 10 per cent. stovain was employed. The operation was painless, but there was more bleeding than with cocain, though this could be controlled by mixing with adrenalin. There were no toxic effects, but the patient was more apprehensive, cocain tending to diminish the dread of the operation. Thus stovain, though quite satisfactory for these cases, was less so than cocain.

In ten septum operations 10 per cent. stovain was used mixed with 1 in 2,000 adrenalin. The mucous membranes anesthesia was equal to that produced by cocain, but the deeper bone was more painful. There was more bleeding, but no toxic effects. The "buck-up" effect of cocain was greatly missed. Stovain was thus not so satisfactory as cocain for this major operation on the nose. In operations for nasal polypi and ethmoiditis the effects were just the same as in the septum operation.

Generally, with regard to stovain anesthesia in the nose the author's experience has been that it is perfectly safe, and the surface anesthesia is excellent; it is perhaps better than cocain for purely mucous membrane work; the anesthesia is slower and the vasoconstriction less; but it is on the whole not so satisfactory as cocain for the major operations.

Twenty operations about the mouth and throat were performed under 1 per cent. stovain. It seemed perfectly safe, there were no toxic effects, and the anesthesia was good. There was very little vasoconstriction. For these cases it is much preferable to the injection of cocain; but it is not preferable to novocain.

In twelve cases the tonsils were removed under 1 per cent. stovain. The anesthesia was good, but there was much more bleeding than with novocain, and it was therefore not so satisfactory for this operation.

As a laryngeal spray for performing minor opera-

tions the author used a 5 per cent. solution of stovain, with excellent results in the three cases—one a papilloma and two foreign bodies.

On the whole, therefore, he considers that stovain should have as big a place in the use of local anesthetics as cocain and novocain, more especially in minor throat and nose operations.

Barbital as a Preventive of Cocain Toxicosis. For a number of years J. Leshure[8] has administered to all patients requiring operation under local anesthesia morphin either alone or in combination with atropin or scopolamin. In spite of this precaution, a considerable number of these patients have exhibited symptoms of poisoning, such as pale, cold, clammy skin, rapid and feeble heart action, and convulsive tremors.

During the last year the author has substituted for these drugs diethyl barbituric acid (barbital) or its sodium salt (sodium barbital), with the result that none of the 100 patients so treated have manifested any of the symptoms mentioned above, and the natural inference is that barbital is an efficient antidote to cocain, procain hydrochloride and other similar drugs used to induce local anesthesia.

This inference is strengthened by the results of animal experimentation carried out by Tatum, Atkinson and Collins in the laboratory of pharmacology of the University of Chicago. Their report demonstrated that the preliminary intravenous administration of sodium barbital and paraldehyde increased the tolerance of dogs to cocain to the extent of about 400 per cent.

It has not been found necessary in average cases to use the intravenous method, and the author administers from 6 to 12 grains (0.4 to 0.8 gm.) of sodium barbital by mouth at least one-half hour before inducing anesthesia. This is best given in 3 grain (0.2 gm.) capsules followed by a glass of water to hasten absorption; the dose is regulated by such factors as age and weight.

(8) J. A. M. A., Jan. 15, 1927.

Clinically, barbital alone appears to be as efficacious as when combined with paraldehyde, although for intravenous use the latter drug would be of considerable value.

[It is gratifying to see the careful studies that are being made on the drugs used for local anesthesias. Cocain in intra-nasal work seems still to be the most satisfactory, but one has always got to be guarded in the use of this drug, especially in intra-nasal work. I have for years used a solution not stronger than 5% and got just as satisfactory results as when I used 20%. In operations around the ethmoid, one is much more likely to get toxic effects than when operating on the septum, a clinical fact which I daresay most operators have observed.—Ed.]

Inactivation of Epinephrin by Certain Colloidal Silver Preparations. To lessen secretion, usually in acute nasal infections, epinephrin is often used locally, either alone or in combination with various supposedly antiseptic solutions, notably of the silver protein preparations. As the majority of the silver preparations in solution liberate silver ions, it would seem that they might inactivate the epinephrin, as epinephrin and other alkaloidal compounds are destroyed by many metallic salts. The investigation reported here by J. D. Pilcher[9] was undertaken, therefore, to determine the duration of the action of epinephrin in such silver compounds.

Epinephrin decreases nasal secretion, probably by lessening the circulation through local vasoconstriction. As vasoconstriction is readily determined by local blanching of the skin when epinephrin is introduced into the skin by scratching, this method was chosen to determine the epinephrin activity. For nasal application, epinephrin is commonly used in a strength of 1 part of the 1:1,000 solution to 3 or 4 parts of the silver preparation, making roughly a 1:4,000 solution of epinephrin. For the purpose of this investigation, it was

(9) J. A. M. A., Mar. 5, 1927.

used in a dilution of 1:4,000 and 1:1,000, the latter strength for comparison, although it seems not to be used in practice. The epinephrin was mixed with solutions of the silver preparations and the mixture was tested at suitable intervals until blanching of the skin failed to appear.

The author's results show that certain members of the organic silver compounds: protargol, argyrol and solargentum, in the commonly used solutions, inactivate epinephrin within a few hours; therefore, if the local effect of epinephrin on the nasal mucous membranes is desired, it should not be used in combination with these substances or the mixtures should be freshly made. Neosilvol and silver nitrate solutions inactivate epinephrin more slowly.

A Plea for Conservatism in the Treatment of Optic Nerve Disturbance from Focal Infection. L. E. White[1] believes it is usually possible to find the focus of infection and by eliminating it, before the nerve is damaged, to obtain prompt recovery. Nasal obstruction when well marked should be removed. As the posterior sinuses are rarely infected it is unnecessary to open them except in a few desperate cases. Papers advocating exenteration of the ethmoids and sphenoids, even when they show no definite infection, are to be condemned. The benefit following the opening of the sinuses would naturally occur about that time, although some of it might be due to the depletion of the structures adjacent to the nerve. As sufficient pathology was not found in the sinuses to account for these optic nerve disturbances more distant foci were sought. The removal of infected teeth and tonsils soon proved to be the most effective method of treatment. Infection is now believed to come from either some systemic condition, as influenza or intestinal toxemia, or from some definite focus in teeth, tonsils or sinuses. This infection travels by way of the blood stream and produces a neuritis of the optic

(1) Laryngoscope, May, 1927.

nerve. Eliminate it from the blood stream and the neuritis subsides.

The prognosis is dependent upon the duration and extent of the loss of vision, the condition of the fundus, the virulence of the infection and the size of the optic canals.

About 85 per cent. of the cases would recover under conservative treatment, such as local medication and the removal of some definite focus. These cases are usually taken too seriously. Extreme measures are instituted where little or no treatment would suffice, and while recovery may take place in spite of, rather than because of, radical operative procedures, the patient is submitted to a needless risk.

In the remaining 15 per cent. where one is contending with a severe neuritis with marked or complete loss of vision, it is usually advisable, in addition to the removal of the focus, to also remove the middle turbinate and open the posterior sinuses.

Teeth should be studied by an expert odontologist, devitalized ones especially.

Negative pressure in the sphenoid would favor the migration of bacteria and toxins from the blood stream to the optic nerve, a condition similar to that which takes place in the tympanum in Bell's palsy.

A definite focus was found in 53 of the 60 unreported cases. The tonsils appeared to be the only focus in 17, the teeth in 14, and the antrum in two. Teeth and tonsils either alone or combined was considered to be the focus in 70 per cent. In but six cases were the ethmoids involved and even in these there was also infected teeth, tonsils or antrum. The frontal and sphenoid were each involved but twice. The removal of the focus was followed by normal vision in 50 per cent and marked improvement in 25 per cent. Much better results would have been obtained had the focus been removed earlier.

[This is a rational logical statement of an important situation. The attitude which some would have us take,

that sinus conditions exist which are undiagnosable and still capable of producing an optic neuritis, is not a very comfortable position for the rhinologist. To conclude, moreover, that any results which may happen to follow an operation where no tangible evidence of sinus trouble existed either before, after or at the time of the operation, would only throw the bars down on indiscriminate operating which in the case of the sinuses is a much more serious matter than the indiscriminate removal of tonsils. A toxic neuritis of the optic nerve from infection is much more likely to develop from focal infection rather than direct extension of sinus trouble to the nerve trunk, a fact which seems to have been overlooked by the enthusiast for sinus operations.—ED.]

Rhinological Findings and Treatments of Cases of Retrobulbar Optic Neuritis. M. J. Gottlieb[2] divides the management of cases of retrobulbar optic neuritis into expectant and operative treatment. Unless haste is essential, the patient should have a blood Wassermann examination, radiograph of the nasal accessory sinuses and of the optic canals. The teeth should be thoroughly examined by the dentist. If the optic canals are large there is no necessity for hurry and the patient may recover without surgical intervention. White believes that the disease, in cases where the canals are large, is not due to direct extension, but from absorption of toxins or bacteria from diseased foci, such as chronic purulent disease of one or more of the nasal accessory sinuses, diseased tonsils or teeth.

Palliative treatment has not been practised in this country because of the fear that the patient would go blind and a valuable opportunity for curing the patient, lost forever.

The rational procedure for the handling of a case of retrobulbar optic neuritis palliatively, would be to give the patient a brisk cathartic, shrink up the tur-

(2) New York State J. Med., Dec. 15, 1926.

binates with adrenalin and cocain, followed by suction. This may be supplemented by tampons containing some of the silver albuminate salt. The giving of a series of injections of autogenous vaccines may be undertaken. This management should be given in conjunction with an ophthalmologist who must see the patient daily so as to determine the condition of the optic nerves and serve as a safeguard against continuing this treatment when the patient is getting rapidly worse. In such an event prompt surgical measures should be applied.

The surgical treatment consists of a thorough removal of all possible ethmoid tissues and breaking down the anterior wall of the sphenoid cavity. The middle turbinate should be removed for it has been the author's experience that the outer surface of the turbinate will in a certain number of cases adhere to the orbital plate of the ethmoid and reproduce the same conditions which obtained before the operation.

The author has seen nine cases of retrobulbar optic neuritis. Eight of these were bilateral and one unilateral. When the affection is on both sides, both ethmoids and sphenoids should be broken down. The procedure can be done at one sitting. This practice is contrary to that of some excellent rhinologists. The unilateral case which was observed by the writer, was one wherein at some time previous a piece of cotton, accidently left by another physician, was jammed between the middle turbinate and the septum. On the day scheduled for operation the patient sneezed out the cotton and the optic neuritis promptly cleared up.

Usually within eight or twelve hours after the operation, the patient finds that the vision has improved, and continues to improve. In a certain few, the vision continues to diminish after the operation and then suddenly veers around and the recovery is uneventful, but prolonged.

[The conclusion one seems to gather from this paper is, that if conservative methods are not entirely suc-

cessful, operate upon the sinuses. We fail to get any discussion pointing towards the recognition of sinus trouble before an operation is undertaken. We feel that it is extremely improbable that a sinusitis may exist capable of producing a neuritis of the optic nerve where an experienced rhinologist, assisted by *x*-ray plates, is not able to make a definite diagnosis of the presence of this trouble before operation.—Ed.]

Treatment of Encephalitis Lethargica by the Removal of Possible Etiological Factors. G. Eden and A. L. Yates[3] suggest that the infection in encephalitis lethargica is a symbiotic process, that in the first place the nasal mucous membrane is damaged by one of the catarrhal group of organisms, and that subsequently the virus of encephalitis is inhaled, passes through the damaged mucous membrane, and thus enters the tissues, reaching the brain possibly by the perineural lymphatics.

In support of this there is a fair amount of evidence that for the transmission of the disease from one individual to another the virus encephalitis lethargica must fall on mucous membrane previously altered by inflammation of such a character that its power of absorption of fluids in contact with it is greatly increased.

The initial damage to the nasal mucous membrane is generally remediable by treatment, and if remedied it would appear that the virus of encephalitis cannot pass into the tissues, and patients become more susceptible to treatment by drugs.

Nasal treatment aims, not at curing encephalitis lethargica, but at preventing admission of fresh virus into the tissues. In those cases where actual destruction has occurred in the central nervous system (a system in which regeneration is impossible) the most that can be claimed for washing out the nasal sinuses is that further irreparable damage is hindered, and in many cases appears to be prevented.

(3) Brit. M. J., Apr. 16, 1927.

The Parkinsonian gait and posture is rarely completely removed without the use of remedial exercises.

The Thymus Gland. As the thymus is supposed to play a part in the condition known as "status thymicolymphaticus," and as such subjects have large thymuses, the roentgenogram should then play an important part in the diagnostic procedure. Certainly, all overweight children should have the benefit of a roentgen ray examination, and it is essential in those of average weight. W. W. Wasson[4] considers it less necessary in those who are underweight. It must also be remembered that the finding of a small thymus on one examination does not mean that a small thymus will be seen in future examinations, and the author knows of no way to safeguard a child except to make a roentgen ray examination before any operation. It has been his experience that in subjects with thymuses measuring more than three times the width of the thoracic vertebra, the operation should be considered dangerous, but the mere presence of a thymus should not be considered a contrary indication. He personally fears operating on children over 2 years of age who have large thymuses. The aid in diagnosis gained by physical examination is valuable and necessary.

It is now the custom with the authors and with many institutions to recommend treatment by irradiation for certain large thymuses. This, of course, is rather empiric and is based on the experience of finding large thymuses when sudden death has occurred. Irradiation by radium or the roentgen ray will reduce the size of these thymuses, and also it seems that after such treatment the patients may be operated on with less fear of sudden death. Many patients are treated indiscriminately when a roentgenogram may by chance show a large thymus.

Under 2 years of age, it is advisable to treat only those patients with large thymuses in whom an operation is necessary, or when the infant may be having some symp-

(4) Arch. Otolaryng., December, 1926.

toms which are definitely due to a large thymus. The author has seen patients under 2 years of age treated by irradiation when a roentgenogram happened to show a moderate-sized thymus. When other errors in diagnosis are made, such as a diagnosis of bronchopneumonia with gurgling, the treatment is sometimes that given in thymus cases. Occasionally, it may be necessary to treat an infant for thymus when all the clinical symptoms point to a thymus but none is demonstrated. This may be due to a misplaced thymus. These cases must be unusual. In a number of patients treated at varying ages, the writer has observed no ill effects. It should be noted that in treatment by irradiation there is only a relative reduction in the size of the gland, and all of its tissue is not removed. All the precautions necessary in gland therapy about the chest should be exercised.

The author concludes that:

First, the thymus gland in infants under 2 years of age can be accurately portrayed on the roentgenogram in a high percentage of cases.

Second, in the infant under 2 years of age the thymus is variable in size, not only in different types of infants but in the same infant at different times. These thymuses may be classified as to size, and it is found fairly definitely that underweight infants have small thymuses and that those overweight have large thymuses, while the average weight infant usually has a moderate-sized thymus but does not adhere so strictly to the rule.

Third, there is an increase in the thymus from birth to 1 year of age, which then reduces in size, with certain exceptions, when the infant is from 28 to 32 months of age.

Fourth, treatment by irradiation will reduce the size of the thymus, but should be used only when there are definite indications of enlargement.

[The condition of enlarged thymus is an important consideration for the laryngologist. Enlarged thymus is pretty likely to be associated with lymphatic enlarge-

ments about the nasopharynx, a condition which is readily recognized and where operative treatment is urgent.—Ed.]

The Pathologic Examination in Cavernous Sinus Thrombosis. As a result of a study of eight definite cases and with necropsy on all but two of these, O. J. Dixon[5] comes to the following conclusions:

1. Ordinary and trivial infections are usually the primary foci (lip, tonsil, teeth).
2. Some form of trauma is usually associated with these primary infections.
3. The thrombosis takes place by direct extension of the thrombophlebitis.
4. The offending organism is most frequently the staphylococcus.
5. The temperature is sustained and gradually increases, and there is usually an absence of chills.
6. Meningitis follows so closely after the eye symptoms develop that septic thrombosis of the cavernous sinus is a nonsurgical complication.
7. Reported recoveries were probably errors in diagnosis.
8. Meningitis and septicemia do not satisfactorily explain the rapid termination.

The Use of Foreign Bodies in Ear, Nose and Throat Surgery. According to H. L. Pollock[6] foreign materials, such as gold, silver, vulcanite, plaster of paris, decalcified bone, paraffin and celluloid have been tried in plastic surgery about the head and have all been discarded by ethical surgeons.

Ivory, in the author's experience thus far, is an ideal material to use as a framework in plastic surgery and is superior to either bone or cartilage. It is, however, still too early to make definite assertions as to the permanency of results from the use of this material in plastic surgery, though the writer feels much encouraged by the reports

(5) J. A. M. A., Oct. 2, 1926.
(6) Ann. Otol. Rhin. and Laryng., June, 1927.

of German colleagues, which leads to the belief that one need not fear the absorption or loss of these implants.

Utilization of Skin of the Upper Eyelid for the Repair of Small Facial Defects. While the availability of grafts of free skin of full thickness from the eyelid for repairs about the orbital region is generally recognized, it is possible that their suitability for certain repairs and corrections beyond that area is not so well known. J. E. Sheehan[8] states that the fact that in a series of forty-eight such operations forty-six were immediately successful suggests the desirability of inviting attention to the advantages of the method.

The prime recommendation of the graft from the eyelid, as compared with other grafts of full thickness, is the assurance that it will "take," a merit it possesses in exceptional degree. A second advantage is that the skin of the lid, if normal in color, matches the skin of the face better than that brought from a distance. Third, the reorganization after healing is so complete that after a few weeks the borders of approximation actually cannot be identified, either at the place of repair or on the lid from which the graft has been taken.

These advantages are obvious when there is question of ectropion of the upper or the lower lip; a distortion at the angle of the mouth; loss of skin on the nasal ala, the columella or the cover of the nose; small burns, whether from acid, lye, radium or fire; "port wine stain," hairy moles or small depressed scars, or lagophthalmus caused by some cicatricial contraction.

The single important contraindication is the relatively excessive pigmentation sometimes observed in the skin of the eyelid. This condition is not so frequently found in persons with fair skin as in those of the brunette type.

The extent of individual replacements in practice is greater than at first thought might be supposed. The sound upper lid can part with a large proportion of its covering of skin without injury, nearly half the width

(8) Arch. Otolaryng., August, 1927.

(in fusiform excision) by three-fourths of the length. Healing of the approximated edges of skin leaves no visible scar, thus conforming to the first principle of constructive reparative surgery, namely, that no new disfigurement shall be made if avoidance is possible.

Facial Reconstructive Surgery: With Presentation of Cases and Lantern Slide Demonstration. J. Maliniak[6] believes that the field of facial reconstructive surgery is growing rapidly, as its value becomes evident to the medical and public opinion. Prophylactic measures in this field will avoid unnecessary deformities. As a rule, nasal deformities have to be corrected by the endonasal route.

Skin, cartilage and fat are the best transplants to be used in facial reconstruction. Paraffin is to be condemned, as all other inorganic substances. Ivory, as a dead organic substance similar in structure to bone, has its indication, as a substitute in some instances.

Aged and flabby facial skin can be surgically corrected in women for professional and social reasons. A thorough rhinological and general surgical training, together with some artistic inclinations, are necessary requirements for this work.

The author presents numerous illustrations of typical cases in this field of plastic surgery.

[Unfortunately, plastic surgery is usually practiced by quacks under the name of beauty doctors, so that unnecessary and often defacing operations are indulged in. The unfortunate victims shrink from the publicity of bringing malpractice suits, so the beauty doctor usually goes scotfree, irrespective of baleful results.—Ed.]

The Nasal Aspect of Headaches. The diagnosis of acute inflammations of the sinuses is relatively simple according to J. C. Braswell[7] and can be made from the history, intranasal inspection, trans-illumination and

(6) Laryngoscope, March, 1927.
(7) Ibid., May, 1927.

x-ray. In chronic inflammations of the anterior ethmoids, frontals and maxillary sinuses, the diagnosis is usually simple. In the posterior ethmoids and sphenoids the problem is more complex and it is frequently necessary to apply all means of examinations at our disposal. Cocainization of the nasal ganglion does not relieve pain from a lesion in the sphenoid sinus, but it may be relieved by cocainization of the sphenoid sinus. Due to the wide variation in the interpretation of pain in this area, one is justified in proceeding with caution in an effort to determine the character, type and location of pain presented for diagnosis. Due to the illuminating work of Sluder one is prone to err in the diagnosis of a simple local lesion as the direct cause of pain, whereas further study will often furnish evidence of sufficient weight to class the pain as purely functional. The so-called psychoneurotic type presents pains of various types and only diligent study, combined with all of the mediums at hand, will definitely determine the correct diagnosis. Cooperation of the internist and neurologist is essential in cases of this type.

Headaches resulting from anatomic variations in the nose causing pressure contacts are by no means uncommon. Pressure headaches resulting from deviations or thickening of the posterior part of the septum or enlarged turbinate occur with frequency. The cause of such contacts may be traceable to acute inflammations or external irritants. The vacuum headache described by Sluder necessarily falls under this type. In many instances marked pressure contact is present in the nose without any evidence of pain and the logical deduction is that the local condition is only a factor in the cause of pain.

New growths in the nasal cavities may be the cause of pain; however, malignant conditions of the sinuses frequently reach the inoperable stage without the slightest manifestation of pain. It is by no means uncommon to find the nasal cavities filled with polypoid growths

of such size as to materially interfere with breathing and phonation, and absence of pain prove to be an outstanding feature.

[The fact that pain is a conspicuous symptom in some cases of sinus disease has led many superficial observers to the conclusion that headache is an indication of some sinus or nose trouble. As a matter of fact, most sinus diseases run their course without headache and most headaches have nothing to do with sinus trouble. We are rather skeptical regarding headaches being caused by nasal variations producing contact between septum and outer nasal wall as we are regarding the whole theory of vacuum headaches. That vacuum may be produced, particularly in the frontal sinuses, by occlusion of the naso-frontal duct is readily accepted, but that such a vacuum can be the cause of persistent headache is questioned since vacuum must necessarily be very shortly relieved by the cavity being filled with transudate.—Ed.]

Diseases of the Nose

Nasal Accessory Sinuses

Iodipin in the Diagnosis of Nasal Sinus Conditions. H. M. Goodyear[8] presents the accompanying roentgenograms (Figs. 21, 22) from a series of nasal sinuses injected with iodized oil. The antrums were injected through the inferior meatus using from 2 to 6 c. c. of the warm iodopin. It was found that moist pledgets of cotton placed in the middle meatus helped to retain the solution. The sphenoid sinuses were injected through the anterior wall with from 2 to 4 c. c. of the oil. Injection of the frontal sinus was not satisfactory.

The author believes that the definite shadow cast by the oil is an aid in diagnosing sinus conditions, especially in cases with uncertain histories of sinus infection and when lavage yields no return of secretion.

(8) Ohio State M. J., February, 1927.

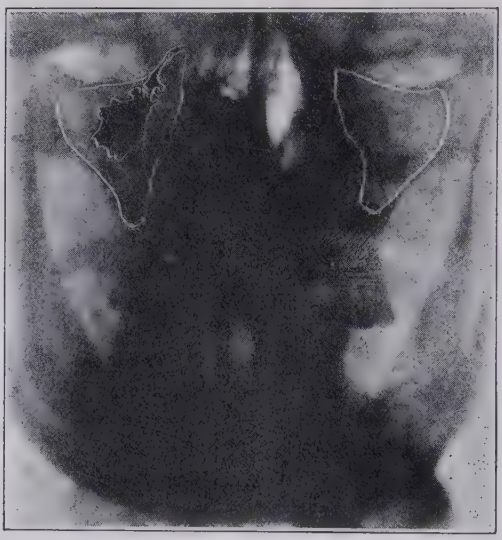

Fig. 21.—Front view of the left antrum from a patient with chronic bronchial cough of ten years duration; the irregular outline produced by the cystic membrane should be noted (Fig. 22).



Fig. 22.—Cystic membrane from antrum shown in Fig. 21.

[The remarkable variations in the contour of nasal sinuses would seem to make it very difficult to interpret roentgenograms of the sinues filled with an oil to indicate the evidence of pathological conditions.—Ed.]

The Injection of Iodized Oil Into the Sinuses, with Special Reference to the Technique in the Sphenoidal Sinuses. Injection of radio-opaque substances for radiographic purposes are indispensable methods of diagnosis in various branches of medicine and surgery. Since iodized oil has been introduced to the profession, sinuography is assuming the popularity it rightly deserves. Iodized oil possesses physical and chemical properties which make it very suitable for the sinus mucosa.

The sinuses can be filled either by injecting the oil through the ostia or by puncturing one of the walls. The puncture method, according to A. Lobell*, has greater accuracy and is very successful in the maxillary and sphenoidal sinuses.

The sinuologist should inject the sinuses in the *x*-ray laboratory just as the urologist does in pyelography. To prevent the escape of the oil from the sinus, the minimum time should be spent between injection and *x*-ray exposure. Sinuography is of indisputable value in the study of the morphologic variations of the sinuses. The surgeon, the student and the teacher will find it of equal importance.

In conjunction with radiography, this method will prove its value as an auxiliary agent in diagnosis of obscure conditions. It is no substitute for radiography because it is not infallible. The evidence submitted suggests that the oil has some therapeutic value in certain types of sinusitis. It offers an unprecedented opportunity for closer cooperation between the sinuologist and the Roentgenologist than exhibited heretofore.

The Catarrhal Inflammation of the Nasal Accessory Sinuses and Its Diagnosis. This report by O. Hirsch[9]

(*) Laryngoscope, July, 1927.
(9) Ibid., January, 1927.

is based on a case of recurring nasal polypi. Irrigation of the antrum revealed no secretion, yet in spite of this the author performed the radical sinus operation and found the antrum filled by transparent edematous mucosa hanging from the walls in polypoid ridges (Fig. 23). The edematous mucosa was removed and on examination it had a histological appearance similar to nasal polypi.

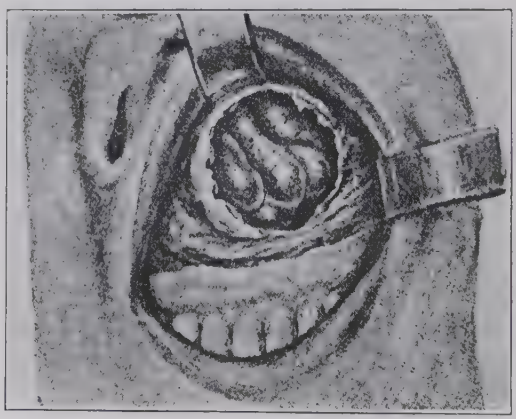

Fig. 23.—Chronic catarrhal antral inflammation. The sinus is filled by edematous convolutes. (Drawn during Hirsch's operation.)

The author believes this case and the results in fifteen subsequent cases bring out certain facts:

1. There is a form of antral inflammation in which one finds an edema of high degree without suppuration.

2. There is a similarity in the histology of the edematous antral mucosa, and nasal polypi.

3. A comparison between the mucosa of the antrum in cases of choanal polypi, and in relapsing nasal polypi, shows that there are two forms of catarrhal inflammation of the antral mucosa; (a) a form capable of involution (the more common); and (b) a form incapable of involution. In the latter form cord-like structures o'

mucous membrane result and these prolapse into the nasal cavity giving rise to either ordinary or choanal polypi.

The author mentions the *possible subsidence of nasal polypi, after the removal of chronic catarrhal antral mucosa.* The subsidence occurred in a few cases only, in those with cord formation, and also in two cases without cord formation. In three other cases the polypi had shrunk. The nasal polypi in all cases operated on by the author showed prior to operation a great tendency to recur, but after operation there have been no recurrences, with the exception of two cases. The recurrence in those two cases occurred in cavities which had not been operated on.

The author concludes, from the invariable connection between chronic catarrhal inflammation and recurring nasal polypi; from the identical histological characters of nasal polypi and chronic catarrhal antral mucosa; from the involution of nasal polypi in some cases after removal of the diseased antral mucosa, that recurring nasal polypi are the results of chronic catarrh of the mucous membrane of the accessory sinuses. On the other hand, one can conclude, from the presence of recurring nasal polypi, that a chronic catarrhal inflammation of an accessory sinus is present. The antrum will be found most often the seat of suppurative disease, as found in all the writer's cases, but *he does not regard the antrum as the only source* of recurring nasal polypi, as all the other sinuses may give rise to similar polypi when their mucosa becomes the seat of a chronic catarrhal disease.

The author believes that just as the reappearance of pus in the nose, after it has been wiped away, signifies suppuration of a sinus, just so does the recurrence of polypi denote the diagnosis of chronic catarrhal sinus disease. However, not all cases of catarrhal inflammation give rise to polypi or have symptoms. The *x*-ray is usually reliable, but there are a few cases that will escape diagnosis.

A point in pathology which the author noted in operating the antrum through the canine fossa was the extreme thinness of the bone in these cases. He is of the opinion that the chronic catarrhal inflammation is accompanied by bone resorption.

[The fact that the mucous membrane lining the antrum may undergo polypoid degeneration exactly as that lining the ethmoid cells, is not surprising. That the recurring polypi in the nose are usually dependent upon an antrum condition seems hardly to be expected any more than one should expect the antrum polypi to disappear by degeneration of the ethmoid. Where the nasal polypi spring from the antrum and hang pedicled from the osteo-maxillary, the exenteration of the membranes of the antrum should put an end to recurrences, but it does not hold that an operation upon the antrum, even when it is full of polypi, will prevent the ethmoid to continue to form nasal polypi. The harmless, usually symptomless course of polypoid degeneration of the membranes of the antrum renders the radical operation for their removal hardly a desirable procedure.—Ed.]

New Antrum and Frontal Rasps. The probe point frontal rasp (Fig. 24), was designed by R. G. Reaves[1] for intranasal operations. The probe point is so small that it will enter the same sized opening that a silver probe can enter, thereby enabling the physician to obtain an entry to the frontal opening, in most cases without forcing an instrument blindly through the floor of the frontal sinus. When the instrument has entered the opening it is gently manipulated, and the floor about the opening is broken down until the larger blunt pointed rasp, or the W. P. Reaves frontal punch, can be inserted. The teeth of these rasps are fine and sharp and cut away the edge of the floor instead of tearing it. The instruments are designed to remove as much of the floor as possible without destroying a large part of the mucosa about the nasofrontal duct. This is accomplished

(1) Arch. Otolaryng., April, 1927.

chiefly because the instrument is small, with a short rasping surface, fine cutting teeth and a delicate sense of touch which is imparted through the instrument. The author has been using the probe point frontal rasp for six years, and feels that it is one of his most valuable instruments. He uses the angle biting forceps (Gruenwald's) to remove as many tags of tissue as possible about and below the opening. This technic has enabled him to obtain results in most cases without resorting to radical (external) operations.

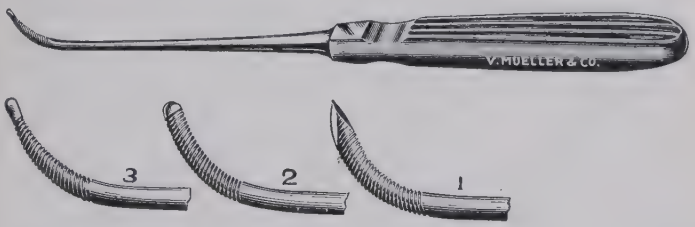

Fig. 24.—New antrum and frontal rasps used for intranasal operation; *1*, the antrum rasp; *2*, the blunt point frontal rasp; *3*, the probe point frontal rasp.

The antrum rasp was designed to enter the antrum so that a biting instrument could be inserted and the edges of the opening smoothed off after the biting instrument had been used. The rasp is small enough to enable one to enter almost any antrum, even that of a child. The rasping surface is short so that when it is properly handled the mucosa is not removed from the inferior turbinate and the inferior meatus. The teeth, which are fine and sharp, cut instead of tear. The instrument is not designed to be used alone for the operation, but can be used for this purpose better than most of the rasps on the market.

[Intranasal technic for securing proper ventilation and drainage of the sinuses, particularly the frontal and maxillary, will, we believe, always remain the method of choice for most of the cases of sinus disease. In the case of the maxillary sinus all that is required is to

cut a large enough opening to secure ventilation when the process clears up of itself. In the case of the frontal sinuses the same holds true. With a sufficiently large intranasal opening all frontal sinus symptoms disappear, including the symptom of pain. Even in those cases where there may continue to be some discharge the patient is probably relieved from the menace of any likely intra-cranial complication, and is better off if left alone rather than be subjected to a radical, external operation which at best is more or less deforming.—Ed.]

Infections of Accessory Nasal Sinuses: As a Cause of Chronic Nontuberculous Bronchitis. F. B. Kistner's[2] experience consists of a series of 196 cases referred as chronic nontuberculous bronchitis. In all but 6 of these he was able to demonstrate a definite chronic sinus disease. Of the 190 positive sinus cases, 164 had had their sinuses operated upon or had been treated a sufficient length of time to judge with some accuracy the effect that treatment of the sinuses has had upon the bronchitis. The ages ranged from 4 to 71 years, the great majority being between the ages of 20 and 50. The shortest duration of the bronchitis was 7 months, the longest 18 years, and this in a young woman 24 years of age.

The author divides these cases into three classes:

1. Those in which there is a slight chronic catarrhal discharge from the nose and nasopharynx and an irritative cough, occasional expectoration with slight variable signs, especially clusters of moist râles in the base of one or both lungs.

2. Those who have frequent exacerbations of a latent sinus disease, followed by acute diffuse bronchitis going on to the chronic stage.

3. Those who have definite purulent discharge from the nose, perhaps with odor and the typical picture of bronchiectasis, unloading large quantities of purulent secretion at each postural drainage.

(2) Northwest Med., April, 1927.

In most, if not all of these cases, the author believes that the relation between the nasal and bronchial lesions is a definite causal one, and that close cooperation between the chest man and the rhinologist will usually reveal the accessory sinuses as the seat of an established infection and the source of the bronchial disease.

Sure as one may feel of the causal relationship between sinus and bronchi in these cases, the author does not feel that one is in a position to be dogmatic. Also, other parts than the sinuses may easily be the source of infection of the lung. The route from the teeth as well as from the tonsil takes the same general direction. However, the writer is here chiefly concerned with a class of cases, in which one can prove a definite sinusitis to bear the weight of suspicion as source of the bronchial disease.

It can justly be urged that cure of the sinus disease does not always result in cure of the diseased lung. This depends upon how far the secondary lesion has progressed. If the bronchial infection is in an incipient stage, cure of the sinus, thereby removing the source of bronchial reinfection, will often result in complete recovery. While the results in those cases falling in class three are disappointing from the lung standpoint, they are by no means negative for the individual.

In the series of 164 cases here reported the results have been uniformly good and in many cases brilliant. The extent of relief depends upon the degree of pathologic changes in the lungs and upon the ability to cure or control the infection in the sinuses.

A number of cases have been cured by conservative treatment, such as antrum lavage. This is particularly true in children; but the great majority had one or more operations upon the sinuses, and the best and quickest results have followed surgery along radical lines.

[One can really accept as a fact that bronchial conditions are often associated with sinus trouble, but it

is not so easy to accept the conclusion that the sinus trouble is dependent upon sinus disease. The two probably take place simultaneously and are not part of a general infection of the respiratory tract. The genuine enthusiast for the theory brought out in this discussion, seems willing to interpret as evidence of the sinus infection slight clumps of mucous which appear in the washing of the irrigation. Such mucous may readily come from the nasal cavities themselves. Genuine bronchiectasis with purulent secretion may, of course, be associated with a chronic empyema of the sinuses. Such cases call for operations upon the sinuses irrespective of the bronchial condition and it is not to be expected that the bronchial condition is capable of recovery in such cases, even though one accepts the view that the origin of the bronchiectasis was from the sinuses.—Ed.]

Paranasal Sinus Infection and Swimming. F. E. Hasty[5] has observed that as a group the sinus infections resulting from swimming are often severe in their nature, and that the ethmoids and frontals are frequently involved. Children especially are likely to pick up infections in pools. The author has seen a number of boys who got sinus infection from one pool as a result of being required to "duck" their heads. Without an exception every boy recovered in the course of a few weeks after they ceased swimming.

Persons who have previously suffered from paranasal sinus infection or nasal obstruction are very likely to develop acute attacks following swimming. The high percentage of frontal and ethmoidal infections is due to virulent foreign bacteria reaching the vulnerable part of the nose, and to a lowered local and systemic resistance. An overdose of foreign bacteria of marked virulence for which the individual does not have previous immunity is a probable explanation that quite likely holds true in children.

(5) J. A. M. A., Aug. 13, 1927.

Man's lack of adaptability to aquatic life is really quite apparent, and, if asked the direct question, perhaps all intelligent persons would frankly state that man does not possess the particular apparatus which would make him capable of behaving in the water in the same way as aquatic animals. Our knowledge, however, does not determine our conduct in this instance, for throughout the length of time man has indulged in swimming either through necessity or for sport or self-exploitation in the accomplishment of aquatic feats.

The final question is, What shall otolaryngologists do to protect their patients?

"Shall we continue as individuals to warn them against the hazards of swimming, or shall we as a group condemn swimming for those at least, who are not capable of appreciating the warnings that should be posted about every pool? I dare not alone answer the question for the entire profession."

Relation of Inflammation of Maxillary Sinus to That of Nose and Other Paranasal Sinuses. It is the belief of J. D. Heitger[6] that the maxillary antrum is the most frequently involved of all the nasal sinuses. Polypi in the meati bear the same relation to chronic catarrhal disease of the sinuses emptying therein as the presence of pus in these areas to suppurative sinus disease.

Secondary or recurring polypi are more frequently encountered than the primary type. Recurring polypi with negative results from antrum puncture may indicate chronic catarrhal inflammation of the antrum.

Recurring polypi are the objective symptom of chronic catarrhal inflammation of the accessory sinuses and suggest involvement of the antrum or other nasal sinuses. The most frequent point of origin of recurring polypi lies in the antrum and not as was formerly considered in the ethmoid.

Polypi are present in the ethmoid capsule, because the pathway from the antrum leads past the ethmoid.

(6) South. M. J., August, 1927.

[It should be kept in mind that the antrum, like the frontal sinus, is an outgrowth from the ethmoid and the membrane lining these cavities can be expected to be subjected to the same changes as those that involve the membranes lining the ethmoid cells.—Ed.]

Diagnosis of Chronic Maxillary Sinusitis; Comparative Value of Roentgenographic and Physical Observations. In this series of examinations of 300 patients with maxillary sinusitis, H. P. Johnson[3] found 127 cases in which clinical observations and roentgenograms were both positive. Investigation of the sinus by puncture showed positive results in all but three of the 127 cases; of the three with negative results, the ethmoid was involved in one, and the frontal sinuses in two. There were 23 cases with positive clinical but negative roentgenographic evidence. Investigation revealed that in seventeen patients the sinuses contained thick mucus or mucopurulent clots and in three pus. The maxillary sinus was normal in two cases of anterior ethmoiditis and in one case of frontal sinusitis.

The cases with positive roentgenograms and negative clinical observations are probably the most difficult in which to make a diagnosis of a sinus infection. Ninety such cases were seen, and a diagnostic puncture of the sinus was made on the roentgenographic observations alone. The sinuses were proved positive in only fifteen of these, which included seven cases of cystic sinus and two in which it was possible to observe the nose but once before exploratory puncture, so that a careful diagnosis was not made clinically. The six remaining cases were those in which the clinical observations in the nose were negative by the usual methods of diagnosis, possibly due to an error in technic.

A diagnostic puncture of the maxillary sinus was made in sixty cases with normal clinical observations and negative roentgenograms. These sinuses were all proved negative except one, which was cystic and con-

(3) Arch. Otolaryng., April, 1927.

tained a thin bloody fluid. There were eight cases in which a cystic maxillary sinus was revealed by exploratory puncture; in seven the roentgenograms of the sinuses had been positive, and all in the clinical observations had been negative.

There are several factors in certain cases which make a positive clinical diagnosis difficult: (1) the sinus may have emptied its contents immediately before examination; (2) the content of the sinus may be of such consistency that suction will not aspirate it through the ostium, and (3) there may be some mechanical obstruction to the ostium of the sinus, such as a polypus or a hyperplastic middle turbinate.

A maxillary sinus was regarded as negative, and further investigations were not made when the clinical observations and exploration did not show a discharge. It was considered that any nonsecretory pathologic change would not be detrimental to the patient's health, and that operative interference was not indicated. This, however, does not apply to tumors and malignant lesions.

Besides chronic inflammation, there are several normal and pathologic factors which modify a roentgenogram of the maxillary sinus: (1) the angle of exposure; if the petrous portion of the temporal bone is projected in line with the sinus, it will appear cloudy; (2) age of the patient; in the young the size and shape may be misleading before the sinus has fully developed, and in the aged the density of the bone is increased; (3) sex, as the bony walls of the maxillary sinus are usually thicker in men than in women; (4) asymmetry in certain cases; (5) previous operations on the sinus which may result in a thickening or a thinning of the mucosa; (6) tumors involving the sinus or the region around it, and (7) foreign bodies in the sinus or close to it.

Ninety-two per cent. of the cases in this series could be diagnosed by means of the clinical data alone; in 67 per cent. of the cases a diagnosis might have been made from the roentgenographic observations, while 98

per cent. were diagnosed from the clinical and roentgenographic observations combined. As evidence of diagnosis, negative roentgenograms were found to be 10 per cent. more reliable than positive roentgenograms. Eighty-seven per cent. of the cases with cystic maxillary sinuses were diagnosed by roentgenograms, while none could be diagnosed from the clinical observations.

Interpretation of the roentgenogram is of most value when made by the rhinologist who is familiar with the clinical observations in the particular case.

Almost 19 per cent. of the diseased maxillary sinuses could be traced to extension of dental infection.

From the investigation of 300 maxillary sinuses, it would seem that a diagnostic puncture of this sinus is justifiable when there is any suspicion regarding its condition. This is the only means of making a correct diagnosis. When the history or complaints of the patient are such that disease of this sinus must be ruled out, an exploratory puncture can be made without hesitation, regardless of the roentgenograms or the clinical observations.

In this particular group of cases there were not any untoward results from a diagnostic puncture and washing out of the maxillary sinus.

[A timely discussion bringing out essential features of the relative importance of various methods of examinations to establish sinus disease. We accept the author's conclusion that the sinusitis that cannot be demonstrated by irrigation of the sinus is not likely and possesses no factors which are of sufficient menace to the individual to justify an operation. We feel that as regards the maxillary sinus a simple method of procedure leads to a diagnosis. If the transillumination tests show the sinus perfectly clear, one can feel relatively sure that the skiagraph will also show the same result and that negative findings on irrigation can be expected. In those cases where the sinus walls are anatomically thick, as in some males especially, transillumination may leave

one in doubt, even where the skiagraph will clear up the diagnosis. Ordinarily where one feels in doubt after transillumination, simple irrigation can be carried out with a more satisfactory conclusion than relying upon the skiagraph and save the patient the unnecessary expense of having a plate made.

In regard to the frontal sinuses the situation is as follows: When transillumination gives entirely clear sinuses only feel sure that the skiagraph has nothing to add. Very often the transillumination leaves one in doubt. In these cases the skiagraph is of great value. Naturally, it is more difficult to get a satisfactory conclusion from the skiagraph than it is from irrigation. We very often have the experience of a patient bringing a plate from outside where a diagnosis has been made of sinus disease, when a properly made skiagraph arrives at a quite different conclusion. A poorly made skiagraph can never be relied upon.—Ed.]

Chronic Frontal Sinusitis: Surgical Treatment. E. G. Gill[8] describes his own technic for chronic frontal sinusitis as follows:

The incision and mode of approach are similar to the method described by Killian in his paper published in 1903 in the *Archiv f. Laryngol.* It is made through the unshaven brow. At first the incision extends about one inch and is extended if the sinus is found to extend much beyond this limit. Cross-cut incisions are made to insure even approximation of the suture line. Particular care is made not to disturb in any manner the periosteum over the orbital arch. The periosteum over the anterior wall is gently elevated. It should not be elevated the slightest distance beyond the upper or outer limits of the sinus. The fact that periosteum does not readily reapply itself to bone has been strongly emphasized by Lynch and others. To secure obliteration, the anterior wall in its entirety must be removed. Every vestige of mucous membrane is thoroughly removed.

(8) South. M. J., August, 1927.

The sinus is swabbed with iodin and packed with cotton moistened in adrenalin. The incision is now extended in a curved manner over the orbito-nasal angle. Thus far the procedure is similar to Killian's.

The treatment of the periosteum covering the floor of the sinus and inner wall of the orbit differs in that the author does not disturb the attachment of the superior oblique muscle or the lacrimal sac, nor does he expose or remove the entire floor of the sinus. Enough of the floor is removed to admit a rubber tube about one-fourth of an inch in size. An opening of similar size is made through the lower edge of the nasal and upper part of the lacrimal bone. The ethmoid cells, if they have not been previously removed, should be removed at this time. A rubber tube, one-fourth of an inch in diameter, is now brought through the nose. The distal portion is in the sinus. The tube is left in position for one week. A probe is passed through daily in order to promote drainage. The wound is closed with either metal clips or dermal sutures, which are removed on the fourth day. A pressure bandage is worn until the sinus is obliterated. This is the most important feature of the after-treatment. No intranasal treatment other than cleansing the nose is required.

The cosmetic result is not to be dreaded if a broad orbital arch is preserved. Furthermore, cosmetic results should not be the chief consideration in a life-saving operation.

The author concludes that:

1. Radical operation upon the frontal sinus is indicated in cases of chronic suppuration that will not respond to intranasal surgery.

2. The mortality in uncomplicated cases is very low, provided the operation is performed by one who is thoroughly familiar with the anatomy of the frontal sinus and its adnexa.

3. Any operator who fails to interpret his own roentgenograms is inviting disaster sooner or later.

4. If complete obliteration is to be accomplished, a pressure bandage over the anterior wall must be applied and during this time the fronto-nasal opening must remain patent.

5. Following the technic described diplopia has been avoided entirely.

Indications for the Radical Frontal Sinus Operation with a Report of Cases. This paper by R. T. Atkins[4] is the result of a review of the histories of 42 patients, on which the radical frontal sinus operation was performed personally.

The term radical frontal sinus operation, as used by the author, implies the Killian operation, which has for its object the obliteration of the frontal sinus and removal of the adjacent ethmoidal cells.

The cases have been arranged in the following groups:

Group I.—Operation urgent because of alarming symptoms. This group includes the cases complicated by intracranial or orbital involvement. As a rule these are acute cases of very marked virulence or acute exacerbations of chronic cases in which the bony walls of the frontal sinus have been softened or necrosed by prolonged suppuration.

Group II.—Operation not urgent, but the indication positive. This group includes cases due to:

1. Failure of intranasal treatment and operative measures to relieve (a) distressing symptoms such as headache, local tenderness, recurring edema of the upper eyelid; neuralgic pain; fever and discharge (b) frequent acute exacerbations which incapacitate the patient; (c) persistent foul discharge.
2. Fistula.
3. Recurrence following previous operations.
4. Cysts and mucoceles.

Group III.—Operation exploratory. Doubtful indications because of uncertain diagnosis. This group in-

(4) New York State J. Med., Jan. 1, 1927.

cludes new growths, orbital tumors simulating frontal sinus involvement and frontal sinusitis as a possible source of focal infection.

In the series of 42 cases, six were operated on immediately because of intracranial complication. There were five brain abscesses, one of which was accompanied with cavernous thrombosis, and one meningitis. All of the cases also had orbital involvement consisting of exophthalmos, chemosis of the ocular conjunctiva, limitation of movement or fixation of the eyeball and swelling of the lids. Three were acute cases with no history of previous attacks, and three were acute exacerbations of a chronic process. All six cases complained of severe headache and had a high temperature.

There were eleven cases operated on because of the urgency of orbital complications. All showed swelling and edema of the lids, exophthalmos, chemosis, and in one case, there was gangrene of the conjunctiva. There was limitation of movement of the eyeball in six. All showed some temperature reaction, and in five cases it was septic-like in character; one case later developed a metastatic abscess of the hip. Headache and severe pain were common symptoms. Necrosis of bone occurred in all but two cases, involving principally the floor of the frontal sinus, and in one case, the author was obliged to remove a large part of the floor of the orbit because of necrosis. The anterior and posterior walls were both involved in one case, which disclosed an epidural abscess. Ethmoidal and antral involvement occurred in all of the cases.

Seven were acute in onset (less than three weeks) and four were acute exacerbations of a chronic process.

In the second group there were ten cases operated on because of long standing suppuration, associated with frontal headache, tenderness, and in some cases swelling and edema of the soft parts about the orbit. The histories varied from eight months to twenty-five years.

All were incapacitated for work during the attacks and were left in a weakened condition after the acute stage had passed. In some cases the headache was almost continuous.

All had intranasal treatment which did not relieve or prevent recurrences.

There were four cases which showed fistula or sinus formations. Two followed an incision of a localized abscess about the orbit, and two followed the spontaneous rupture of an abscess. All of these cases had well marked signs and symptoms of frontal sinus involvement, and on probing, necrotic bone could be felt.

There were four cases operated on secondarily, because of failure of the primary operation to affect a cure. In all of these cases the indications were very apparent.

In the third group there were six cases, especially interesting because of the doubtful nature of the pathology. Operation was, therefore, exploratory.

[The author states very fairly the indication for radical external operation in frontal sinusitis. He has presented quite a formidable list. A very small number of such must come to the personal experience of a single individual. It should be stated that most cases of frontal sinusitis with a definite diagnosis are not cases that come within this group which the author is discussing, that is, the group which requires external operations.—Ed.]

The Local Administration of Bacterial Vaccines in the Treatment of Subacute and Chronic Nasal Sinus Conditions. According to H. Hays[5] cultures for the treatment of sinus conditions can be easily made and broth vaccines prepared from them in any well equipped laboratory. The vaccine is applied on long pledgets of cotton, packed into the nares and allowed to remain for twenty minutes. This has not the disadvantage of hypodermic injections, which is a particularly difficult

(5) Laryngoscope, November, 1926.

procedure with children. The vaccine is never applied to the mucosa until it is first thoroughly cleansed.

In the majority of cases, the vaccine can be applied to the mucosa of the nose near the sinuses affected with the exception of the antra, into which the vaccine can be injected directly. There is a possibility that the vaccine may have a specific effect in certain cases of malignant growth. This vaccine differs materially from the usual vaccine, in that it not only contains all the bacteria from the diseased part, but the by-products of these bacteria and the chemically changed broth in which the growth took place.

At the end of the eighth treatment, which means at the end of the fourth week, the patient ought to notice a decided improvement or cure.

[This method of treating sinus disease does not impress itself very strongly upon us. Vaccine therapy for infections of the respiratory tract has been rather extensively exploited. One field has been to protect patients from recurring head colds. Because a patient happens to have a period of freedom from head colds after vaccine therapy, it is no evidence that the vaccine therapy had anything to do with the phenomenon. Patients usually experience no difference whether they have, or have not, subjected themselves to vaccine therapy for head colds.—Ed.]

The Treatment of Antral Disease by Simple Tube Drainage. From a study of 230 cases R. E. Mercer[6] concludes:

1. That as far as these records go, a large proportion of antral cases are not secondary either to disease of other sinuses or of the teeth.

2. That simple drainage and aeration are effective in curing 85 per cent. of all cases, and if the ones that were not followed up are omitted, instead of being classed as failures, about 94 per cent.

(6) Ann. Otol. Rhin. & Laryng., March, 1927.

3. Asthma, ten cases only; antral disease is very rarely a causative factor, and antral operative work is of little value in relieving.

4. Bronchitis; antral disease may be of a causative factor in some obscure cases, and antral drainage may be curative.

5. The antrum may be a source of focal infection in rheumatism, but few cases, less than 5 per cent., of antral disease complain of rheumatism. In those that do an operation may have decided value.

6. Postnasal dropping may be caused by antral as well as by other sinus disease, and operative treatment may give relief.

The advantages of the tube drainage are:

Over repeated punctures, permits constant aeration and drainage is less painful for the patient and less troublesome for the operator.

Over window opening, permits home treatment and is rather more simple.

Persistent use of the tube will render a radical operation unnecessary in a great majority of cases. This is true not only in chronic purulent antral disease, but also where there is hyperplasia of the antral mucosa.

There were no untoward symptoms from or following the operation in any case; no air was injected; the operation is simple and safe.

[It is the exceptional antrum situation that cannot be properly handled by the intranasal route. Window resection, with or without tube, is the goal to be obtained. Postnasal dropping may be noticed as a symptom in some antrum diseases. Most antrum diseases, however, do not produce this symptom and it may be stated as a clinical fact, that most cases of postnasal catarrh have nothing to do with sinus trouble, a fact which every rhinologist should ponder over before reaching a conclusion, that: because a patient has postnasal catarrh, he must, therefore, expect to find some sinus involvement. We know of some who would diagnose

obscure ethmoid trouble, because of the presence of postnasal catarrh. Such men are among those who find themselves guilty of a great many unnecessary operations.—Ed.]

The Intranasal Ethmoid and Frontal Sinus Operation. The technic for these operations as described by W. Spielberg[7] is essentially that of the Halle flap intranasal operation. The author reports eleven cases where the antra and ethmoids were operated on, and nine with the frontal sinus operation in addition.

From his experience the writer believes that the intranasal ethmoid and frontal sinus operations described are the operations of choice as compared with the other operations in vogue at the present time for the following reasons:

1. It preserves the middle turbinate bone and leaves the nasal mucosa in as normal a state as may be possible, whereas the middle turbinate is sacrificed in part or whole, and a good deal of the surrounding normal nasal mucosa destroyed in the other methods used.

2. Injury to the cribriform plate, anterior cranial fossa and olfactory nerve filaments is practically made impossible.

3. By constructing the mucoperiosteal flap and preserving the middle turbinate, postoperative scarring, dryness and crust formation, as well as the long drawn out course of postoperative treatment is avoided.

4. It is at times difficult to tell postoperatively whether or not an operation has been performed, so little damage is done to the nasal structures.

5 It opens up a route for entering the frontal sinus, giving it sufficient drainage without risking postoperative complication frequently the result of intranasal sinus surgery.

6. The intranasal frontal sinus operations should always be done first, before the external operation is at

(7) Laryngoscope, February, 1927.

tempted, as the majority of cases will get well without any further operative procedure.

[We can concur in all of the conclusions expressed by the author.—ED.]

Local Anesthesia in External Operations on the Nasal Accessory Sinuses. The principal object of this paper by R. Harris and W. L. Simpson[8] is to present a routine for external operations on the nasal accessory sinuses, principally the frontals, the ethmoids and the sphenoids. This procedure has been developed by gradually weeding out the little details found bad and holding on to and adding such as were thought good. Careful attention to matters which might be, and often are, lightly passed has proven of much value in final results.

The preliminary preparation of the patient for such an undertaking, as radical operations on the frontals, the ethmoid and the sphenoid of one side, under local anesthesia, is most important. As to medication, one of two regular plans are employed. In one hospital where only male patients are handled, ¼ gr. of morphin sulphate and 1/200 gr. of hyoscin hydrobromide are given in 2 c. c. of 25 per cent. magnesium sulphate solution one-and-one-half hours before the time set for the operation, and ⅛ gr. of morphin sulphate with 1/200 gr. of hyoscin hydrobromide in 2 c. c. of 25 per cent. magnesium sulphate solution 15 minutes before the patient leaves for the operating room. At other hospitals the patient is given morphin sulphate grains ⅛ in 2 c. c. of 25 per cent. solution magnesium sulphate one-and-one-half hours before the operation. In 20 minutes after the first dose, morphine sulphate gr. ⅛ and atropin sulphate gr. 1/200 are given in 2 c. c. of 25 per cent. solution magnesium sulphate. A third dose is given the same as the first 20 minutes after the second.

With either plan the patient is placed in a darkened room two hours before operation. A tactful nurse is given in charge. No visitors are allowed. The patient

(8) Laryngoscope, April, 1927.

is not allowed to talk, and can usually be persuaded to keep the eyes closed. The nurse's job is an important one, but she will not fail you if time is taken beforehand to explain just what is necessary, and why. When the stretcher arrives the patient is lifted on to it and a towel is placed over the eyes. The operating room is ready, no instruments are in sight, but the patient's eyes are kept covered and he or she is gently and quietly lifted onto the operating table. If quiet is had the first 20 or 25 minutes ordinary conversation by the surgeon and assistant is not noticed by the patient. Occasionally the patient sleeps at intervals during the operation.

The whole face is painted with 5 per cent. solution of mercurochrome, sterile towels are placed so that the breathing is free and easy. The inside of the nose is swabbed with a mixture of adrenalin chloride solution 1:1000, one part, and 4 per cent. cocain hydrobromid, two parts, then with 1 per cent. mercurochrome solution. Then the side of the nose to be operated on is packed with a strip of gauze wet with the above described cocain-adrenalin solution.

Twenty c. c. of novocain solution is placed in a medicine glass. Twelve drops of fresh adrenalin chlorid solution 1:1000 is added. Care is taken to inject no other than this solution; 15 c. c. is usually injected. Special attention is paid to injection of the lachrymal sac region and supra-orbital nerve region. Injection is made all along the line of expected incision, that is along the margin of the orbit and the side of the nose. The incision may be made six or eight minutes after the injection is finished. The bleeding will be surprisingly little, one or two bleeding points usually have to be caught, and occasionally require tieing. For ordinary chronic pansinusitis, the Lynch incision is used. In elevating the periosteum injection of one or two places may be, but usually is not, necessary. The size of the frontals is very well determined by *x*-ray before the operation. The frontal is opened with gauge and mallet.

The opening is enlarged with Citelli rongeur or heavy Hejak punch. Very few patients complain when the frontal sinus is cleaned out with Coakley curet and sharp malleable ring curets. If any pain *is* felt, packing with cocain-adrenalin solution will stop it. When the ethmoids are opened there will be pain unless packing and working are alternated. The bleeding is so well controlled that the landmarks and field are always in plain view before the operator at all times. The nasal nerve, where it makes its exit from the cranial cavity, is accompanied by blood vessels. These are clamped and tied on the orbital side, then cut internal to the clamp. The whole operative field is free of blood when the operation is ended. The time consumed is less than when general anesthesia is used. No postnasal plug is necessary. Drainage is by iodoform gauze in the nose.

[This paper represents a well thought out, logical way of handling the difficult external operation.—Ed.]

The Two-Stage Operation for Suppurative Frontal Sinusitis with External Manifestations. In a previous critical study of the surgical management of cases of definite suppurative frontal sinusitis with some external manifestation, H. I. Lillie and C. M. Anderson[9] found that the best results were obtained by employing the two-stage, intranasal and radical operation. Further experience with the same type of disease has shown that the two-stage operation is satisfactory. The external radical stage may be avoided in certain cases in which it might have suggested itself primarily as the method of choice.

The rationale of the method seems reasonable. It was observed that the intranasal maneuver as the final stage in the external radical operation presented many difficulties; for example, the anatomic relations are inverted; bleeding interferes notably with good visibility; and in case other paranasal sinuses are involved, too radically destructive measures are required to eradi-

(9) Arch. Otolaryng., February, 1927.

cate the disease. The intranasal stage of the operation, on the other hand, performed under local anesthesia with the patient in the sitting position, overcomes these objections. The maxillary, sphenoidal and ethmoid sinuses can be attacked if necessary, and the nasofrontal duct enlarged. In other words, by this method of attack, the final stage of the radical external operation is used as the first stage in the two-stage method, except that it is performed intranasally under local anesthesia.

It is natural that patients prefer to avoid an external operation on the frontal sinus because of the possibility of scarring and unsightly deformity. However, this group of patients is anxious to be rid of the disease and is willing to accept the possibility of some deformity, if more conservative measures have failed. Some type of incomplete operation which had not controlled the disease had been performed before the patients presented themselves. The surgical treatment is formidable under the best conditions but the possibility of deformity need not be so great as to prevent external operation.

The type of disease must be determined. If it is simply a suppurative process, ample intranasal drainage will control it. If the integrity of the mucous membrane and periosteum has been assailed, and periostitis or osteomyelitis has resulted, nothing short of eradication of the lesion will control the disease.

The nose is not packed after operation, and in the after-treatment a cannula is inserted through the nasofrontal duct and the contents of the sinus aspirated. Irrigation with any aqueous solution is avoided. It has been found that the less the healing parts are disturbed, the better the progress made.

The authors have found the intranasal operation effective when we did not expect it to be.

If the external operation is necessary, it can be performed after a week or ten days. The type of anesthesia is important, but is dependent on facilities and the preference of the surgeon. Recently the authors have used

rectal anesthesia with satisfactory results, although gas and ether are well adapted for this purpose except for the obvious disadvantage.

[The method followed by the authors is that long practiced by rhinologists, namely, to undertake intranasal surgery for the relief of frontal sinusitis and when this fails to give sufficiently satisfactory results, to resort to the external operation. The only difference here is that the authors seem to expect to have to do an external operation and seem surprised to find that this is often unnecessary.—Ed.]

The Influence of Negative Pressure in the Sphenoid on the Optic Nerve. The fact that the opening of the posterior sinuses, although apparently normal, usually relieves optic neuritis, has led to the conclusion that these sinuses are in some mysterious way responsible for the eye condition.

The foci actually responsible for most of the optic nerve disturbances have been found in the teeth and tonsils. The theory of negative pressure in the posterior sinuses would explain the beneficial results which follow the opening of normal sinuses.

Negative pressure is considered by L. E. White[1] under two aspects:

1. Is it possible for it to take place in the posterior sinuses?

2. If it does exist, would this negative pressure favor the passage of the bacteria in the blood stream to the nerve?

Negative pressure is a well recognized condition in the frontal sinus, antrum, anterior ethmoids and middle ear, and is brought about by a closure of their ostia or ducts, so that reasoning by analogy, a similar condition should be brought about by the closure of the sphenoid ostium.

In Bell's palsy negative pressure within the tympanum seems to favor the migration of bacteria from some

(1) Ann. Otol. Rhin. & Laryng., December, 1926.

distant focus to the facial nerve, so that it seems logical to conclude that a similar condition of negative pressure within the sphenoid would favor migration of bacteria to the optic nerve. If it is conceded that a closed sphenoid may favor the invasion of the optic nerve by bacteria from the blood stream, the logical thing is to eliminate the focus that feeds the bacteria to the blood.

Treatment is considered under three heads:

1. About 50 per cent. of the cases will recover spontaneously. Any definite focus is to be removed. If none is found, surgical intervention is contraindicated.

2. In 30 per cent. of the cases the relief of nasal blocking is indicated in addition to the removal of the focus.

3. In somewhat less than 20 per cent. of the cases it will be found necessary to open the posterior sinuses to prevent optic atrophy.

Thirty-three optic nerve cases are analyzed. In but 15 per cent. were the sphenoids and posterior ethmoids opened, and even in some of these it was unnecessary.

[The author presents a logical formula in the handling of this most difficult problem, the relations of optic neuritis to sinus disease. His conclusions may well be a guide to many of us who see much less of this sort of work than the author has the opportunity of observing.—Ed.]

Foreign Bodies in the Accessory Nasal Sinuses. In reviewing the literature on this subject M. B. Wilson[2] has divided the cases into five groups:

Group 1 consists of foreign bodies of dental origin, of which 17 observers reported 19 cases.

Group 2 consists of calculi, of which 2 observers reported 2 cases.

Group 3 consists of instruments and appliances, of which 33 observers reported 35 cases.

Group 4 consists of gun pieces and bullets of which 40 observers report 41 cases.

(2) Ann. Otol. Rhin. & Laryng., December, 1926.

Group 5 consists of miscellaneous foreign bodies, of which 12 observers reported 13 cases.

The author's case was that of a man, 38 years old, who presented a fistula in the lower eyelid, apparently leading to the antrum, and considerable pus discharge into the nose on the same side. A second *x*-ray picture revealed a foreign object in the left maxillary sinus. A Caldwell-Luc operation was performed and a horn pipe stem removed from the sinus. Following the operation the fistula healed and the purulent discharge ceased.

Endonasal Treatment of an Ethmoid-Frontal Mucocele. Rossier[9] reports a case of a girl, aged 18, who had a swelling in the region of the internal angle of the left orbit, accompanied by diplopia and displacement of the eyeball to the left. There was a large bony portrusion in the region of the middle meatus. This protrusion was rounded and smooth, and touched the nasal septum. There was a normal mucosa, and no pus was present in the nose. The roentgenogram showed a mass uniformity clear in the region of the left frontal ethmoid. This mass was regularly rounded and encroached on the inferior and internal part of the frontal sinus. The diagnosis was a mucocele developing from the anterior ethmoid cells and spreading out to the inferior part of the frontal sinus.

An operation was performed under local anesthesia and consisted of resection of the septum, removal of the anterior two-thirds of the left middle turbinate and opening up of the bony swelling endonasally with escape of a mucoid, slightly yellowish fluid. The frontal sinus was probed, and the entire region involved was cleaned out. The bony bulging at the orbital angle was reduced under ethyl chloride anesthesia by digital pressure. Six months later, there was an excellent result.

The author speaks of the endonasal route not being generally used in the treatment of mucoceles of the ethmoids. He states that the mucocele from the posterior

(9) Ann. d. mal. de l'oreille, du larynx, January, 1927.

ethmoids must be operated on by the external route. The pure frontal sinus mucoceles should be operated on either endonasally or externally, depending on the size of the cavity and the ease with which the mucocele can be reached. The anterior ethmoid mucocele should be operated on by the endonasal route. The principal indications are the ease with which the opening of the pouch through the nasal fossa can be made and the possibility of resetting the deformed orbital wall by simple external digital pressure.

Experiences with Orbito-Ethmoidal Osteomata Having Intracranial Complications. H. Cushing[1] reports four cases of orbito-ethmoidal osteoma with intracranial complications. In the first case, that of a man 23 years of age, the osteoma was clinically mistaken for a meningioma of the olfactory groove. Transfrontal osteoplastic exploration disclosed an intradural projection of the osteoma. The tumor was removed through the roof of the orbit with unavoidable opening of the ethmoid cells. The operation was followed by cerebrospinal rhinorrhea and death from infection and meningitis.

The second case was that of a man 22 years of age who gave a history of convulsions and recurrent orbital infections. A lateral craniotomy had been done previously for drainage of an infected (?) aerocele. Attempted exposure of the tumor by the author was blocked by an infected frontal sinus. Further surgical intervention was delayed. A ventricular pneumatocele with nasal rhinorrhea then developed and death resulted from meningitis four years after the onset of the symptoms.

In the third case, that of a man 41 years of age, a huge intracranial pneumatocele of unexplained origin was exposed and emptied at operation. The pneumatocele then recurred. A second operation revealed an ethmoidal osteoma and alongside it a minute canal connecting the ethmoid cells with the adherent leptomeninges, whereby the pneumatocele could be inflated. The tumor was

(1) Surg. Gyenc. Obst., xliv, 1927.

removed and the canal closed by the implantation of fascia. The patient recovered.

The fourth case was that of a man 35 years of age. A transfrontal osteoplastic craniotomy revealed an orbito-ethmoidal osteoma with an intradural projection and an intracerebral mucocele. The tumor was removed through the roof of the orbit with opening of ethmoidal cells. Closure was effected with a fascial stamp. Uncomplicated recovery resulted.

The author states that the first two of these patients died because of a lack of knowledge concerning the relation of the osteoma to the intracranial symptoms. One died from infection due to failure to close off the communication between the meninges and the nasal cavity at the conclusion of the operation and the other as the result of surgical procrastination.

In the author's opinion, it is best to remove ethmoidal osteomata as soon as they are revealed by the *x*-ray. The lesion under consideration arises apparently from the ethmoid cells. Therefore it would supposedly lie in the province of, and be detected primarily by, those who specialize in diseases of the nose and throat. As a matter of fact, the secondary symptoms usually send the patient first to the ophthalmologist, and in the past the ophthalmologist has courageously and often successfully attacked the lesion from in front with the removal of at least its intra-orbital portion.

It is evident, however, that certain of these ethmoidal osteomata, perhaps the majority of them, ultimately lead to intracranial complications of one sort or another. Consequently they may fall into the hands of those whose special training makes them more familiar with the cranial chamber than with the orbit or the recesses of the nasal air passages. So do the surgical specialties overlap. Since no surgeon can possibly foretell into what difficulties or into what adjacent and unfamiliar regions his chosen specialty may lead him, the patient will be safeguarded only when all who engage in surgical spe-

cialization have a thorough preliminary grounding in the principles of general surgery.

Abscess of the Frontal Lobe Following Sinus Disease. G. Portman and N. Moreau[2] discuss the occurrence of abscesses of the frontal lobe of the brain following suppuration in the frontal sinuses. The condition occurs about puberty, and its frequency increases from then to a maximum at about the age of 30, whence it decreases, until examples are almost unknown after the age of 55. Approximately two males are affected to one female. Tuberculosis, diabetes, and syphilis appear to be without influence on its occurrence. As in ear conditions, it is the recrudescence of a chronic or a quiescent suppuration that appears to be most commonly followed by an abscess. Minor traumata acting on an infected sinus appear to influence its spread, and incomplete operations which leave behind infected pockets and fronto-ethmoidal cells are likely to be followed by an abscess. Careful search has to be made at the time of operation for subsidiary cells and reduplicated sinuses. The purulent infection may spread directly through the posterior osseous wall of the sinus and finally reach the brain, or it may pass along the walls of an infected vein. The abscess forms in the frontal lobe, is usually pyramidal in shape, and is limited in its backward progress by the anterior extremity of the lateral ventricle. It varies in size from that of a small nut to a hen's egg. It may be single, may have diverticula, or there may be several small abscesses just under the cortex. The contents are yellow or greenish-yellow pus and may include some gas; there is usually a very fetid collection of pus.

Localizing symptoms are absent, and in the presence of a frontal sinus suppuration attention is drawn to the brain by signs of intracranial tension. Frontal headache is the most common sign, and vomiting, and slowing of the pulse and of cerebration may follow. There is rarely any papillo-edema, and attempts at localization are diffi-

(2) Rev. de laryngol., Jan. 15, and Feb. 15, 1927.

cult. In the earlier stages changes of a psychical nature somewhat similar to the grandiose ideas of general paralysis may be noticed, and the conversation may take on a very childish strain. There is often a marked and unnatural loquacity. As the disease progresses there is a weakening of judgment, of memory, and of will, and a confusion of ideas. The olfactory function is interfered with, and this, if unilateral, is of great value in localization. In large abscesses the motor area may be affected, giving rise to epilepsy, or sometimes, in very late cases, to paralysis. There are four stages in the formation of an abscess. In the first there are slight fever, headache, and slight vomiting; this may go on to acute encephalitis, or more usually it subsides and the condition falls into the second stage of remission; the third stage is that of manifestations of intracranial pressure and irritation; the fourth is the terminal stage, in which coma follows the continued increase of pressure, or death is caused by irruption into the lateral ventricle.

Osteoma of the Frontal, the Maxillary and the Sphenoid Sinuses. As regards age incidence this type of tumor usually develops in the young when the bones are undergoing the greatest developmental activity. The varieties of osteoma are: (1) hard, eburnated; (2) compact, and (3) spongy. They vary in size from that of a bean to that of a good sized potato. The weight varies from 7 to 440 grams. Growth usually is slow; it is often ten years or more before the tumor causes the patient to seek relief. There may be several tumors and they may involve even the frontal nasal or lacrimal bones, or all of them.

The symptoms are divided by W. T. Garretson[3] into (1) local, that is, within the sinus itself, and (2) those from pressure on adjacent cavities.

1. Patients often have attacks of pain over the site of the sinus or growth. This is usually caused by a growing tumor. In general, however, there are no symp-

(3) Arch. Otolaryng., February, 1927.

toms, owing to the slow growth, unless basal structures are pressed on, and these usually are in the later stages when the nasofrontal duct has been closed and either mucocele or sinus infection is present, or when pressure on the nerve supply to the orbital tissue or under the optic nerve itself is present.

2. The symptoms in the second class of cases depend on the cavity involved and on the extent of the encroachment. The older cases which are reported are principally cases of tumors of the orbit. The classic picture of this tumor is as follows: The orbital contents are displaced, usually forward, outward and downward, with a marked proptosis. In a tumor of this kind, palpation above the eye usually reveals a hard, firm ball which is more or less painful. The tumors within the nasal cavity or sinus often project into the brain cavity. Diplopia and optic nerve derangement are often prominent symptoms. In the intranasal type, external nasal deformities and nasal obstruction may be present. In those with prominence of intracranial extension in the place of sinus infection, meningitis may be the first symptom. However, the tumor may project into the cranial cavity, owing to the great adaptability of the brain to gradual encroachment from without.

Besides the clinical symptoms mentioned, roentgen ray examination is of paramount importance in the diagnosis, especially in the eburnated variety of tumor. In the compact or cancellous variety, the roentgen ray, aside from showing the bony tumor, does not give the classic picture owing to the similar roentgenographic density. In these kinds of tumors, malignant bone tumors will be rather difficult to differentiate. In the diagnosis, mucocele of the ethmoid and frontal and maxillary sinuses must be differentiated. In these, expansion of bone usually is present until the point is reached at which superadded infection may intervene. Malignant tumors are rare in the frontal and ethmoid sinus, but in the maxillary sinus bony tumors originat

ing from the dental structures may render diagnosis difficult. The rareness of the osteoma, however, tends to eliminate the diagnosis of malignancy.

The treatment is complete surgical removal whenever possible. This usually is best accomplished by the external route after the Killian method. In this operation the ethmoids and sphenoidal osteoma may be best approached.

Intracranial Complications of Fracture of Skull Involving Frontal Sinus. Although not of common occurrence, in F. R. Teachenor's[4] experience, fractures involving the frontal sinus have been the source of intracranial infection with greater frequency than in all other fractures of the skull combined. He has also noted that the fractures involving the frontal sinus have been from extensions of fractures of the vault of the skull, rather than from fractures of the base.

Basilar fractures have always been considered grave, one reason being that basilar fractures are frequently compound by involvement of the paranasal sinuses. Basilar fractures following a transverse meridian frequently involve the middle ear and the mastoid, ethmoid and sphenoid sinuses. Those passing along the longitudinal meridian involve the petrous bone and the ethmoid and sphenoid sinuses, but usually pass lateral to the frontal sinuses and rarely involve them.

Fractures of the vault of the skull usually include both tables of the bone. The fracture of the outer table passes through the anterior wall of the frontal sinus. Fracture of the inner table passes through the posterior, or inner, wall of the sinus. It is the fracture of the posterior, or inner, wall of the frontal sinus that is of importance, as it forms a compound fracture and exposes the cranial cavity and contents to infection. In one of the author's cases, the inner wall of the sinus was fractured without involvement of the outer wall.

When a fracture of the inner wall of the sinus exists,

(4) J. A. M. A., Mar. 26, 1927.

two factors combine to render intracranial infection almost inevitable.

First, hemorrhage from the line of fracture in the sinus wall fills the frontal sinus with blood. The blood then flows through the frontal duct into the middle fossa of the nasal cavity. Here the blood tends to obstruct the nasal passages and causes irritation of the sensitive mucosa. The patient reacts by blowing the nose, sneezing, or other increased respiratory effort to clear the nasal passages. All of these reactions tend to increase intranasal pressure and force infective material under pressure into the frontal sinus and through the fracture into the cranial cavity. The author believes this to be an important factor in the transmission of the infection.

Second, a blood clot forms within the frontal sinus. This clot becomes infected from the nasal cavity, or from latent infection existing within the sinus itself. By ball valve action of the clot, or by infection and swelling of the sinus mucosa, the nasal duct becomes occluded. With the frontal duct occluded, inflammatory reaction within the sinus soon increases the intrasinus pressure and forces infection through the fractured sinus wall into the cranial cavity.

Fortunately, the frontal sinus is readily accessible, and both of these factors may be controlled by prompt surgical drainage.

The operation required is very simple and can be done in a few minutes under local anesthesia. After proper surgical preparation, an incision is made starting at the root of the nose and continued laterally for a short distance in the eyebrow so as to expose the anterior-inferior wall of the affected frontal sinus. The wall of the sinus is perforated by a drill or chisel and enlarged to about 1 cm. in diameter. The opening into the sinus need be only large enough to remove the blood clot and control hemorrhage within the sinus. In cases in which cerebrospinal rhinorrhea is present,

or cerebrospinal fluid is found in the sinus, the opening in the anterior wall of the sinus must be enlarged sufficiently to enable one to remove the inner sinus wall and locate and suture the laceration in the dura. A small rubber tube is used for drainage, and placed so that the lumen of the tube is directly over the frontal duct leading into the nasal cavity. This conducts any air forced into the sinus from the nasal cavity through the tube to the exterior. If gauze packing is required to control oozing, it should be placed so as not to cause interference with this function of the drainage tube. The incision is then closed about the tube, and packing and dressings are applied in such a manner as to permit free passage of fluids and air from the tube. The packing is removed in twenty-four hours. The tube is permitted to remain in place for one week and kept freely open during this time.

For the sake of contrast, the author has divided his sixteen cases of fractures of the skull involving the frontal sinus into two series of eight cases each. In the first series there were three operations, but they were done after the onset of the complications. In the second series prompt operation was done in each case as a preventive measure.

In the first series of eight patients, there were seven deaths. Two died from brain injury accompanying fracture; one of intradural frontal abscess; one of extradural abscess and meningitis, and three of meningitis. In one case of cerebrospinal rhinorrhea the patient recovered.

In the second series of eight patients, there were three deaths. Two died from brain injury accompanying fracture, and one of meningitis; five recovered without intracranial complications.

Epistaxis is the one constant symptom, and in one of my cases was the only subjective sign. Usually there is some ecchymosis in the region of the frontal sinus, at the root of the nose or about the inner canthus of the

eye. In severe injuries there are gross signs of trauma. Roentgenograms are invaluable, and it is with them that the final diagnosis is made. In addition to the line of fracture, the roentgenogram frequently shows marked opacity of the affected sinus as a result of blood in the sinus.

Atrophic Rhinitis

Treatment of Atrophic Rhinitis by Ivory Implants. According to H. L. Pollock[5] the etiology of atrophic rhinitis is unknown and thus far the treatment has been unavailing. The symptoms persist unless the abnormally large intranasal space is materially lessened. By intraseptal implant of ivory, this space can be lessened and consequently the symptoms must disappear.

Thus far the author has operated on one side only, being fearful of a loss of cartilage. It is only a question whether the perforated implants will remain in situ or slough out, and time, and time alone, will solve this question.

Up to the present time it has been necessary for the writer to remove the implants in only two cases; all of the other patients being delighted with the unilateral result and anxious to have the other side operated on. On examination in these cases the cartilage appears still intact.

Four Years' Clinical Experience in the Surgical Treatment of Ozena by Implantation of Macerated Spongy Bone of Cattle. Recent added experience by Eckert-Moebius[6] has shown that the more porous the bone, the more easily the granulation tissue grows through it. For this reason several small pieces of bone are used, which are easier than the larger ones to introduce.

The interior of the nose should be carefully cleansed and iodine painted in the vestibule. Eighteen patients have been under observation for from three to four

(5) Ann. Otol., Rhin. & Laryng., March, 1927.
(6) Ztschr., f. Hals—, Nasen—, u. Ohrenh., November, 1926.

years; there was perfect healing in nine; nine extruded small pieces of bone, and in five, lesions of the mucosa were caused. The operation was unsuccessful in only three patients; of the remaining fifteen, six were cured without any after-care, while nine were greatly improved, requiring an irrigation of the non-operated side.

During the last three years sixty patients have been operated on, with what the author believes will be even better results.

Atrophic Rhinitis: Some Findings in a Series of Eighty Cases. In this article G. D. Hoople and A. W. Rowe[7] give their results of their detailed study of this condition:

1. Of 80 cases of atrophic rhinitis there were 31 male and 49 female patients.

2. The average age at onset was 14.9 years.

3. At the time of examination the average interval history (from onset to the present) was ten years.

4. Sixty per cent. gave a history of previous purulent nasal discharge.

5. Every patient in the series had a negative Wassermann.

6. There were no consistent findings in the bacteriologic examination.

7. Seventy-five per cent. of the cases showed, by *x*-ray, pathology in the sinuses. The antrum was most frequently involved.

8. Evidence seems to point to the fact that some factor present in atrophic rhinitis causes a disturbance, in some patients, of the normal functioning of the thyroid gland. In general, atrophic rhinitis has an adverse influence on body metabolism. There was no evidence obtained that pathology of the endocrine glands had a causal relation to atrophic rhinitis.

9. There was a remarkable variability in the findings of the patients in this group. This is best explained by assuming that atrophic rhinitis is the product of a

(7) Ann. Otol., Rhin. & Laryng., March, 1927.

combination of factors rather than the result of any one cause.

The Significance of the Germinal Substance in Incidence of Ozena. W. Albrecht[8] investigated 25 families, whose family trees he had diagrammed; they showed a decided tendency to have either atrophic rhinitis or ozena. His conclusions were: (1) A tendency to chronic inflammation is present in the mucosa; (2) the membrane reacts to the inflammatory agent according to its hereditary tendency by an atrophic change; and (3) the form and width of the nose is an etiologic factor. As to whether or not the specific odor of ozena is due to the Perez coccobacillus, the author has not yet decided.

Miscellaneous Nasal Conditions.

Treatment of Obstructing Inferior Turbinates. Nasal obstruction is a very common complaint for which patients seek relief. It may be due to a septal deviation but more frequently to an obstructing inferior turbinate. The textbooks describe various methods of handling hypertrophic inferior turbinates, which are sometimes part of a chronic hypertrophic rhinitis, sometimes compensating with a deviation of the septum and often as a result of venous stasis. The treatment should take under consideration the difference in pathology.

Inferior turbinates may hypertrophy from diseases above. Discharges from the ethmoids and other sinuses will secondarily affect the turbinates, causing vasoparesis in the erectile tissue. At the beginning the obstruction will be intermittent, depending on variations in the rest of the nasal mucosa and the character of the discharge. This gives us the so-called turgescent inferior turbinate. Finally, the obstruction may be constant when hyperplasia takes place in cases of chronic inflammation. The inferior turbinate that shrinks little under adrenalin is probably hyperplastic, and one that shrinks

(8) Ztschr., f. Hals—, Nasen— u. Ohrenh., October 6, 1926.

to half or less is turgescent and gives intermittent obstruction.

M. L. Harris[9] believes it is manifestly unsound to remove turbinates completely except for malignancy. What one needs to do is to restore function. All that is necessary is to give the patient sufficient breathing space to make him comfortable and provide proper aeration for all the nasal chambers.

The obstruction may be handled in various ways, depending on its cause and its pathology. An inferior turbinate which is hyperplastic is best partially removed and a simple method is that with the clamp and cautery, as this is not followed by troublesome bleeding.

Submucous resection involves removal of the turbinate bone and is rather a long procedure and not always easy. Cauterization only destroys the mucosa.

The inferior turbinate that causes intermittent obstruction is one in which the venous channels get engorged intermittently and these are best treated by coagulation of these venous spaces. This is best accomplished by the high frequency current. The monopolar method is used and coagulation is produced by inserting the needle for distances varying from one-fourth inch to one-half inch at various points in the submucosa and the current allowed to flow for about ten seconds. This is repeated in a week and again if necessary until the turbinate assumes a stationary position without obstruction. Of course, disease of the sinuses which is frequently the cause of this condition should also be treated at the same time.

The method of reduction of an hypertrophied inferior turbinate is simple, there is no bleeding, requires no packing and there is no danger of postoperative synechia, as in repeated cauterization.

[A timely reminder of the clinical fact that obstruction to nasal respiration, even when associated with an anatomical irregularity of the septum, may best be re-

(9) Laryngoscope, May, 1927.

lieved by proper treatment applied to the turbinal body. Simple linear cauterization practiced so much a quarter of a century ago seems to have been forgotten by many rhinologists today. It is a simple, effective, entirely harmless method for shrinking up the turgescent membranes. We do not understand what the author has in mind about the resulting synechia of the septum. Linear cauterization of the turbinal bodies does not touch the septum.—Ed.]

Radium in the Treatment of Nasal Polypi. S. N. Key[1] believes that nasal polypi are the outcome of a hyperplastic non-secretory ethmoiditis. As a result of his experience the author concludes that:

1. Radium is indicated postoperatively in all cases of nasal polypi.
2. Radical nasal surgery will be less frequently indicated where radium is used.
3. The percentage of cures will be greater where radium is used.
4. The interval between recurrences will be lengthened.
5. The objections to the use of radium are the length of time radiation consumes, and the production of atrophy in the region where the radium is applied.

[Our experience with the use of radium for the relief of hyperplastic ethmoiditis has not brought us to the conclusion that this method will supplant the operation for exenteration.—Ed.]

Chancre of the Nasal Septum: Report of Three Cases. That a primary syphilitic infection of the nasal septum may not be as rare as generally supposed is indicated by the subjoined three cases seen in private practice by E. P. Zeisler[2] within the last five years.

Case 1.—A man, aged 30, married, was seen, November 13, 1926, because of a cutaneous eruption and a lesion within the nose, producing swelling and obstruc-

(1) Texas State J. Med., October, 1926.
(2) J. A. M. A., May 28, 1927.

tion of the left nostril. For six weeks he had noticed a "sore" in his nose which caused difficulty in breathing on that side, swelling of the face, and pain radiating to the forehead. For several weeks he had received local treatment at the Eye and Ear Infirmary, where he was told that he had an ulcer in his nose and sinus trouble. For the past two weeks the glands at the angle of the left jaw had been swollen. A Wassermann test made prior to admission was negative. The eruption was first noticed five days before, and at the same time he began to complain of nocturnal headaches, slight fever and malaise.

The patient was well developed, but anemic looking. The temperature was 99.4 F.; the pulse was 90, and the respirations were normal. The left side of the face around the nostril was edematous and the left nostril gaping. Examination of the interior of the nose revealed an elevated granulomatous ulcer at least 1.5 cm. in diameter occupying the entire anterior part of the left nasal septum, and producing almost complete obstruction on that side. The lesion gave rise to a scanty discharge, bled readily, and was indurated. The right side of the septum was normal. There was a firm packet of glands in the left submaxillary region.

Examination of the trunk and extremities showed a typical macular syphilid. There was general adenitis. Lesions were not present on the genitalia. Dark field examination of the serum from the intranasal lesion revealed numerous actively motile spirochetes. The Wassermann reaction twenty-four hours later was reported four plus positive. The intranasal lesion, as well as the eruption, rapidly healed under antisyphilitic medication with the arsphenamines and mercury.

Case 2.—A physician, aged 40, was seen in the latter part of 1922 on account of a lesion of the septum of ten days' duration, which was suspected of being an early chancre. The patient indistinctly remembered having picked his nose about a month previously,

after examining a group of patients in an industrial establishment.

On examination there was found a round, shallow, bright red erosion of the anterior part of the nasal septum, about 0.75 cm. in diameter. A small, firm, submaxillary gland was palpable on the same side. Dark field examination revealed *Spirochaeta pallida*. The Wassermann test was negative. Treatment was promptly instituted and continued for a year, with an apparent clinical cure. The intranasal lesion healed without perforation. Symptoms or signs have been absent over a period of four years, and repeated Wassermann tests have been negative.

Case 3.—A man, aged 45, unmarried, was referred in January, 1924, for the diagnosis of a cutaneous eruption which had been present for two weeks. He stated that he had noticed a sore in his nose for six weeks, and had been treated locally by a well known rhinologist for an "ulcer." The glands in the right cervical region began to enlarge three weeks before.

Examination revealed a crusted ulcer on the right nasal septum, measuring a little less than 2 cm. across, with an indurated cartilaginous border and considerable edema of the surrounding mucous membrane. There was a massive bubo in the right submaxillary region. The trunk, face and extremities showed a maculopapular syphilid. The diagnosis was confirmed by a positive dark field examination and blood test.

The foregoing cases are illustrative instances of primary syphilitic infection of the nasal septum. In two, the diagnosis was not made until the supervening glandular swelling and the exanthem made it self-evident. In one case, the correct diagnosis was made by the examining rhinologist, and confirmed by finding *Spirochaeta pallida* in the early seronegative stage, the ideal time for abortive treatment. The most important point in the early diagnosis of a hard chancre of the septum is the erosion or ulceration with indurated bor-

der on the septal surface, which bleeds easily but does not cause perforation. The surrounding mucous membrane may be edematous, clogging the nose and producing some discharge. There may also be swelling of the outer surface of the nose, and at times pain radiating to the teeth, eyes and forehead. The discrete, painless submaxillary bubo is an important diagnostic point, as this does not occur in the commoner tertiary lesions within the nose.

The differential diagnosis must exclude the various forms of late syphilis, particulary the circumscribed gumma of the septum with crater-shaped ulceration and perforation; tuberculosis, either in the form of the solitary tuberculous ulcer or an ulcerating lupus vulgaris, and epithelioma involving the septum. In rare instances, a rhinoscleroma may have to be ruled out.

In the literature on syphilis, scant mention is made of the possibility of primary intranasal syphilis, but cases are on record of infection carried by fingers, handkerchiefs, towels and sponges. Rhinologists, who are the first to see these lesions, should recognize the necessity of making the diagnosis as early as possible, and the importance of dark field examination in suspicious ulcers or erosions of the septum.

Intranasal Radium Therapy in Malignant and Benign Tumors. E. R. Van Meter[3] has made observations on ten cases of this type, that is, malignancies originating in the nasopharynx. From his observations on this limited number of cases, and from the experiences and observations of other writers on this subject, he has drawn the following conclusions:

1. Malignancies occurring in the nose or nasopharynx are far more frequent than even the most conservative believe.

2. More careful study by the rhinologist of this type of case, especially of the nasopharyngeal space, should be made.

(3) Arch. Otolaryng., March, 1927.

3. In certain malignancies, when diagnosis is made early, radium offers greater possibilities as a therapeutic agent than any other known remedy.

4. In persistent, recurrent cases of nasal polypi, the combined surgical and radium treatment is to be preferred, and a certain number of these patients will get well under this treatment.

5. Larger doses of radium should be used, and the radium should be administered in one dose rather than in divided doses.

6. Radium should not be used until four weeks after operation.

[Our experience has been that malignant growths in the nasopharynx and nasal cavities are very favorably influenced by radium. In most of these cases the patients died of the extension of the growth, but the relief is remarkable and prompt. In some cases years have elapsed without any detectable recurrence.—Ed.]

Tuberculosis of the Nasal Fossæ. All manifestations of tuberculosis occurring intranasally except cutaneous lupus are considered by H. Retrouvey[4]. Primary tuberculosis is thought to be rare, usually latent and of slow progress. The author describes the lesions under five headings:

1. Ulcerative lesions, which generally made their appearance suddenly in advanced tuberculosis. The sites of election are the anterior-inferior portion of the septum, the extreme anterior portion of the lower turbinate and the adjacent floor of the nasal fossa. The subjective symptoms are slight; there is a burning sensation, but little or no obstruction or secretion. The general appearance of the mucous membrane is pale. There may be one or more superficial ulcerations, the irregular margin of which blends with the surrounding sound tissue. The floor is a gray-red, uneven and often covered with crusts. These may be yellowish granulations in the vicinity of the ulcerations.

(4) Rev. de Laryngol., Jan. 15, 1927.

2. Larval lesions, in which the only means of arriving at a diagnosis is by a study of the pathologic anatomy. The microscopic section shows tuberculous follicles, giant cells and bacilli. The symptoms are essentially disappointing. The subjective symptoms are those of hypertrophic coryza, with watery discharge and obstruction. The appearance is that of ordinary hypertrophic coryza. There are no ulcerations, although true bacillary ulcerations have been observed after turbinectomy. The course is benign, and the condition responds to appropriate treatment.

3. Pseudo-atrophic lesions, which Moure is quoted as describing as indicative of a prebacillary tuberculosis. Microscopically, one finds only common chronic inflammatory changes. The symptoms and observations resemble those of atrophic rhinitis, from which this condition must be differentiated. The general appearance of the patient is that of adolescence, with lymphatic facies, soft, waxy flesh, large lips and physical and mental underdevelopment.

4. Vegetative lesions, which are divided into the tuberculoma and the osteocartilaginous forms. The tuberculoma, rather rare, is usually found on the anterior part of the septum. It varies in size and shape, is rose gray or red, granular and of soft consistency. Microscopically, one finds lymphoid elements, giant cells and caseous tubercles. The mucous glands are infiltrated, and the perichondrium may be invaded and perforated. The epithelium of the crypts is cylindrical, while the surface cells may be pavement. The characteristics are those of obstructing tumor. Perforation of the septum is to be expected, but epistaxis is rare. The course is latent, and prognosis is relatively good. The osteocartilaginous form is rare, but serious. It may be primary. The lesion begins in the osteocartilaginous framework of the nose, and gradually invades the mucosa. The symptoms are those of obstruction due to tumor. The appearance of the tumor mass is that of polypoid degeneration. The

septum is usually thickened and ulcerated. Progress is rapid, and death often results from tuberculous meningitis.

5. Lupus, which shows a preference for young adults, especially women. It usually attacks the anterior third of the fossa, later invades the choana and finally the pharynx. The lesions are in the form of small tubercles scattered throughout the mucosa. They may be exuberant and assume the vegetative form. On section the usual pathologic condition in tuberculosis is found. The subjective symptoms are not distressing, usually being due to crusting. On inspection one finds eczema of the vestibule. On clearing away the crusts in the nose, areas of small rose and brown granulation are found, giving the mucosa a more or less fungoid appearance. In this fleshy bed, ulcerations and even perforations may be found. Sometimes the granulations may be exuberant, and may assume the appearance of the vegetable type. The lesions resolve themselves into cicatrices and deformities. Syphilis may modify the symptoms, the lesions assuming the characteristics first of one condition and then of the other. Cutaneous lupus usually is found.

Cerebrospinal Rhinorrhea; the Study of One Case and Reports of Twenty Others Collected from the Literature Since 1900. In this article W. H. Johnston[5] presents an exhaustive review of the literature regarding the pathogenesis and diagnosis of this condition. The author's case was that of a married woman, 34 years old. Following an attack of influenza the patient complained of nasal discharge, most marked on the left side. Examination of the nose revealed nothing particularly abnormal. The exact point where the fluid escaped could not be seen, but it was apparently from somewhere in the posterior half of the cribriform plate. The laboratory tests made on the fluid showed it to be cerebrospinal fluid. Linen was not stiffened; with Fehling's

(5) Ann. Otol., Rhin. & Laryng., December, 1926.

solution a copper reducing substance was found. The author considers the etiology to be an internal hydrocephalus, resulting from an obstruction to the normal circulation of the cerebrospinal fluid. The obstruction was probably caused by a low grade inflammation or pressure from a slow growing tumor of the base. The only treatment which made any change in the amount of fluid was restriction in the amount of fluid intake.

Summary of Cases Reported.—Including the case here reported, there are 21 in the series. The ages ranged from 22 to 57 years, and there were 13 females and 7 males. The nostril affected was the left in nine instances, right in eight instances, bilateral in one and not stated in three. In Thomson's series of nine undoubted cases there were five left side, one bilateral, one right, two not stated. The duration of the flow was not stated in every case but ranged from one week to nine years. Eye symptoms were reported in ten cases and cerebral symptoms in fourteen cases. Injury could be considered as an etiologic factor in six instances. The escape of fluid persisted in nine cases, and the patients were alive at time of report. The flow had ceased in six cases. Six of the twenty cases reported were dead when reports were published. In the progress of the writer's case there has been little change. General condition is better than in June and she has gained in weight. No eye and no cerebral symptoms have been observed up to this time. She complains of some headache but it is not severe and apparently does not interfere with her rest or with attention to her usual duties about her home.

[This unusual and most interesting phenomenon is one with which rhinologists have long been familiar. The cause is obscure.—Ed.]

The Method of Choice for the Correction of Saddle Nose. J. N. Roy[6] believes that the ideal method for the correction of depressed nasal deformities consists in making an internal incision and, after having pre-

(6) Arch. Otolaryng., March, 1927.

pared a tunnel, inserting a piece of the cartilage of the first floating rib. When the graft is placed in position, the application of two little bands of adhesive tape transversally to the nasal bones fixes it, and consequently offers better conditions for adhesion with the surrounding tissues. Carried out in this manner, the operation is more likely to be successful by this than by any other method.

Diseases of the Mouth

Surgery of the Mouth and Face with Special Reference to Cleft Palate and Cleft Lip. W. H. Logan[7] summarizes his experience as follows:

1. An infant born with cleft of lip but having a normal alveolar process which may or may not be complicated with cleft to any degree of the soft and hard palate, posterior to the normal anterior alveolar process, should not have the lip deformity corrected until it has ceased to nurse, unless the surgeon is positive that the mother's milk can be maintained throughout the entire post operative treatment.

2. In the cases where there is a normal alveolar process as described and the infant is not receiving its nourishment by nursing, the operation upon the lip need only be postponed until a proven formula has been found, its birth weight regained and satisfactory physical condition is established.

3. Patients presenting with complete congenital cleft of the hard palate, alveolar process and lip should have the defect in the alveolar process closed between the second and fourth week if the patient's physical condition will justify. (The only exception made to this statement is in those cases where there is such a marked deficiency in the bony parts that to bring them into contact would occlude the nasal fossa on that side and produce a deformed upper arch.)

(7) Kentucky M. J., October, 1926.

4. To avoid undue surgical shock, it is held to be advisable in the majority of these complicated cases not to operate on the complete cleft of the lip until four to eight weeks after the operation for closure of the cleft through the alveolar process and a narrowing of the width of the cleft straight in from the tuberosities.

5. If the case is complicated with protruding maxillary bones, they should never be excised but always retained and placed in position to be made an integral part of the jaw as they contain, as a rule, the germs of the upper deciduous and permanent incisors and form a necessary support to the upper lip.

6. When separated bones are brought into position the compact surface is removed so that a bony union may be secured in the line of the alveolar ridge.

7. The operation for the closure of the soft palate should be undertaken between the eighteenth and twenty-fourth month, or just before or during the early weeks when the child is beginning to speak.

8. The employment of equistene in the lip operation instead of horsehair and the sealing of the line of incision upon the labial aspect with liquid benzoin evaporated to a syrupy consistency and the application of the traction bow with tension straps of adhesive plaster to the cheek and face is recommended.

9. Pre- and post-medical care should be in charge of a pediatrician.

Harelip and Cleft Palate. R. Durham[8] believes that these cases should be handled in the following manner:

First. At two weeks of age repair of the superior maxillary processes should be done.

Second. At the same time repair of the lip should be attempted if the condition of the child permits. If the child can not stand the added operation at the time, the harelip should be operated on as soon as possible after recovery from the first operation.

(8) Long Island M. J., March, 1927.

Third. Repair of the hard palate by the eighth month or before the sixteenth month should be attempted.

Fourth. The soft palate must be repaired six or eight weeks after the operation on the hard palate, or if possible by the eighteenth month.

The cleft palate interferes with the proper nutrition of the child because of the mechanical impossibilities of nursing at the breast, and the difficulty of swallowing, and the frequent regurgitation of food, and the resulting malnutrition. Therefore the closure should be done early.

The superior maxillae are soft, pliable, and easily moulded at two weeks, and the dangers of the operation are less than later in life; therefore early operation is advisable.

The repair of the lip helps approximate and mould the upper jaw after suture, and it also saves the distracted parents the embarrassment and need of apologies consequent upon this horrible deformity.

The repair of the palate should be completed by the time the infant is learning to speak, so that the speech may be more nearly perfect. This operation is usually done in two steps. When done at one sitting there is risk of non-union of the whole, whereas even a small degree of union of the hard palate makes the chance of success easier when the soft palate is attempted.

Aids to Palatal Sufficiency After Cleft Palate Operations. Where the child is reasonably young, R. Woods[9] believes that careful training is often all that is required. In more severe cases, when the patient is old enough, exercises before a looking glass in order to get voluntary control of the constrictors of the nasopharynx should be instituted.

When the opening, left after the postnasal sphincter has contracted, is small, the author has had good results from injections of paraffin wax behind the sac of the

(9) Brit. M. J., Feb. 26, 1927.

pharynx. This forms a cushion against which the soft palate makes a contact.

It is, however, in the worse cases of this kind that the author wishes to suggest a remedy and he presents a case which he has been able to so relieve. The patient, a woman, on whom quite a good operation had been performed still had a huge opening behind the palate. It occurred to the author that by snipping away the mucous membrane of the nasopharynx at the level of the soft palate that, after cicatrization when the scar had contracted, the defect might so be reduced that the patient could supplement it by training the muscles and so have much improved voice. Accordingly the procedure was carried out but the scarred area healed before adhesion occurred. The author then used diathermy. This produced sloughing of the adjacent areas of the pharyngeal tissues and as an end-result the opening was reduced by the adhesions and scarring until it was the size of the tip of a small finger. The patient was then able to learn to talk quite correctly.

Some Shortcomings in the Surgery of Cleft Lip and Palate with Suggestions for Meeting Them. In this article R. E. Farr[1] states that the management of cleft lip and palate is difficult and the results often unsatisfactory. More highly specialized training is desirable. Methods of procedure are not as yet standardized.

The following innovations are suggested:

1. The Brophy wiring may be done in two stages.
2. Postoperative manual stretching of the lip will relieve tension, increase redundancy and prevent its thinning out.
3. The nasal septum may be divided at its base to allow proper elevation of the nasal tip.
4. The prolabia may be used as a prolongation of the columella rather than a portion of the newly constructed lip.
5. Lip tension should be more often relieved by mak-

(1) Minnesota Med., February, 1927.

ing incisions along the "laughing wrinkle."

6. Cleft lip may be closed in two stages.

7. The delayed-flap method of suture of the palate may be indicated in certain cases and in every case of failure to obtain union a secondary suture should be made during the second post-operative week.

Chronic (Streptococcic) Hypertrophy of the Lower Lip. L. G. Beinhauer[2] reports the case of a baker, aged 19, who presented a persistent swelling of the lower lip. The condition began three years previously, following a fissure of the lip. A lymph puncture was made from the deeper structures of the lip and a streptococcus viridans recovered. The author had an autogenous vaccine made and the patient was given repeated small doses with gratifying results. Ultraviolet light therapy was also given and the lip was reduced about half in size. Recurrences of swelling have been treated with the vaccine and light therapy, and each time the swelling subsided. On one occasion radium was used, which resulted in a firmer, reduced size of the lip, but also caused it to be more painful with the recurrent attacks of the swelling.

This condition is supposed to be more prevalent in people constantly irritating the mucous membranes of the lip; such as, musicians, glass blowers, and smokers. Constant biting of the lip is also a predisposing factor. It may follow erysipelas, eczema or other facial infections always gaining entrance through a fissured or abraded mucous membrane. Both sexes are equally attacked. The condition is chronic but is subject to acute exacerbations. Focal infection about the teeth, intranasal regions, tonsils and adenoids play an important part in its production.

The condition may give local or general symptoms depending upon the severity of the infecting organism. A feeling of tenseness and weight with occasional obstructive symptoms to eating and talking and pain are

(2) M. J. & Record, Dec. 15, 1926.

the common symptoms. The clinical picture is constant in all reported cases giving a tender, red, greatly swollen everted lip presenting a glazed, slightly thickened mucous surface with the portal of infection usually present. The glandular involvement is very slight.

This type of chronic hypertrophy must be differentiated from the group macrochilia due to neoplasm, tuberculosis, syphilis, filariasis, injury, hypertrophy of the mucous glands and other allied groups. Elephantiasis, chronic lymphostasis, macrochilia and chronic hypertrophy have been used interchangeably but chronic streptococcic hypertrophy of the lower lip is favored as the name of choice because it is the most descriptive.

The treatment of this condition is very unsatisfactory. Radium and roentgen rays are of no benefit and are advised against because of the resultant fibrosis produced. Local injections of thiosinamin have no therapeutic value. Surgical procedures may be tried but give no permanent benefits. Of these the simple lymph drainage, the Handley and the complicated Kondoleon operations are the choice. Extirpation of the adjacent lymph glands offers another surgical procedure. The most effective treatment to combat the acute condition is repeated injections of small doses of autogenous vaccine. One must remember that any treatment used is only a palliative measure offering a partial reduction of the swelling and a temporary relief from its symptoms.

Observations on Salivary Secretions and Associated Clinical Findings. From a study of the saliva and also of the gastric secretion in a number of young adults R. A. Barlow[3] believes that cankrum oris is not a disease entity but an oral manifestation of some general disturbance. Cankrum oris in young adults should warrant careful investigation, with special reference to gastric acidity. The author has usually found this low in these cases.

Stomatitis, glossitis, or aptyalia in individuals more

(3) Ann. Otol., Rhin. & Laryng., December, 1926.

than 40 years of age should call for investigation of the gastric acidity and warn of the possibility of intestinal malignancy or pernicious anemia.

Alkalin mouth washes in the majority of these cases are of little value, and satisfactory results have been obtained by the administration of dilute hydrochloric acid (ten drops in water after meals).

Glossitis, stomatitis and cankrum oris are lesions on which the otolaryngologist may be called upon to pass judgment. Tonsillectomy and further surgical procedures should be postponed until other factors are ruled out. The acidity of the saliva is apparently a constant factor and is not markedly affected by disease.

Ranula. According to D. C. Fitzwilliams[4], ranula is a loose term inherited from bygone days, distributed widely over the world, and one which we shall probably never be rid of; but it is a term in medicine which cannot be defined and has no scientific meaning. It has been applied to all cystic swellings of the floor of the mouth whatever their form or origin. Dermoid swellings, swellings in connection with calculi of the salivary glands, acute swellings, traumatic swellings, parasitic swellings, swellings below the jaw, and even below the hyoid bone in connection with the thyroid gland, have all been included under the term ranula.

The actual connotation of the term ranula even is uncertain—whether it refers to the croaking voice caused by the tumor likened to that of a frog, as some assert, or refers to the glistening appearance of the tumor which resembles the belly of the frog is unknown. Some have thought the swelling is like the head of a little frog, the openings of Wharton's duct being its eyes, and others again have likened the glairy fluid evacuated to the jelly-like substance in which the eggs of the frog are found. Ranulae are found quite commonly among the lower animals.

(4) Brit. J. Surg., January, 1927.

The author discusses in detail the various types of ranula and presents a total of 22 illustrative cases, taken mainly from the literature. The variations of this tumor described include: cystic swellings of the mucous and sublingual glands; cysts of Blandin's gland; congenital ranulae; acute ranula; traumatic ranula, and large bilocular and burrowing ranulae (Fig. 25).

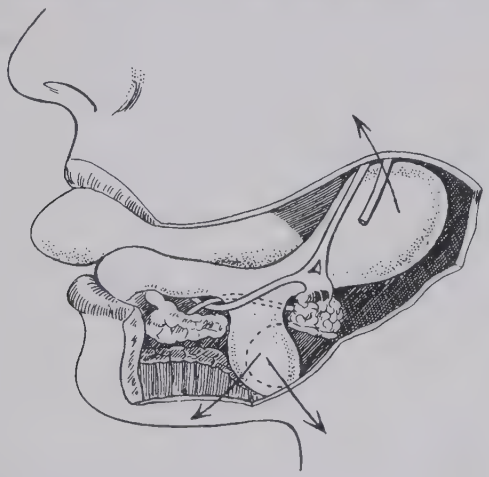

Fig. 25.—*Case.* The diagram shows a ranula under the tongue. The arrows indicate its extension through the mylohyoid muscle to below the chin, to the neck and face, and to the fauces.

From a consideration of such cases, which fairly represent every form of tumor described, the author concludes that these tumors form first in the mouth, and then spread, extend, or burrow into the other regions. Many are in connection with the submaxillary gland, others are not so obviously in connection with this gland, and others again have no connection with it. When traced to the region of the sublingual gland there is no way of telling whether they are mucous or salivary in origin. Birkett mentions one in which a probe could be passed along Wharton's duct, though there was a ranula with an extension into the neck.

Fleischmann described his bursa in 1841, but no one has been able to confirm his findings. The efforts of Tilleaux to establish the bursa were not accepted by his hearers. Skillern reported a bilocular ranula which he said originated in the bursa, but no proofs were forthcoming. The white-of-egg fluid was different perhaps from saliva, but it was not analyzed, and seems to have differed very little from the fluid found in those cases which were obviously in connection with the submaxillary gland. The author is not aware if the fluid from any of these extensive cases has been analyzed, or if it differs, as well it might, from normal saliva. It is known that saliva from the submaxillary gland differs from that of the parotid, and in physiological textbooks it is said that saliva from the sublingual is intermediate between the two.

Oral Lesions Due to Vincent's Angina. The condition that is called Vincent's angina presents a very varying appearance of the mucous membrane of the gums about the teeth, of the lips, cheek and floor of the mouth, and of the tonsillar area and pharynx. The mucous membrane lining the three communicating chambers—oral cavity, fauces and pharynx—may be diffusely involved or there may be only a single spot of a few millimeters in diameter. The single spot is the unit, and the diffuse lesion is only a multiplicity of single spots. The single spot is at first a red area of irregular outline, never sharply defined, of such a peculiar redness that it might be called the erysipelas of the mouth. The center of the red area may be covered with a whitish or grayish patch which is really due to the superficial destruction or necrosis of the red mucous membrane. Beyond this superficial slough there is still a red zone. It is not unlike a minute gumma in which a central zone of necrosis, surrounded by the red zone of collateral anastomoses of increased vascularity, is recognized. In this stage, because of the little gray or whitish slough, the condition may be confused with leukoplakia, but the

latter is never surrounded by an inflamed and reddened mucous membrane. Leukoplakia and Vincent's angina may appear together. In the next stage the slough comes away and leaves an ulcer. Thus there may be, according to J. C. Bloodgood[5], single or multiple red areas, single or multiple areas covered with a superficial slough, or single or multiple ulcers. Now and then one or more of the ulcers may be quite large, although rarely more than 18 mm. in diameter; usually the single unit areas are only a few millimeters in diameter. The ulcer never looks like a mucous patch, and it never has the ragged excavated edge of the tuberculous ulcer or the induration of the cancerous ulcer. In the very extensive cases, there may be a fibrous exudate not unlike diphtheritic inflammation.

The diphtheritic type as a rule can be distinguished clinically from diphtheria by the fact that, regardless of how diffuse the involvement or how extensive the ulceration and fibrous exudate, the patient does not exhibit toxic symptoms.

The author has never found the organisms of Vincent's angina in a mouth from which all the teeth have been extracted. Apparently the organism can exist only in the crevices about the teeth, and as a rule one does not often see Vincent's angina when the teeth are clean and smooth, when only the enamel is exposed, when the gums have not receded, and when pyorrhea is absent.

On the other hand, it must also be remembered that when one makes routine examinations of mouths, the organisms will frequently be found without any evidence of their presence in a visible reaction of the mucous membrane. Another very important observation is that the finding of Vincent's angina in the cover slips does not necessarily mean that the lesion is entirely due to this type of infection. Whenever there is a benign or malignant lesion of the mucous membrane

(5) J. A. M. A., Apr. 9, 1927.

leading to an ulcer, Vincent's angina may be a secondary invader. In such cases sodium perborate will clear the oral cavity of the organism, but will not heal the ulcer, which may be traumatic, syphilitic, tuberculous or cancerous. But for all those lesions which are entirely due to this infection, sodium perborate properly employed will accomplish a cure—and a rapid cure —in more than 95 per cent of the cases.

The author also differentiates leukoplakia. He believes this condition is caused by tobacco only. Fibromas are of traumatic origin and resemble the tendon sheath tumors. If they are situated in cancer areas it is best to excise them. When situated on the dorsum of the tongue, well within the margin, they may be left alone.

Hypertrophy of the papillae at the base of the tongue is becoming a more common observation. The treatment is the same as for any area of irritation; the cause should be removed. The most urgent causes are tobacco, and dirty, ragged teeth. The ulcer of itself is always suggestive of a malignant growth, especially if tobacco and ragged teeth are predisposing factors. But ulcers may be syphilitic, tuberculous, due to Vincent's angina, or purely traumatic, from the pressure of a plate or the irritation of a tooth. It is a mistake to start treating ulcers with caustics or radium or roentgen ray. The possible causes, tobacco and ragged, dirty teeth, should be removed. If Vincent's angina organisms are present in the cover slips, there should be immediate improvement after a few applications of sodium perborate. The same would be true if the Wassermann reaction is found postive and the ulcer syphilitic after intravenous therapy. In tuberculous ulcer the author has never failed to find tuberculosis of the lungs. In the ulcer due to the pressure of a plate or the injury by a tooth, there should be immediate relief on removing the cause. The writer's experience with ulcer clearly shows that there has been too much local treatment with irritants, rather than a rapid, scientific, sensible removal of causes and

observation of the effect. If an ulcer does not heal after this, it should be looked on as malignant. When the complete excision can be performed without mutilation, then it should be done with the cautery, in such a way that nothing more need be done if the microscopic examination reveals cancer. If the ulcer is larger, a piece may be excised for frozen section diagnosis, to be followed at once by the radical operation with the cautery when the section shows a malignant condition. Tuberculosis may produce a large ulcer even with the induration of cancer.

Geographic tongue is a very typical and striking lesion of the tongue, usually in a single area, now and then in two. The area is a spot on the tongue in which the papillae are smaller. It is like a bald spot on the scalp. The cause of the geographic tongue is not known.

Carcinoma of the Mouth: Types and Degrees of Malignancy. From a practical standpoint carcinomas fall into two general groups, those that arise from the regenerative cells of protective epithelium and are known as epitheliomas or epidermoid carcinomas, and those that arise from the regenerative cells of gland epithelium and are known as adenocarcinomas.

As regards the cause of carcinoma, A. C. Broders[7] believes that irritation plays the lesser, and heredity the greater part in the cause of spontaneous cancer. In grading the malignancy the author uses the same method as reported by him in 1920. A series of 362 cases of epithelioma were grouped as follows: Group 1, the tongue; Group 2, the gums, inside of cheek, lips, floor of mouth; Group 3, the tonsils, and Group 4, the pharynx and hard and soft palate.

The average of malignancy in cases of epithelioma of the tongue (Group 1) is rather high as a little more than half of the cases were classified in Grades 3 and 4. Sixty per cent. of the cases in Group 2 are graded 1 and 2, and 40 per cent. graded 3 and 4. About 94 per

(7) Am. J. Roentgenol., January, 1927.

cent. of the cases in Group 3 were graded 3 and 4, while in Group 4 slightly more than half were graded 3 and 4; the remainder graded 2.

Of the 362 cases 101 were inoperable; practically all of the remainder were treated surgically. Since radium has a greater lethal effect on cells in an undifferentiated or immature state than it has on the mature cells, the author believes that radium is the treatment of choice in the large majority of highly malignant carcinomas of the mouth.

Lesions of the Tongue, with Special Reference to Their Location. Lesions of the tongue are detected

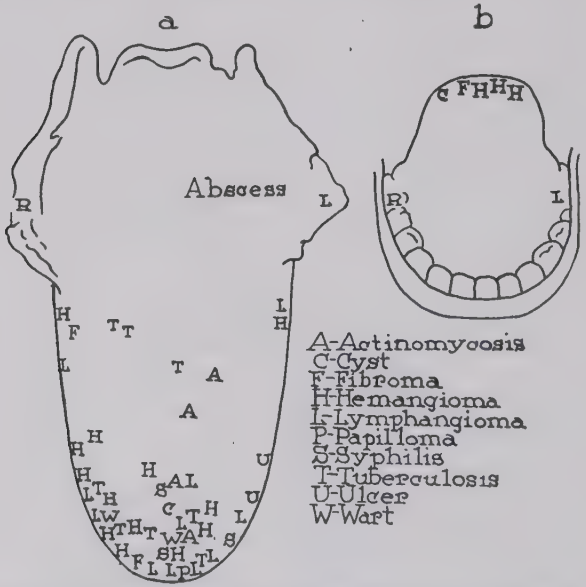

Fig. 26.—*a*. Approximate site of benign lesion on dorsal surface of the tongue; *b*. Approximate site of benign lesions on ventral surface of the tongue.

relatively early because of their situation. However, the results of treatment have not been satisfactory, chiefly because physicians have not appreciated the im-

portance of early accurate histologic, as well as clinical, diagnosis before various types of treatment have been tried. In a study of 250 lesions of the tongue it was apparent to M. Owen[6] that certain types of lesion occurred frequently in rather definite areas (Figs. 26, 27).

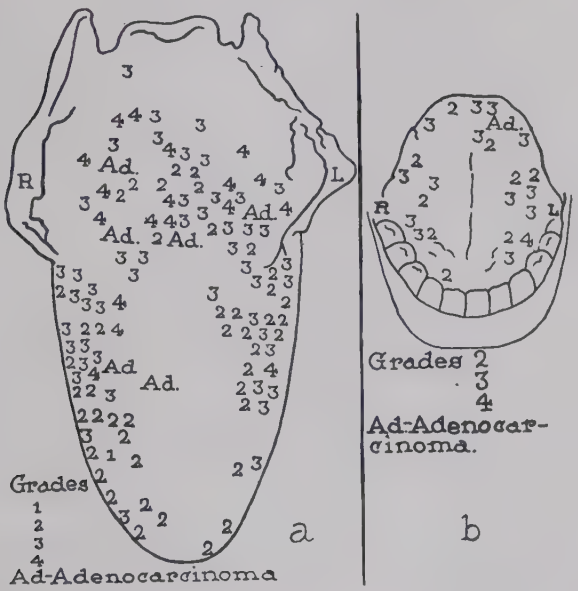

Fig. 27.—Approximate site and grade of malignancy of epitheliomas: *a*. on the dorsal surface of the tongue; *b*. on the ventral surface of the tongue.

The author has found that repeated biopsy is often necessary to establish a definite diagnosis. Almost all of the benign lesions occur on the dorsal surface of the anterior half of the tongue, at or near the tip. Malignant lesions are most frequently found on the base and margins. The only marked exceptions are the epitheliomas associated with syphilis of the tongue. These frequently occur in the middle-third of the dorsum of the

(6) Texas State J. Med., March, 1927.

tongue near the median line. In general, malignant lesions of the tongue nearer the tip are of a lower grade of malignancy and those nearer the base are of a higher grade.

Diseases of the Throat

The Tonsils

Biochemistry of the Tonsils. According to E. Luescher[8]:

1. The method of Warburg permits one to make metabolic tests with a few milligrams of surviving tissue. Therefore it is especially adapted to clinical purposes in making microdeterminations.

2. The method applies to the investigation of the utilization of oxygen (breathing) and of carbohydrate metabolism of the tonsil. The results refer to the behavior in Ringer's solution.

3. The normal tonsil shows considerable utilization of oxygen, and pronounced glycolysis (fermentation) takes place in them. The relation of fermentation to breathing is greater than in all other normal tissues.

4. This holds good also for adenoids. It seems to be a special quality of the germinal centers of peripheral lymph nodules.

5. Not only does the tissue act in this manner, but also the lymphocytes of the tonsil which wander to the surface through the epithelium.

6. The glycolytic effect is not present in salty extracts. Therefore it is not bound, in larger quantities, to extracellular colloidal material or to material in solution.

7. The hypertrophic tonsil differs from the normal tonsil by increased utilization of oxygen and more fermentation (there may be relatively more fermentation

(8) Ztschr. f. Hals—, Nasen—, u. Ohrenh., Dec. 18, 1926.

than oxygen). It presents a hyperfunction and dysfunction compared with the normal.

8. The thymus differs from peripheral lymph nodules by the absence of almost all fermentation. Lymph glands differ also in one person. Some show a relatively considerable fermentation, some almost none. The peripheral lymph nodules show great fermentation continuously, whereas the lymph glands show fermentation only at times.

9. Under certain circumstances, lymphocytes contain a substance of great glycolytic effect, which is bound fast to the cell.

10. Hypertrophic tonsils plainly show involution caused by age. Breathing and fermentation begin to decrease between the sixteenth and twentieth years. They decrease by about one half.

11. Sex has no influence on this metabolism.

12. Seasons seem to have an influence. The rate of metabolism is lower in spring and summer than in winter.

13. The total metabolism of the normal, and especially of the hypertrophic, tonsil is high, compared with that of other organs.

14. On account of their glycolytic quality, the penetrating lymphocytes are probably able to live anacrobically in the presence of hexoses. They keep the surface of the mucosa free from sugar.

(Hence the culture medium for bacteria is less favorable, and their virulence may become less.)

Chronic Tonsillitis. R. F. Nelson[9] has examined microscopically all tonsils removed in private and in clinic practice at Stanford University hospitals in San Francisco for two years, in all about 2,000 pairs, with the accompanying adenoids when present. He describes the microscopic picture of such specimens, giving some new features and emphasizing some old ones. Various workers have touched on many of these points, but this

(9) Arch. Otolaryng., March, 1927.

summary of the pathologic observations is based on the primary inflammatory nature of the changes in the different tissues of the tonsil, and the author does not attempt to make an artificial subclassification of the various phases of this single process. He believes that a clearer understanding of the meaning of chronic tonsillitis is thus derived. A clinical correlation is not appended.

Summary.—A rapid review of the processes gives a composite picture. Infectious menace is first met in the tonsil by an inflammatory reaction and leukocytic migration into the epithelium and space of the crypts and by hyperplasia of the lymphoid follicles; a prolonged encounter of attacking organisms and leukocytes destroys the cryptic lining, and granulation barriers form; by proliferation and contraction of these granulations an attempt is made to obliterate the septic space from below outward, but the depth and ramification may pervert this process so that purulent pockets are obstructed or walled off to form abscesses.

Fibrosis of the stroma commences to strengthen the barrier, but this in time destroys the active elements without extruding the offending matter; as the capsule and peritonsillar tissue become involved in the chronic inflammatory reaction, fibrosis and thickening occur, and cartilaginous and bony walls of defense may develop. However, these barricading efforts of nature seldom succeed in expelling the invading hosts from the cryptic labyrinth, although complete destruction of the essential tonsil structure and extensive degenerative changes may be produced. Simple lymphoid hyperplasia is the most common process in the adenoid; it does not differ from that in the tonsil, although its mechanical effects are of greater moment.

Localization and Diagnosis of Foci of Chronic Infection in Chronic Tonsillitis. Acute tonsillitis spreads in two ways, according to Ruf[1], either superficially as a

(1) Ztschr., f. Hals—, Nasen—, u. Ohrenh., October 6, 1926.

diffuse catarrhal or as a fibro-membranous inflammation, or from a primary defect (ulcer) into the depth of the tonsil, usually from the base of a crypt, resulting in phlegmonous tonsillitis or, if deep enough, in peritonsillar abscess.

The superficial catarrhal form may be followed by resolution and a normal condition may result; the fibro-membranous form results in a subepithelial cicatrix. The ulcerative and phlegmonous forms heal with scar formation. In many cases the healing is not complete, but exudation and proliferation persist as evidence of a chronic irritation, associated with keratosis of the crypt epithelium and infiltration with leukocytes, lymphocytes and plasma cells. The clinical diagnosis of chronic tonsillitis is more difficult. Color, size and consistency are not conclusive; an irregular, torn surface, from the cavities of which abnormal exudate may be pressed, which shows a large preponderance of leukocytes, is of more value. The surest guide is a definite history of repeated attacks of angina. In a chronic inflammation the tendency to resolution is lost.

There are four sites of predilection for chronic inflammation: the upper tonsillar fossa, the lower tonsillar fossa, the supratonsillar fossa and infratonsillar (retroplicar) fossa. The upper tonsillar fossa is often divided from the lower (or sinus tonsillaris) by the plica transversus, which may also divide the tonsil into two distinct parts if two poles are present, or it may only partially divide the two poles. The author's conclusions are based on the clinical history and pathologic conditions in 53 cases.

Chronic Focal Infection of the Tonsils and Accessory Sinuses in Adults. Based upon observation during the past twenty-five years, J. Daland[2] concludes the following:

1. Latent or chronic infection of the tonsils or sinuses is not uncommon in adults.

(2) Ann. Otol. Rhin. & Laryng., December, 1926.

2. Scarlet fever, diphtheria, influenza and streptococcic milk in childhood are often the primary causes of latent or chronic tonsillitis diagnosed late in life.

3. Systemic disease, secondary to chronic infection of the tonsils or sinuses, is associated with leukopenia, lymphocytosis and diminished polymorphonuclear cells in about 40 per cent. of the cases.

4. The presence in pure culture of the streptococcus hemolyticus or viridans in the bottom of a crypt of a tonsil is diagnostic, the importance of which is increased when injections into animals prove that the streptococci possess pathogenicity and selectivity.

5. The presence of bacteria in sinuses possesses additional diagnostic value because these regions are normally sterile.

6. Latent or chronic sinusitis is often an unsuspected focus of infection and often coexists with infected tonsils and teeth.

7. A negative opinion in suspected chronic sinusitis should only be given after repeated examinations.

8. Closed infected ethmoid cells may be the cause of post-operative failure, even when free drainage has been secured.

9. Autogenous vaccines are valuable in asthenia, emaciation, anemia, and the aged.

[It is interesting to get the conclusions of an internist on a problem in rhinology and laryngology, that is usually discussed by specialists. The problem of focal infection should be studied by the otolaryngologist in cooperation with the internist.—Ed.]

Coagulation Time Prior to Tonsillectomy. An analysis of the data studied by W. M. Hunt[3] brings out the following points:

1. There is considerable interest in routine coagulation time prior to tonsillectomy.

2. Sixty-eight per cent. of the 300 hospitals sending replies consider a routine coagulation time advisable.

(3) Ann. Otol. Rhin. & Laryng., March, 1927.

3. Fifty-eight per cent., a little over half, do a routine coagulation time.

4. This 58 per cent. class has come into existence in the past ten years.

5. The most popular method by far is the capillary method.

6. In spite of the increase in the taking of routine coagulation time, little is to be learned from such a test as to post-operative hemorrhage.

7. There is apparently no great legal risk for those who do not follow this practice.

8. Hemophilia occurs only in males and is rare.

9. A coagulation time is not always indicative of bleeding time, and vice versa.

10. Routine coagulation time is desirable to make a full and complete record of the patient while in the hospital, but

11. It is not necessary for the welfare of the patient if a proper history has been taken.

12. A coagulation time should be done on all staff cases unless,

(a) All children admitted for adenoidectomy and tonsillectomy are sent through the children's department for complete history and physicals in consultation with parents prior to recommendation for tonsillectomy;

(b) All adults have thorough history and physicals in both outpatient department and hospital.

13. All doubtful cases should have both coagulation and bleeding time done.

14. Private cases can well be left to the discretion of the attending surgeon.

15. The only apparent advantage of a routine coagulation time prior to tonsillectomy in an institution which has facilities for a thorough history and physical record is for that added margin of safety "when trouble comes."

[A very thorough statement of the problems of protection against bleeding in tonsil operations. A real menace exists. Hemophilia is an unusual cause for serious bleeding and, as the author states, can be detected from the history as readily and as accurately as from coagulation time. However, we quite agree with the author, that for the protection of the institution and of the physician it seems advisable that, as a routine, coagulation time should be made in all tonsil operations, especially on children. This is especially appropriate for dispensary work where a great many of these operations are taken care of.—Ed.]

Coagulation Test. R. McKinney[7] has checked up on the results of the coagulation test in 982 cases. The shortest time was one minute and the longest, eight minutes. The capillary tube and the Bürker slide test were the methods employed, and there was very little disparity between them. The author had practically no bleeding in those cases requiring longer than six minutes for coagulation, whereas the most persistent bleeding occurred in a patient whose coagulation time was only five and one-half minutes.

In persons with hemophilia, one does not expect an increase in the length of the coagulation time, but one does look for prolonged bleeding time. One of the author's patients was a "bleeder," as was shown both clinically and by the history. His bleeding time by test was but four minutes; on the other hand, in another case in which there was no history of bleeding, the bleeding time was between seventeen and eighteen minutes.

With experience so contradictory, it is not surprising that skepticism as to the value of both bleeding and coagulation tests should exist. The writer's own opinion is that such tests have no clinical value, and on scanning the literature he is inclined to believe that this opinion is widely prevalent.

(7) Arch. Otolaryng., August, 1927.

Then, why continue such tests? The answer is that psychology must be considered. The laity has learned that so-called "blood tests" were made before operating, and in private work, frequently the first question asked is, "Do you make a blood test?" An affirmative reply reassures them.

Now if coagulation tests have no practical value, by what is one to be guided in determining whether the patient is a "bleeder"? Family history is the best guide, undoubtedly, but as hemophilia is not a common condition and occurs only in males, many thousands of apparently useless histories would be taken before a case was found. Occasionally one learns of a death from hemorrhage following tonsillectomy; however, in most of these cases the author believes that this occurred, not because the patient was a "bleeder," but because hemostasis was not secured before the patient left the table. He is convinced that his own cases of postoperative bleeding were due to this, and does not believe any kind of coagulation test will aid in the avoidance of postoperative hemorrhages.

[Where an actual condition of hemophilia exists, facts are readily ascertained from the history of bleeding or bruises. Serious bleeding after tonsil operations is just as likely to occur where the coagulation time is somewhat prolonged as where it is shorter.—Ed.]

Further Investigation Concerning the Changes in the Lymph Follicles in Angina Lacunaris. According to R. Waldapfel[5] lymph follicles are free from great quantities of leukocytes in all sections of clinically normal tonsils. At times scarcely a single leukocyte is found in a follicle. In tonsillitis a mass of leukocytes is found in most follicles a day after the clinical height of the disease. In only a few sections did such a focus communicate directly with the lacuna. These foci correspond in appearance and localization with those previously described by the author and Grossmann, in which

(5) Ztschr. f. Hals-, Nasen-u. Ohrenh., Jan. 31, 1927.

they also demonstrated streptococci. At this stage, the epithelium is densely infiltrated with leukocytes, which in some places wander to the surface in masses. These cells are found in larger quantities only in the interfollicular tissue, which contains vessels, and in the so-called germinating center.

During the next few days the picture becomes normal. Large cells appear in the follicles. They contain granules, which are apparently reticular cells, and seem to have absorbed leukocytes which have perished. In the period of convalescence leukocytes can be found only in the superficial layers of the epithelium. The deeper layers are free. The sections show a normal appearance again in less than a week after the disappearance of the clinical symptoms. The lymph follicles and their germinating centers are not exclusively places of production of lymphocytes.

Some Phases of the Tonsil Problem. In this article W. Mithoefer[8] states that it is undoubtedly true that many tonsils have been removed that did not require removal, but is it not likewise true that many patients have died an untimely death as a consequence of infected tonsils when a properly done tonsillectomy might have rescued them? The laryngologist has been impressed with the radicalism of some and the ultraconservatism of other practitioners of medicine regarding tonsillectomy.

It has been the author's observation that the most dramatic results after tonsillectomy have been experienced in those patients referred by the practitioner who has radical views. He has done a tonsillectomy on semi-comatose patients with good results, on a patient with daily attacks of angina pectoris with immediate relief, on diabetics and nephritics with and without good results. Three deaths have occurred, one in a diabetic, two in nephritics with uremia. Some of the most astounding results have been seen in acute poly-

(8) Quart. J. Med., September, 1927.

arthritis following a tonsillitis when tonsillectomy was done in the active stage of the disease. Some of these patients were so ill that they could not be removed from bed at the time of operation.

Conservative methods of treatment such as incision of the crypts, cautery, ultra-violet, diathermy, roentgen and radium therapy, etc., are seldom indicated. As a result of conservative methods of treatment, scar tissue develops in the crypts and retention of pus follows. The author has done tonsillectomies on patients who had undergone a course of *x*-ray treatment and found the tonsils very much adherent and with pus in the submerged upper pole. Roentgen therapy, it is true, will readily diminish in size a non-infected, hypertrophied tonsil. Treatment as well as operation on simple hypertrophy of the tonsil, unless obstructive symptoms are present, is not necessary. It is doubtful whether *x*-ray therapy influences the bacterial flora of the tonsil. It is also questionable if the *x*-ray does not exert a deleterious effect on the parotid gland and the unerupted teeth in children.

The author will probably be accused of having removed many tonsils that were not diseased. He is not willing to admit this to be true, for it is his firm belief that after three years of age there are few tonsils that would not show evidence of disease if carefully examined. However, he is willing to admit that he has done many tonsillectomies without improvement of the health of the patient. If it were not for the unusually good and striking results obtained in other cases these failures would be very discouraging. The author has no patience with the practitioner who does not believe in tonsil operations and can give no reason therefor.

The other extreme of advising every tonsil to be removed is also to be deplored. The author believes that other factors than the results obtained from the tonsil

examination are to be considered in advising tonsillectomy.

In the examination of the patient other factors, such as teeth, naso-pharynx, nasal sinuses, ears and the nasal mucous membrane itself, must receive due consideration before arriving at a definite conclusion. When the teeth and gums are at fault it is advisable to have them treated before doing a tonsillectomy for fear of causing a postoperative sepsis. It must also not be forgotten that not all cases of arthritis are the result of a focus of infection and that gout may be the underlying cause of the arthritic condition.

Also the presence of a hard concretion is no reason for advising tonsillectomy. The most important evidence for their removal is the history of repeated attacks of tonsillitis. This is the strongest indication for the operation. There are many patients, however, who have never had a sore throat in whom there is present a chronic tonsillitis which may or may not be the cause of a systemic complication. Pressure on the upper pole of the tonsil may reveal the presence of soft concretions and pus. If there is any doubt as to the advisability of removing the tonsil, the next step is to express the concretions, if present, and examine them microscopically. Kahler has shown that the microscopical examination of the concretions reveals the fact that in many instances there is present a large number of leukocytes, if the concretion is of the soft variety; whereas if it is of the hard variety, few, if any leukocytes are found. It has been shown that hard concretions contain few if any leukocytes, whereas soft concretions show from ten to twenty leukocytes to the field.

The improved general health of the patient, which very often occurs after tonsillectomy, is, in all probability, the reason for its popularity. The majority of cases who consult the laryngologist for an opinion regarding the condition of their tonsils are not patients who have been referred by the general practitioner. Many

of them have been treated for months by the internist for the relief of neuritis, cholecystitis, albuminuria, anemia, incipient tuberculosis, etc., until finally they become discouraged and seek another opinion. It often happens that there is an improvement in the health of these patients after tonsillectomy, and that happy result makes such an impression on the family and friends that they often, in turn, consult the laryngologist for an opinion regarding a tonsillectomy on themselves. The truth of the matter is that the layman has made the tonsil operation popular. Occasionally one hears that a patient is advised not to have his tonsils removed, inasmuch as the tonsils have a function. When one stops to consider for a moment that the removal of the tonsils, as well as the appendix, does not interfere with the functioning mechanisms of the body, and that the function of the tonsil, whatever it may be, after its removal is readily performed by the pharyngeal mucous membrane, he will realize the insignificance of the above assertion.

[The decision as to the presence of a proper indication for a tonsillectomy is not so simply reached as many assume. Where the question is entirely a local one, recurring attacks of acute tonsillitis, the presence of local findings indicating a type of chronic tonsillitis which constitutes a real menace, the throat specialist is perhaps best able to pass on the condition. That pathological changes are present in all adult tonsils is readily admitted, but this does not mean that all adult tonsils should be removed. Where the indication for tonsillectomy is the presence of a supposed systemic infection and where the local indications may not exist which constitute in themselves an indication for tonsillectomy, the decision should be reached only after consultation with the internist.—Ed.]

Tonsillectomy in Nephritis. F. W. Törne[2] has made a study of the relation between tonsillectomy and nephri-

(2) Acta oto-laryngn., 10:477, 1927.

tis. He had a series of nephritis patients including several different types from whom the tonsils were removed, and a parallel series of nephritic patients whose tonsils were not removed.

The progress of the nephritic patients after tonsillectomy was followed by means of tests for albumin in the urine and the abnormal constituents in the sediment. The author investigated fifty-two cases of nephritis in which operation was performed. Practically all of the patients who showed albumin and abnormal constituents before operation showed a definite increase after operation. Most of them who were free from albumin and abnormal constituents in the sediment, showed one or both after operation. The average time of observation after operation was twenty-nine days for the acute, sixty-two days for the subacute and thirty-six days for the chronic conditions. The author says that during these observations there was no noticeable improvement.

The non-operated series consisted of fifty-six patients treated in the same hospital. They seemed to progress as satisfactorily as the patients operated on.

The conclusion is that definite benefit has not been proved to follow tonsillectomy in subacute and chronic nephritis, and that the operation presents considerable risk as far as the course of the disease is concerned. The author admits that freedom from further infection from the throat is of great advantage and may overbalance the immediate disadvantage.

[This impresses one as a rational and logical way of determining questions, as to whether the removal of the tonsils influences nephritis cases. The literature is too full of observations where improvement of a few cases after operation were taken as evidence that the improvement took place because of the operation.—Ed.]

Tonsillectomy in Singers. Stern[4] advises tonsillectomy in singers on the same indications as in others, but the operative technic must be meticulously careful, cut-

(4) Ztschr. f. Hals—, Nasen—, u. Ohrenh., October 6, 1926.

ting or pulling the soft palate and pillars being avoided. Graded exercises for the voice should be begun within two weeks after the operation.

In nervous singers, and those who have a poor technic, the author advises against operation, as they are likely to develop paresthesias or other psychic disturbances for which the surgeon will be blamed, regardless of how excellent the technical work has been done. When these precautions have been taken, the author has not seen any unfavorable results from the operation, but often great relief from the ill effects of chronic tonsillitis, and an improvement in the voice.

[This discusses an important problem. We have reached the same conclusion: namely, that where a real indication exists for the enucleation of the tonsils in singers, this operation should be carried out and especial care should be taken not to injure the pillars. We have never seen any unfavorable effects on the voice in any of our own work.—Ed.]

Subtotal Tonsillectomy. Subtotal and complete tonsillectomies performed in the hospital Brancoveano are described by E. Daraban[5]. In children under 6 years of age, the tonsil was removed subtotally by the guillotine method. The crushing forceps of Ruault was applied for the removal of the tonsil in adults, under local anesthetic, after dissection of the anterior and posterior pillars. Any fragments remaining were removed with a Hartman forceps. The author contends that the procedure is more rapid, and that less bleeding is encountered than by the American method.

[His conclusion seems to us rather surprising. No other method can be more rapid than the enucleation of tonsils as practiced in this country. Certainly the partial removal of tonsils leaves a condition that is too likely to be of serious future trouble to recommend this operation.—Ed.]

(5) Arch. internat. de laryngol. otol. rhinol., November, 1926.

Postoperative Leucocytosis and Temperature Variations Following Tonsillectomy. The writings of various authors, Schultz in 1893, Busse in 1905, Krumbhaar in 1917, Stahl in 1921 and Witter in 1925, describe a postoperative leukocytosis after various surgical procedures, particularly gynecologic and abdominal. Witter also studied the postoperative temperature reaction in adults and found that it was asynchronous with the leukocytosis.

J. A. Foote and M. Selinger[1] studied the postoperative leukocytosis and rise in temperature in children subjected to tonsillectomy, dividing their material of 147 cases into four age groups. Group 1 consisted of children from 1 to 5 years of age; group 2, those from 5 to 7; group 3, those from 7 to 10, and group 4, those from 10 to 13. Leukocyte estimations were made at two-hour intervals, before and after operation, in children of various ages until eight hours had elapsed and then at four-hour intervals. The graphs of all these observations showed a rapidly increasing postoperative leucocytosis, reaching a maximum after from four to six hours, and remaining at that height for variable periods, depending on the age of the subject. The temperature was also taken, and both total leukocyte and differential counts of blood were made before operation, from four to five hours after operation and twenty-four hours after operation.

A study of this material showed that the average rectal temperature before operation was 99.3 F., five hours after operation it was 99.6; twenty-four hours after it was again 99.3. The data showed that the postoperative variation in temperature in the various age groups was slight and did not parallel the post-operative leukocytosis.

The maximum rise in leukocytosis was found to occur in from four to five hours after operation, regardless of age. The average increase of from 3,000 to 4,000 leukocytes may be expected five hours after tonsillectomy.

(1) Am. J. Dis. Child., January, 1927.

The Injurious Results Frequently Following Tonsillectomy. C. C. Rice[6] mentions some of the injurious results which frequently are caused by tonsillectomy. The operation is nearly always followed by a severe grade of dry pharyngeal catarrh, especially of the postnasal region, a very annoying condition and a great impediment to the singing and speaking voice.

The removal of tonsils, capsule and all is a grave anatomical shock to the pharynx and larynx by reason of the sudden lessening of blood and nerve supply and the substitution of scar tissue for a normal moist mucous lining. This is followed by surface dryness all the way from the vault of the pharynx downward, and such catarrhal dryness quickly extends to the larynx and the trachea.

Postnasal disturbance, too, is a very potent predisposing cause of colds in the head. This dry catarrh, always accompanied by collections of mucus, is so annoying to the average patient that he constantly consults his physician, and is obliged to follow perhaps for life a local treatment of washing and oiling the nose and throat. The author is considering the nonprofessional person who uses his voice only in conversation. However, this sudden anatomical change in the formation of the pharynx is much more harmful to singers, actors and speakers.

Other injuries results from tonsillectomy are the serious deformities of the pharynx. The writer believes that such injuries cannot be avoided no matter how skillful the operator may be. The most experienced physician cannot determine the degree of traction which the pharyngeal pillars will exert on the soft palate as the wounded surfaces heal and contract. Frequently, unintentionally of course, the pharyngeal muscular pillars are so excised that they are seriously shortened and then the traction on the soft palate becomes still greater. The lateral pharyngeal muscles are so taut as to be almost

(6) M. J. & Record, Apr. 6, 1927.

immovable, and the soft palate drawn so far forward, that it would seem impossible for it to meet the posterior wall and close the postnasal cavity.

The author questions whether the presence of so-called diseased tonsils—a term which is much too freely used —have shortened life. Is it proved that people who have occasional attacks of tonsillitis are peculiarly susceptible to rheumatic affections and heart disease? Is the ordinary appearing tonsil, which today is being removed a potent factor in increasing blood pressure? In a practice extending over many years the writer's observation is that these points are far from being proven. There are so many other pathological conditions which bear a much closer causative relation to the general diseases, that it is difficult to believe that the tonsils play any very important part. Many of the tonsils removed today can undoubtedly be acquitted of harmful influence upon the general health.

The author hopes the time will come when physicians will feel that the old time tonsillotomy operation, when properly done, was sufficient to remove overenlargement and congestion, for this procedure was not followed by dryness and deformity, and that the portion of tonsil that remained after this operation acted as a conservative protection to the throat, and its presence gave less annoyance than a dry tonsillar cavity.

Of course there are many tonsils which should be made smaller, congestion reduced, and the follicles destroyed, so that they no longer can be receptacles of pus, cheesy material or detritus of any sort, and also all functional activity, if it exists, which is doubtful, be made to cease. It will answer every requirement when one has transformed this organ, which is no longer performing any beneficial function, into a harmless collection of connective tissue.

This can be accomplished by the skillful conservative use of the electric cautery, instead of performing the radical tonsillectomy which so often is followed by

harmful results. The platinum point, at any heat required, will diminish the size, reduce the congestion, and destroy the follicles of such tonsils as require to be treated. This result can be attained without hemorrhage and with far less soreness of throat than when cutting is done. No dry catarrh and no deformity of pharynx follow this mode of treatment.

[We would change the title of this article to "Some Unusual Results or Exceptional Results of Tonsillectomy." We, ourselves, have seen just what this author describes, but only in exceptional cases and then of short duration; a period of months usually suffices for its entire disappearance. As regards the deformities, these are more conspicuous from their appearance than from their symptoms. It is only the very unusual deformity that produces anything but transitory symptoms. The old type operation was given up for good reasons. Tonsil stubs left after the old operation of amputation, tonsillotomy, frequently remain the seat of recurring acute tonsilitis or a persisting focus of chronic infection. The advice to use the galvano-electric cautery strikes us as most inadvisable. To sear over the surfaces of the tonsils by cauterizing them only tends to increase the risk from buried foci of infection.—Ed.]

Irradiation of Diseased Tonsils. In the implantation of removable platinum radon seeds J. C. Seal[7] believes we have an adequate substitute for tonsillectomy in those cases where surgery is, for any reason, contraindicated.

1. The amount of radiation can be measured with accuracy and the applicators located with such exactness as to insure equal and complete distribution throughout the tissues.

2. Only one treatment is necessary, a fact much appreciated by the patient.

3. The platinum filtration eliminates all danger of necrosis with subsequent sloughing of the tissue, systemic reactions of any kind never occurring.

(7) M. J. & Record, Dec. 1, 1926.

4. The attached thread, making the seed easily removable when its period of usefulness is completed, does away with the objectionable foreign body remaining permanently in the tissues—a drawback of the bare tube method.

5. There is no hospitalization, nor disability of any kind. No anesthetic is necessary, yet there is no pain, nor suffering of any description. The complete absence of shock is a great advantage in those cases classed as inoperable.

[We agree with the author that irradiation is called for where, for adequate reasons, the enucleation is inadvisable. This situation rarely, however, arises. Experience, so far, in removing the tonsils of adults by irradiation, while it has resulted in a lessening of the size of the tonsils, has not apparently been able to eliminate these structures as possible foci for systemic infection. It may not even eliminate the annoyance of risk from attacks of acute tonsillitis. One should not lose sight of the fact that in chronic tonsillitis there frequently results over-development of connective tissue and elimination of the lymphoid or parenchyma. This result, however, has not eliminated the tonsils as a focus for infection.—Ed.]

Treatment of Diseased Tonsils by Means of Radium. The new removable platinum radon seed is a means of administering a definite dosage of radiation, of insuring complete elimination of necrosis and sloughing and of doing away with the presence of a permanent foreign body in the radiated tissue.

In cases in which there have been repeated attacks of severe tonsillitis in acute infection, the results of radiation may not be so marked. This is undoubtedly due, according to J. C. Beal[8], to the fact that radiation exerts its effect on the lymphoid tissue only, and when because of repeated inflammation the tonsil has become fibrous, this tissue remains more or less resistant to

(8) Arch. Otolaryng., February, 1927.

radiation. In such tonsils, however, there is a gradual process of atrophy and disappearance of the crypts, as well as elimination of the focus of infection. To sum up, it is the author's opinion that the results obtained indicate that we now have a satisfactory method of removing diseased tonsils without the risk of fatalities in inoperable cases.

In the cases reported it was seen that in the first group, in which the tonsils were treated by radium needles, in addition to the pain and gagging while the needles were kept in the tonsils for three hours, the results were not ideal. The lower poles did not receive any radiation in several instances, while a great many patients had a reaction lasting three days.

In the second group of cases in which the patients were treated with glass radon seeds, the results were better. The pain and gagging were done away with; the only objections were that the implantation necessitated from six to eight punctures, and the glass seeds had to be left permanently in situ so that they acted as foreign bodies; a slight reaction also followed implantation. The damage that these seeds would tend to do as foreign bodies is still, of course, only conjecture, as experience with this method of treatment is still insufficient to permit generalization. The reaction noted was undoubtedly due to the lack of complete screenage of the capillary glass tubes.

In the third group of cases in which the patients were treated with removable radon seeds, the ideal method appears to have been employed. In the first place, sufficient radiation is obtained by implanting only one seed instead of the three glass seeds before required; second, the seed can be removed, doing away with the presence of a foreign body; finally, no reaction was noted in any case, the platinum screenage being sufficient to prevent burns and necrosis.

Treatment of Tonsillitis with Sugar. E. Koenigs-

berger and S. Mussliner[9] discuss the treatment of tonsillitis, diphtheria, and Vincent's angina. They have obtained particularly good results in the treatment of tonsillitis by the local application to the tonsils of sugar. The sugar is applied in the form of powder or in a 30 or 40 per cent. solution. The same treatment was found to be beneficial also in diphtheria and Vincent's angina, in conjunction with the usual serum and other treatment of these diseases.

Hemorrhage Following the Removal of Tonsils and Adenoids. W. J. McNally[4] reports on the operations performed in the Royal Victoria Hospital during the year 1926. The results of the study show the following:

1. In this series of 1,416 cases of tonsillectomy and adenoidectomy secondary postoperative hemorrhage was more common than primary postoperative hemorrhage.

2. Postoperative hemorrhage, both primary and secondary, were more common following the guillotine method of tonsillectomy than following the dissection and snare method of operation.

3. There was no primary postoperative bleeding from the adenoid bed. Every case of bleeding from the adenoid bed was of definite secondary hemorrhage.

4. All cases of primary postoperative hemorrhage occurred within the first six hours after operation. Eighty per cent. of the cases of secondary postoperative hemorrhage occurred within the first seven days after operation.

5. Out-of-town cases should be kept in the city at least eight days after operation for re-examination, owing to the danger of secondary hemorrhage.

[The rare occurrence of a serious bleeding later than 24 hours after a tonsil operation would hardly seem to warrant ultra conservative advice regarding hospitalization. The matter should always be presented to a patient, so that he would know what to do if he should be troubled with bleeding after leaving the hospital.—Ed.]

(9) Deutsche med. Wchnschr., Feb. 11, 1927.
(4) Canad. M. A. J., June, 1927.

A Method which Insures the Practical Control of Hemorrhage in Connection with the Operation of Tonsillectomy. The method which W. A. Wells[6] now employs and which he advises giving the best guarantee against the continuance of primary hemorrhage or the occurrence of secondary hemorrhage, consists briefly in

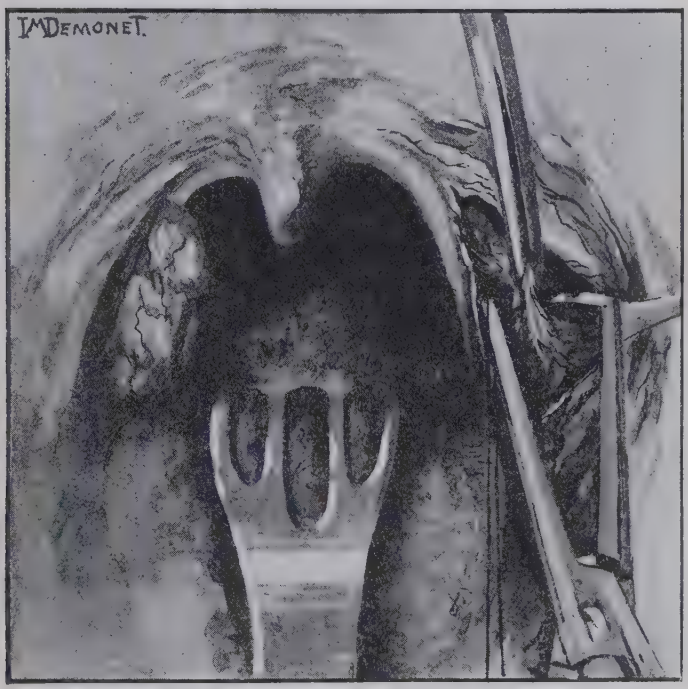

Fig. 28.—Instrument ready to place suture through tissue pinched up by hemostatic forceps.

the placing of suture ligatures by means of a special instrument in certain designated points and in a particular way. This should be done as a routine procedure (Figs. 28, 29).

(6) M. J. and Record, Aug. 17, 1927.

Certain points represent the most frequent sites of tonsil bleeding, corresponding as they do to the places where vessels penetrate the fossa or at least are most likely to be severed in the operation of enucleation.

Fig. 29.—Showing thread through tissue. Released from instrument on one side, it is held in eye of needle on the other, to be drawn outward through the mouth.

Of these the most important is at the upper pole, under the angle of the juncture of the two pillars, the bleeding being due to a wounding of a descending artery formed by the anastomosis of the ascending and descending palatine, probably the largest of the branches of this area. In every case this vessel should be ligatured, even

though the bleeding at the time seems negligible, if one values security from further trouble.

The point of second importance from the viewpoint of the troublesome hemorrhage is in the lower pole of the tonsil often quite close to the base of the tongue. In adults a ligature should as a routine be placed also at this site. If there is the least indication of bleeding at the point indicated in the central area of the tonsil bed, there is the place for a third routine ligature.

The point of fourth importance is in the lower half of the posterior pillar due to a lesion of the ascending pharyngeal vessel which in some cases may be exceptionally large. For grasping the tissue in which the bleeding vessel is contained, one should employ a slightly curved hemostatic forceps, with a broad rather than a sharp point. Held by an assistant or in the left hand of the operator, traction is made upon the tissues by the hemostat and a suture immediately placed just beneath the level of the grasp. It is also quite feasible in many instances to place the suture through the tissues without having first grasped them with the hemostat.

The position of the suture relative to the vessel and to the bleeding point is a matter of prime importance. As the vessels in the tonsil area run in a vertical direction the suture to engage them properly should be carried in a transverse direction. Furthermore, it is a point worth remembering that as the bleeding in the region of the upper pole comes from a descending vessel and all the other bleeding points from ascending vessels, the ligature in the former case should be placed above the bleeding point, in the latter case below it. By the use of the suture placing instrument, vessels can be ligatured with almost no loss of time. This means a shortened anesthesia, and a shortened anesthesia means much to the patient in the avoidance of shock and delayed convalescence.

The saving of blood is not always in itself so important, but the ill effects of great amounts of blood are

sometimes to be avoided, and besides we have to reckon with the possibility of a serious complication from presence of blood in the chest. In children, and in adults already anemic the mere loss of blood may be a serious handicap.

It may be remarked that the time consumed in the operation of tonsillectomy is not so much for the mere cutting or removal of the organs, but rather for the control of hemorrhage. The strictly surgical work required for the removal of both tonsils can easily be done in three to five minutes, but one needs to devote at least twice that time to the hemostasis; and he who slights this latter duty, may find that he will have to pay for it by a sacrifice of much more time a few hours or days later.

An advantage in attacking the problem of hemorrhage in the manner described, is, that it saves time, it saves blood, it lessens the likelihood of complications, and it is the best possible guarantee against recurrence of post-operative bleeding. Besides practically eliminating the possibility of death from hemorrhage, it lessens the chances of accident from the anesthetic. It removes the chief cause of painful postoperative treatment, and it tends to avoid a tedious and prolonged convalescence

Ligation of the vessels of the tonsil area is after all the only procedure which gives the surgeon a sense of security against the continuance of hemorrhage, or its recurrence. There are many surgeons who will see the advantage of ligaturing the vessels in cases in which there is manifest bleeding, who will, however, be averse to its employment as a routine measure. But when one considers that the sutures can be so easily placed and in less time than is ordinarily required to stop the bleeding by pressure there seems really no good reason in any case for omitting the procedure. One needs only to think of the discomforts and disadvantages of post-operative bleeding, not to mention the more serious haz-

ards, in order to have an excellent argument in favor of its use.

New Instrument Producing a Bloodless Tonsillectomy. According to F. P. Herman[7] his instrument has the original loop; it has the bowl, which acts as a receptacle for the tonsil after it has been severed from its base, thereby eliminating the use of the tonsil-seizing forceps, plus a most important additional action, in that it collects the pus and other débris which is always in

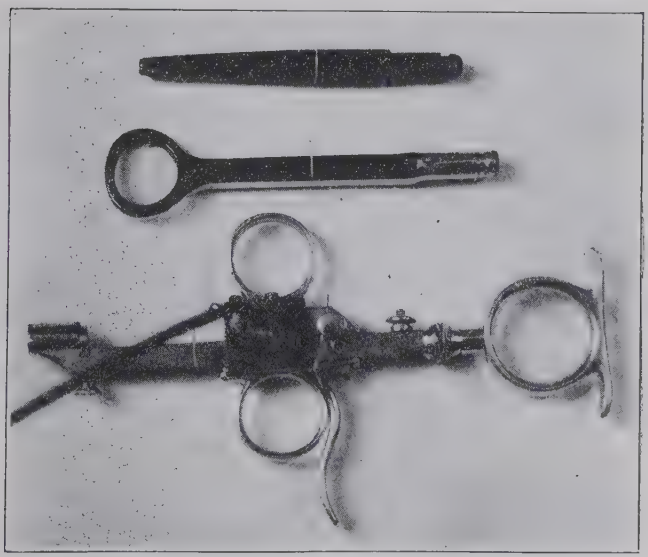

Fig. 30.—Herman's instrument producing bloodless tonsillectomy.

evidence when the tonsil is involuted through the loop. Such substances frequently give rise to fatal complications resulting from aspiration. (Figs. 30, 31.)

It has the suction application, which enables one to engage the tonsil without a great deal of pressure against the anterior pillar (an act that sometimes causes considerable trauma, with resultant delayed convalescence).

(7) J. A. M. A., Sept. 24, 1927.

It has the electrocoagulation feature, which brings about the bloodless postoperative condition. By virtue of this coagulation, any microscopic cells, which are frequently left and result in new lymphoid growths, are destroyed. Further, by the sealing of the blood and lymph vessels, any local infection of the wound and also the production of blood stream infections or metastatic complications are prevented.



Fig. 31.—Herman's instrument.

It renders the act of removing the tonsils just slightly inconvenient, with nothing to be feared on the part of the patient and a real surgical pleasure on the part of the operator.

The efficiency of this new procedure is amply proved, as the usual deep general anesthesia is no longer necessary. The patient is simply relaxed with nitrous oxide sufficient to open the jaws with the gag, the right tonsil is engaged, and the current is turned on with the foot switch. The snare is drawn through the base at a fairly rapid rate; this is accomplished with considerable ease, as the current itself is of the cutting type.

The instrument, containing the tonsil, is removed and the anesthesia readministered in sufficient amount to relax again, and the left tonsil is secured in a like manner. It is possible to operate on most adults under local anesthesia. When the latter method is used, an acetylsalicylic acid tablet dissolved on the tongue immediately following operation takes care of the pain attendant for a short time following the application of this type of current.

Following this procedure, the patient with hemophilia, diabetes or hypertension should cause no more concern than the ordinary patient.

[Since this article was published in the Journal the author has revised the technic to the extent that instead of placing the inactive electrode in connection with the large damp on any part of the body, he is now using an insulated tonsil seizing forceps to which the inactive electrode is attached. This modification of technic prevents any penetration of the tonsillar fossae, thereby eliminating any subsequent sloughing and oozing.—Ed.]

A Ligature-Carrying Tonsillar Hemostat. The advantages claimed for this new instrument, described by A. J. Smith,[3] are that it combines the hemostatic forceps and ligature carrier in one instrument, and with it the operator can ligate vessels without assistance other than that necessary to expose the field of operation. (Fig. 32.)

The forceps differs in no respect from the curved tonsillar hemostats in common use. The ligature carrier is a movable rod slightly shorter than the forceps, which by means of outriggers attached to the forceps is held in position parallel to the latter. This rod has a small opening at the distal end through which the ligature is threaded, and at the outer end a groove to receive the long arm of the ligature to prevent entanglement.

The construction of the instrument is such as to permit this rod to slide in the direction of its long axis back

(3) Am. J. Surg., July, 1927.

and forth over the face of the forceps. When drawn back the carrier locks in position and in no way obscures the tip of the forceps from view. This is the position of the carrier when the vessel is grasped, after which, by pushing in on the outer end of the carrier, it is made to glide along until the eyelet passes the tip of the forceps by approximately three millimeters. This eyelet acts as a pulley through which the ligature travels, and is of sufficient size to permit the ligature to run smoothly without undue friction.

Fig. 32.—A ligature-carrying tonsillar hemostat.

To tie, the bleeding vessel should be grasped in the point of the forceps, the carrier pushed in as far as it will go. While holding the carrier in this position traction must be made on the long arm of the ligature, when the loop will slide down over the point of the forceps and engage about the vessel. Before the loop actually engages, the forceps should be drawn away sufficiently to put the tissues slightly on the stretch. Firm traction is continued until the loop closes tightly. The ligature is then severed close to the point of the forceps, the carrier withdrawn and forceps released.

Technic of Tonsil Electrocoagulation (Diathermy). In this article G. A. Dillinger[5] reports a series of one hundred and fifty cases. The author uses a machine giving 1,750,000 oscillations per second. He states that the electrocoagulation is an office procedure. The patient is seated in any kind of office chair desirable, and a

(5) M. J. and Record, May 18, 1927.

large piece of block tin, six inches by ten inches, is applied to the bare skin of the patient's back and connected by an insulated cord to the machine. A ten per cent. solution of cocain is used, the cotton on the application being moistened only once with the solution. This is quickly applied to the soft palate, around the tonsil, inside the cheek and the base of the tongue, repeating this five or six times with the same pledget of cotton, but no additional cocain. No more than four or five drops are used for the whole procedure. Now the throat and tongue are sufficiently anesthetized. The author has never had a patient faint nor show the slightest sign of syncope. He never injects novocain for three reasons. First, there is the slight danger from the anesthetic; second, more fluid is added to the field which one wishes to dehydrate; third, there is about as much reaction from the fluid injected into the soft tissues as from the diathermy.

The author takes the needle, usually the end slightly curved, and puts it from one-eighth to one-quarter inch into the tonsil, and steps on the foot switch, and in from one to two seconds the white ring appears around the needle. He then releases the current and takes out the needle. This procedure is repeated until the tonsil has been covered with punctures about one quarter inch apart. The number of punctures varies according to the size of the tonsil. The author often uses on large tonsils as many as twelve to fifteen. The tonsil is now painted with some acriviolet, and the patient goes right on with his usual routine of the day.

The author's usual practice with patients who live in the city is to treat only one tonsil at a sitting. In eight or ten days the patient comes back, the tonsil operated upon has from fifty to seventy-five per cent. disappeared, and the other tonsil is treated. Both tonsils can, of course, be treated at one sitting and can be entirely removed with one treatment, but there will be, of course, great reaction and the patient is more

uncomfortable than when only one tonsil is treated at a time. Giving two or three treatments to each tonsil is preferable, and they are removed with no great inconvenience. The author has not had more than four or five patients who have gone to bed for a day, or who have had any temperature, or who have missed their three meals a day, or who have missed any time from school or business.

The author believes that those who criticise his method have not given it a fair trial or else know absolutely nothing about it. He would advise no one to attempt this method who has not seen someone perform the operation a number of times and learned the little tricks of technic, which are so great a factor in getting good results. At the present time he knows of no university or medical school in this country where this experience can be had.

In conclusion the author states that with local application of cocain as described, and with proper technic, following the method of treating one tonsil at a sitting, making two or three treatments to each tonsil about eight days apart, one will have nothing but success, with disappearance of the tonsil, with absolutely no danger to any other structure, and all objectionable features of tonsillectomy removed. The patients will be free from their foci of infection and constitutional symptoms, and yet they have been subjected to nothing more serious than an occasional sore throat.

The author also calls attention to the fact that too many tonsils are being removed, especially in children, for the tonsil certainly has a very important function to perform during the period of growth and development. There is an intimate connection between tonsils and the thyroid, and between the thyroid and ovaries, testes, and other glands.

[We wonder what evidence the author has that the tonsils are such an important organ in childhood, where the tonsils frequently become such a serious menace to

children not over 2 years of age. We have never heard of any evidence that the child, after his tonsils had been removed, showed that he had been deprived of some functioning organ. We wonder whether the electrocoagulation (diathermy), as advised by the author, is not likely to leave a condition analagous to that left by the cautery puncture commonly used a few decades ago. It was frequently observed in these cases that the scarring of the surface seemed to be responsible for making a tonsil more susceptible to infection.—Ed.]

Electro-Coagulation as an Adjunct in Tonsil Dissections. W. H. Taylor[9] states that hemostatic preparation of tissues prior to cutting them is the outstanding feature of the method. Otherwise, the technic does not differ materially from that of ordinary tonsil dissection. The mucous membrane covering the pillars is first of all divided. This does not require coagulation, since bleeding from this source is negligible. The tonsil is drawn forward and, one after another, each band of tissue between the pharyngeal wall and the capsular membrane is grasped between the scissor blades and coagulated; the current being controlled by a foot-switch; and along the line of coagulation each bite of tissue is severed by closing the blades.

In this way the dissection may be carried out bloodlessly; or with no more bleeding than is incidental to the incision in the mucous membrane, or to the separation perhaps, of a piece of friable tonsil in the teeth of the tonsil-holding forceps. The use of the snare is dispensed with, since the tonsil is severed, in the same bloodless manner, at its base.

Not the least of the advantages afforded by this method is the visibility of the structures dealt with, due to the unaccustomed dryness of the operative field.

Molt and Storz Modification of the Tonsil Guillotine. As it is a mechanical impossibility to make a blade that will fit perfectly into a rigid ring instrument, W. F.

(9) Canad. M. A. J., February, 1927.

Molt[1] therefore conceived the idea that a flexible steel loop could be placed into the ring end of the guillotine so that when the blunt blade was driven home by the special thumb dog, an even pressure would be exerted at all points of the blade and a complete enucleation obtained by the use of the thumb pressure alone. A

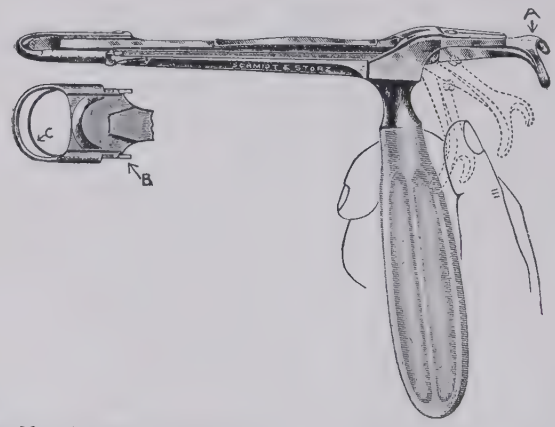

Fig. 33.—A tonsil guillotine: *a*, special thumb dog; *b* and *c*, show resilient loop partially removed.

special constructed lever which is a part of the blade itself makes it possible to exert all the pressure necessary with the thumb.

The blade and the carrier have been so constructed that this instrument takes up much less space in the mouth than the ordinary guillotine. (Fig. 33.)

The Pharynx

Experimental Sore Throat. In 1921 and 1923 G. F. Dick and G. H. Dick[6] showed by experiments that the scarlet fever streptococcus may cause sore throat without exanthem. They now have demonstrated that the hemolytic streptococcus found in erysipelas may cause

(1) Laryngoscope, October, 1926.
(6) J. A. M. A., Oct. 1, 1927.

acute anginas resembling ordinary sore throat or tonsillitis without the skin manifestations of erysipelas.

Scirrus Carcinoma of the Throat. W. R. Watson[2] in reporting this case states that he finds no report in the literature since 1893 of a similar tumor in the throat.

The patient was a white woman, aged 25, whose family and personal history was negative except that she had her tonsils removed at the age of 15 years. The present complaint was that there was a swelling in the right tonsil region which interfered with swallowing and phonation. It had been present since the tonsils were removed, but began to grow progressively larger during the past year.

On examination a hard nodular mass was seen externally, palpable below the angle of the jaw and inward almost to the midline. Intraorally a smooth tumor was seen whose mass crowded the soft palate down to the left and so large as to almost fill the pharynx. The tumor was slightly movable, as though encapsulated. The Wassermann was negative on three examinations and mixed treatment had no effect on the tumor.

A biopsy was made, and on cutting into the tissue the knife slipped into a cavity, from which a bloody fluid escaped. The report on the biopsy being questionable, a second one was made, but this also proved unsatisfactory. Finally the tumor was totally removed, enucleating out along a definite line of cleavage. The pathological report on this proved it to be a scirrus carcinoma, with the cells running in indistinct cancer columns.

At the present time there has been no recurrence in the throat.

Pemphigus of the Throat. Since a previous report A. H. Rubenstein[3] has had a second case which closely resembled the first. As cases of acute pemphigus are still infrequent, the two cases are of enough importance to

(2) Laryngoscope, October, 1926.
(3) Arch. Otolaryng., April, 1927.

warrant a review and a comparison of their outstanding factors.

Both patients were men, one, aged 54, the other, aged 39; both were Russian Jews. The first symptoms shown by the patients were lesions in the mouth, developing shortly after the removal of a tooth; the lesions were widely distributed over the lips, gums, pharynx and larynx, although in the second patient the larynx was much more involved. The lesions were ulcerated, irregular, macerated and bleeding, the macerated mucosa giving the appearance of a pseudomembrane. Vincent's organisms were found on repeated smears; blood Wassermann tests were negative. Dermatologic lesions developed in the first patient three weeks after the appearance of lesions in the mouth, while in the second patient they developed in eight weeks. The first patient died in five weeks; the second patient is still alive, but septic. He has periods of remission, but death will probably result from the condition.

A characteristic odor of the breath, which was emphasized in the report of the case of the first patient, was detected on the breath of the second patient, and because of this, the possibility of pemphigus of the throat was suggested on the first day. The breath of both patients had a pungent, raw flesh odor. The author has never previously detected this odor in cases of ulcerative lesions of the mouth and pharynx. He cannot say how much importance should be given to this symptom in making a diagnosis, and he does not assert that it is characteristic of pemphigus of the throat.

The organisms of Vincent's angina in the throat may be present as saprophytes as are streptococci. As much caution should be used in diagnosing lesions of the mouth as Vincent's angina as in diagnosing as septic pharyngitis every condition of the throat which shows streptococci in the cultures. Vincent's ulceration should be diagnosed from the appearance of the lesions, with a

minimal consideration of the results of the laboratory examination.

A Case of Retropharyngeal (? Tonsillar) Myxosarcoma Observed During a Period of Twenty-two Years. D. M. Greig's[4] patient was a married woman, 33 years old, who in 1901 noticed a swelling in the region of the right tonsil. Several biopsies made of the lesion at that time were diagnosed myxosarcoma. Inflammation of the tumor occurred, but after subsiding, the patient apparently entirely recovered.

In 1913 the patient complained of a swelling in the right side of the neck, which, though she had noticed an enlarging gland there for eight years, had only begun to trouble her during the last eighteen months. The author found a mass of well-defined, moderately soft glands occupied the right side of the neck in front of and deep to the upper half of the sternomastoid, passed forwards in the submandibular region to the chin, and within the mouth a semisolid mass pushed the soft palate forwards and the right tonsil and the uvula across the middle line. A fortnight later, under chloroform anesthesia, through a curved incision extending from the chin to the mastoid and descending as low as the hyoid, a mass of fairly firm enlarged glands, the size of an orange, was removed. The glands extended well down the neck, and upwards over the mandible into the parotid region to the level of the tragus where an additional incision was required. The pharyngeal wall was not infiltrated nor apparently was the tonsil affected, and therefore the pharynx was not opened though a preliminary laryngotomy had been done with the expectation of a pharyngeal extension. The wounds healed rapidly and in three weeks the patient was discharged from the hospital. The pathologist reported that the recurrent tissue was typically sarcomatous, the myxomatous element being only moderately developed.

The author examined this woman for the last time in

(4) Edinburgh M. J., October, 1926.

December, 1920. She was then 51 years of age, somewhat plethoric and stout, but in excellent health and spirits. The scars on the neck and cheek and in the mouth were the only indications of her serious illness. The greater part of the right tonsil remained and appeared normal. Since then the writer learned that three years later, having gone into the country to reside with a relative, the woman died at the age of 55, and that the cause of death, so far as could be ascertained, had no relation to her sarcoma.

Torula Infection of the Nasopharynx. Torula is the name given the pathogenic yeasts which closely resemble the oidiomycetes (blastomycetes). Of the 21 cases reported in the literature, 18 have involved the cerebrospinal nervous system and have manifested symptoms entirely cerebral in character. This case reported by E. Lloyd Jones[5] is of interest, first, because of its rarity, since no case of torula infection producing gross destructive lesions in the nose or throat alone has thus far been reported. Secondly, it shows the possible relationship between a fungus infection in the tonsils and nose, and the brain cases. Thirdly, it is difficult to differentiate this lesion from the lesions of syphilis, tuberculosis, carcinoma, and oidiomycosis (blastomycosis); and fourthly, the disease has been invariably fatal in the brain and lung cases, whereas the author's case is now an arrested condition.

The patient was a man, 34 years of age, who had his tonsils removed in March, 1923, because of chronic tonsillitis. In March, 1924, the right ear became deaf. Difficulty in breathing through the nose had been present for some time previously, but as the onset was insidious it had caused little concern. There were several swellings in the roof of the mouth which made their appearance shortly after the removal of the tonsils, and as they caused no annoyance they received no attention. These swellings became tender and increased in size at the time

(5) South M. J., February, 1927.

the right ear became deaf. The left ear became deaf in August of the same year.

Examination.—A functional test of the hearing revealed a partial loss of hearing due to pathological changes in the conductive apparatus. In the nose the posterior end of the septums was so thickened that inspection was impossible beyond the anterior half of the nasal cavities. No tonsillar remains could be seen.

Fig. 34.—Drawing of the throat as seen in November, 1924.

There was a moderate amount of scar tissue in both fossae. On the right anterior pillar were two nodules about 6 mm. in diameter, slightly elevated. Over the soft palate and the posterior portion of the hard palate were six similar nodules producing an undulatory appearance of the surface (Fig. 34). The mucosa covering these nodules was unusually pale, yellowish-white, as

though an abscess were beneath. The nodules in the palate were slightly tender to the touch. No inflammatory reaction was present. There was no evidence of any acute infectious process or ulceration. By mirror and palpation the soft palate was found to be much thickened. Extending upward into the nasopharynx on both sides were tumor masses about 2 cm. in length attached to the lateral pharyngeal walls with a broad base just in front of and below the eustachian tube orifices and completely blocking off these tubes. One of the nodules on the right anterior pillar was removed for microscopic study and a specimen of blood was taken. General physical examination was negative. Roentgenograms of the chest were negative. The temperature was normal.

The blood Wassermann was reported one plus, but tissue examination revealed nothing suggestive of syphilis or tuberculosis. The pathologist felt that was a low grade chronic inflammation such as is produced by a foreign body or other mild but constant irritant.

The patient was placed on antiluetic treatment but instead of improving, the lesions commenced to ulcerate. By the end of December the uvula and central half of the soft palate were missing. Following this consultation was obtained, several biopsies taken, but no definite diagnosis was made. Ultra-violet ray treatment had no effect. Surgical removal with cauterization carried out five times resulted only in recurrence.

In April, specimens of the sputum, while negative for tuberculosis, showed yeast cells. The cultural characteristics identified this yeast as torula. Roentgen ray treatment was finally adopted in view of the diagnosis of the torula and the nodules disappeared. The mucoid discharge from the ears, which had developed several months previously, ceased entirely. The lesion has appeared healed for seven months and the author considers the case arrested, at least until more time has elapsed. In summarizing he states that the condition

is that of a destructive lesion in the palate and nasopharynx due to the yeast.

Lesions by this yeast are rare, most commonly occurring in the central nervous system, and are preceded by similar infections in the nose or throat.

The organism must be differentiated from the oidiomycetes and coccidioides by cultural studies and the gross lesion from lesions of syphilis, tuberculosis and carcinoma by biopsy when possible.

Nothing definite has been shown in the way of treatment. Roentgen rays are given credit for arresting the present case.

Pathologic Anatomy of Malignant Tumors of the Nasopharynx. Primary malignant tumors of the nasopharynx are rare. Round and spindle-cell sarcomas are found comparatively seldom, lymphosarcomas more frequently. Most carcinomas are squamous epithelium tumors, frequently of the indefinite type. Trotter thinks that endothelioma is the most frequent type.

Among 7,051 necropsies in Muenchen-Schwabing, studied by L. Singer[3] during the last ten years, only five cases of primary malignant tumors of the nasopharynx were found; one sarcoma, two carcinomas and two other tumors which could not be classified definitely. The disease took a rapid course in all cases, lasting from nine to ten months. In four cases the tumors seemed to originate from the lateral wall of the pharynx.

In one case the origin appeared to be at the base of the cranium, because the sphenoid and the posterior wall of the pharynx were destroyed, and because the lateral walls of the pharynx were less affected. The tumors had penetrated into the nasal cavities, especially into the ethmoid cells, and had involved the palate, nasopharynx, the base of the tongue, the retropharyngeal tissue of the neck on one side, the middle ear, the middle cranial fossa and the brain. In all instances the tumors followed the lymph vessels. In three cases distant metastases oc-

(3) Ztschr. f. Hals-, Nasen-u. Ohrenh., Feb. 22, 1927.

curred. Metastases were found three times in the liver, once in the lung, once in the dura (with arrosion of the roof of the cranium), once in the skin, in two cases in the lymph glands in the mediastinum, in the paratracheal region, in the hilum, in the region of the bifurcation, in the periportal and inguinal lymph glands. Twice an osteoplastic metastasis was found in the spinal column, the pelvis, the ribs and the bones of the extremities. The histologic observations of the tumors are given in detail.

Concerning the differential diagnosis, the author mentions that Schminke considers that the lympho-epithelial tumors are epithelial new formations of a branchiogenous nature, a netlike syncytium of epithelial cells with lymphocytes in the retiform spaces. This picture corresponds with those found during the development of lympho-epithelial organs of the thymus and tonsils. These tumors are relatively benign, as they frequently recede after irradiation and are partly cured. Complicated processes of development take place in this region. Embryonic tissue layers persist to a great degree. This might explain why unripe tumors of an embryonic nature are found. Syphilis may be an auxiliary irritating factor. A chronic irritation might influence such embryonic germinal layers to assume a tumor-like growth, principally on the basis of a chronic inflammatory process with ulcerative cicatrized changes.

Nasopharyngeal Atresia. The many procedures advocated for the cure of nasopharyngeal atresia bear witness to the inadequacy of all and to the extreme difficulty in the way of even a moderate degree of accomplishment. This is due not to the lack of either painstaking effort or ingenuity on the part of the surgeon, but to the character of the disease and to the inaccessibility of the surgical field. Here one encounters a dense, fibrous scar, generally syphilitic in origin, surrounded by soft, flexible tissue which yields without resistance to fibrous contraction. The contraction is, moreover, exerted to a central point from the periphery of a circle, as well as in a

perpendicular direction. The scar that results from syphilitic ulceration has a quality of contraction all its own, and is nonexistent in the fibrous tissue following ordinary inflammation. The more this syphilitic scar tissue is molested the more obstinately it asserts its supreme contractile power growing harder and tighter after each surgical intervention.

Assuming the hole to be present, and only a partially destroyed mucous membrane on the pharyngeal wall below the palatal curve, J. MacKenty[4] outlines two flaps as follows: Beginning just external to the point where the probe enters the nasopharynx, the knife is carried downward half as far again as the upward extension of the adhesion. The knife is now turned outward and carried horizontally across the posterior pharyngeal wall until it reaches the position occupied by the pharyngeal pillar, then upward and slightly outward to where the dim outline of the arch of the soft palate appears. This procedure is repeated on the opposite side. A curved needle on a Pagenstecher thread is inserted near the lower inner angle of this outline and brought out in a similar position near the lower external angle. This needle must be placed inside of the outlined flap and the tread must pass superficially under the mucous membrane between the points of entrance and emergence. The outlined flap is dissected up, with a sharp knife, curved on the flat, or with a curved scissors, care being taken to go deep enough to avoid cutting the Pagenstecher thread. The dissection is carried upward and outward into the nasopharynx until the adhesions are completely freed and the nasopharynx stands open, as it should do normally. There is now an open nasopharynx, and on either side of the median line, below the normal level of the soft palate, and forming a part of it, are two pendulous flaps, from near the lower borders of which emerge two Pagenstecher threads. Four ends emerge from the mouth. On each side is threaded a curved needle. Start-

(4) Arch. Otolaryng., July, 1927.

ing at one end of this row of threads a needle is grasped by a needle-holder in such a way that the needle is continuous with the shaft of the needle-holder, making traction on the flap through which the thread passes. The palate is drawn forward, the needle passed behind it and plunged, in an anterior direction, through the soft palate at a point above the line of atresia. The remaining three threaded needles are similarly passed and the threads drawn forward. The four threads emerge from the soft palate in a line across its base, i. e., well up toward the hard palate. Traction on the threads doubles the flaps backward and upward on themselves and applies them against the posterior surface of the palate. The mucous surfaces of the flaps face the posterior nasopharyngeal wall and the raw surfaces of the flaps are brought against the raw surface of the soft palate. Other stitches are used to secure good approximation of the parts. All are tied over lead disks and through diminutive lead tubes.

In the event of failure or inability to secure satisfactory flaps from the posterior pharyngeal wall, a second procedure was devised, which so far has been successful. Its aim is to produce a cleft in the soft palate as far up toward the hard palate as seems necessary for a sufficient permanent opening. Allowance must be made in making this opening for some postoperative contraction. Objection may be made that defective speech may follow the operation. In the few patients operated on, this has not occurred. Since it is of paramount importance to restore both breathing and drainage in this region, the author believes one is justified in taking some chance in this regard.

A horizontal incision is made along the normal palatal curve from one pillar to the other. From the center of this, a perpendicular incision is carried through the soft palate upward well beyond the upper line of the atresia. The adhesions are freed laterally to this on both sides. The soft palate is now divided into two triangular portions. The anterior and posterior mucous

membranes of these flaps is united by a continuous or interrupted stitch across their raw edges. To make this more effective and to do away with tension as far as possible, a v-shaped trough is made in the edges of the flaps, a strip of tissue being removed from the two sides of each triangle. This requires a sharp knife and an assistant to keep the tissues taut.

Dilation should be carried out after both of these operations to such an extent or for such time as seems indicated.

Ten cases have come under observation since about 1906. The first operative procedure was successful in seven and failed in three; the second procedure succeeded in establishing a sufficient opening in these three.

The cause of the atresia in the ten cases was as follows: syphilis, four; trauma caused by the removal of adenoids and tonsils, two; cause not ascertained, two; congenital arrested development, one, and probably scarlet fever, one.

Diseases of the Larynx and Trachea

The Epiglottis in Respiratory Obstruction Under Anesthesia. Respiratory obstruction under anesthesia is a matter of considerable importance to every anesthetist, but of vital interest to the throat surgeon. H. M. Wharry[1] is not considering the minor crises which arise during the course of an anesthetic, and are overcome by such simple but all-important manipulations as forcing apart the clenched teeth, gagging open the mouth, holding the jaw forward, pulling out the tongue, swabbing mucus or blood out of the throat, and performing artificial respiration. His object is to push a step further in the knowledge of causes of dyspnea in the normal air passages. The emergencies are rare, but when they do occur, usually result either in the performance

(1) Brit. M. J., May 21, 1927.

of a tracheotomy or in the death of the patient, or sometimes both.

Having had the opportunity of dealing satisfactorily with a number of these cases, and of making certain definite observations in the course of treating them, the author feels justified in making some suggestions as to a routine method of procedure to be followed during the very short interval of time which elapses between unrelieved respiratory obstruction, subsequent cardiac failure, and the patient's death.

There can never be any doubt as to the identity of this clinical picture, which must be diagnosed from cardiac or respiratory failure due to shock, chloroform poisoning, or depression or poisoning of the respiratory or cardiac centres in the central nervous system.

The patient's color affords the first indication that all is not well. The cyanosis is often concurrent with difficult or poor respiratory movements. This change of hue gradually becomes intensified and is soon dark blue with a blackish tinge. Respiration ceases altogether, and the pulse becomes rapid and feeble. The mouth is gagged open, the tongue pulled out, and artificial respiration is performed, but without effect. The pharynx is swabbed clear of mucus and an oxygen tube introduced in vain.

There is clearly some laryngeal obstruction, and if this is relieved at once the situation is saved, but if not the heart finally ceases to beat, the color turns from blue-black to white, the skin surface turns cold, and the flesh when cut no longer bleeds. At this point the patient is technically dead, but may be resuscitated within two minutes.

The author deals with this type of crisis in two stages: (1) When respiration ceases, and efforts to restore it have failed owing to an obstructed airway, but the circulation is still maintained. (2) When respiration has ceased for so long that the circulation fails also. The treatment of stage one is closely concerned with the epiglottis.

Where there is no laryngeal disease the epiglottis is the key to the lower air passages. Although the laryngeal sphincter, consisting of the arytenoid, thyro-arytenoid, and thyro-aryepiglottidean muscles, may be thrown into spasm, this only occurs when anesthesia is so light that the laryngeal reflex is present. The spasm passes off of its own accord in a short time and does not occur under deep anesthesia.

The epiglottis may be of several types:

(*a*) The epiglottis may be of the "overhanging" variety. That is to say, that when observed with a laryngeal mirror the larynx cannot be seen, but only the anterior surface of the free part of the epiglottis. The upper end is closely approximated to the posterior pharyngeal wall, even when the tongue is pulled forward, as is usual during indirect laryngoscopy. It is easy to understand that if the tongue falls back under anesthesia, such an epiglottis will lie right over the laryngeal and esophageal openings.

(*b*) The epiglottis may be of the "dead leaf" type. That is to say, it is curled laterally upon itself, the two sides being bent backwards and approximating to the center. This type also hides the glottis to a certain extent, and may overlap it under anesthesia.

(*c*) The epiglottis may be quite normal in appearance and yet have the following slight variations: It may be comparatively long, short, thick, thin, broad, narrow, hard, soft, rigid, or pliable. And yet if it was to be examined during an autopsy it would not attract any attention. The author has known an epiglottis (which was a little long, thin, soft, and pliable) nearly cause a patient's death by becoming impacted over the larynx. But when examined *in vivo* afterwards by the indirect method it looked the same as any other epiglottis, with the exception of the slight divergencies mentioned.

The epiglottis serves two important purposes, apart from its influence in modulating the voice:

(*a*) It acts as a protection to the larynx from the normal secretions in the mouth;

(*b*) It serves in swallowing.

The author has, by repeated digital examination during anesthesia, found the epiglottis either impacted over the laryngeal aperture, or lying in contact with the posterior wall.

As a result of his experience the writer has evolved certain requirements which he believes necessary for resuscitation of patients during such an emergency. The requirements are mainly physiological, and consist of (*a*) a free airway; (*b*) the presence of sufficient oxygen in the lungs to oxygenate the blood in the alveolar capillaries to the fullest extent possible; (*c*) the passage of that blood into the left auricle; and (*d*) sufficient movement of the heart to force some oxygenated blood through the aortic valve so as to enable it to circulate through the coronary arteries, and supply the heart muscle with enough oxygen to allow it to contract automatically. No mention of the respiratory and circulatory centres in the central nervous system is made, because our knowledge of them is theoretical rather than practical. One cannot exert clinical influence upon them in the time at our disposal, and the local treatment of the lungs and heart will produce the desired effect if accomplished in time.

To elaborate these requirements in terms of practical performance is a simple matter.

1. As soon as the emergency arises one individual must start doing artificial respiration and maintain it continuously and without ceasing for any reason, being relieved by another at any necessary intervals. Artificial respiration should be regular and unhurried, but very forcible; and should compress both lungs and heart.

2. Simultaneously another gags open the mouth, and introduces the finger as far as the larynx, raises the epiglottis and presses it forward against the back of the tongue. If the airway is now quite free the fact will

be obvious because the breath will be heard coming and going easily under the force of artificial respiration. If not, a laryngotomy or tracheotomy should be performed immediately and without hesitation, a laryngotomy being quicker and easier than a tracheotomy.

3. While this is going on a third person has brought forward the oxygen cylinder and turned on the oxygen with propulsive (but not explosive) force, and holds the tube ready to the operator's hand when he calls for it, which he does the moment the airway is free.

As soon as the operator has established the airway and holds the oxygen tube in his hand, he tests the power of the stream of oxygen and then introduces it into the laryngeal aperture or directly into the trachea in the case of a laryngotomy or tracheotomy. The lungs are thus, in the shortest time possible, flooded and washed out with oxygen aided by powerful artificial respiration.

If these three people know what to do beforehand and act simultaneously the utmost relief is supplied within a few seconds, which is an all-important factor in treatment. The necessary movements of the heart to induce the initial automatic contractions can be brought about in the majority of patients by vigorous passive movements of the chest wall. Special attention must be paid to compressing the cardiac area, and this can always be done, with the possible exception of certain individuals with unusually rigid chest walls. As soon as this is accomplished and the alveolar air has been flooded with oxygen, the heart, which has been stimulated and supplied with oxygenated blood, starts to beat and the crisis is relieved.

Trichloracetic Acid in the Treatment of Ulcerative Laryngeal Tuberculosis. B. C. Davies[8] has treated forty-two patients with pure trichloracetic acid and with uniformly good results. The ulcerations healed promptly, and they were able to swallow in comfort.

The location of the ulceration does not influence the

(8) Ann. Otol. Rhin. and Laryng., September, 1927.

treatment in any way. The acid is easily applied, and frequent applications are not necessary. No routine is followed as to a definite interval between treatments. They are given as indicated by the character of the ulceration. As a rule, all that is required, after the first application, is a touching up of small areas that have not been as prompt in granulating as the rest. With subsequent applications these areas are stimulated and become even and smooth.

When complete coverage with granulations has taken place, it is a good practice to make regular applications, twice a week, of chaulmoogra oil, 20 per cent., in olive oil, in order to establish fibrosis and thus render the area firm and hard. As a rule, this oil is used for two months.

The action of acid trichloracetic is escharotic. The tubercular ulceration is a broken down miliary tubercle, now filled with detritus, which is very hard to penetrate. Pus and bacteria form a combination which perpetuates the ulcer and permits it to enlarge.

This mass is rapidly penetrated by the acid, and instant coagulation takes place down to normal tissue, causing the mass to slough within a few hours, leaving a very clean, even surface.

Following this process, granulation tissue begins to form within a very few hours, eventually covering the ulcer completely. Not more than four treatments have been given to any one ulcer in order to produce repair of the ulcerative area and eliminate the dysphagia.

Tuberculosis of the Larynx. The superior laryngeal nerve, essentially the sensory nerve of the larynx, has played an important part in the treatment of tuberculosis of the larynx during the last two decades; but only for the last five or six years has the recurrent nerve been considered in this connection.

H. P. Schugt[6] bases his report on a series of 79 cases and records fifteen cases in detail. The author's pro-

(6) Arch. Otolaryng., December, 1926.

cedure is to resect the superior laryngeal nerve at the hyothyroid membrane and to inject the recurrent nerve with 1 to 1.5 cm. of 80 per cent. alcohol. The paralysis from the latter remains on an average from about four to eight weeks.

The results in fifteen cases of therapeutic paralysis of the recurrent nerve may be summarized: (1) improved, nine cases; (2) unimproved, three cases; (3) worse, two cases, and (4) insufficient treatment and observation, one case.

The author has tabulated apparently healed cases as improved, as a complete anatomic healing appeared doubtful after so short a period of observation.

At all events, this method of treatment, which has been in use for only the last few years, appears destined to play an important rôle in the treatment of tuberculosis of the larynx as an adjunct to the other methods of treatment. Laryngologists who prefer more conservative methods of treatment are likely to use this method, as are those who may have justifiable doubts as to the efficacy of operative intervention, such as curettage and cauterization, which may be useful in certain cases and harmful in others. Of course, in the treatment of tuberculosis of the larynx, each patient should be studied conscientiously from certain points of view and the best method of treatment determined.

The therapeutic paralysis of the recurrent nerve is especially beneficial in unilateral cases which have not advanced too far and in which the pulmonary condition is relatively favorable, *i. e.*, in the fibrotic forms.

The Diagnosis and Treatment of Laryngeal Tuberculosis. According to E. A. Looper[7] every patient with pulmonary tuberculosis should be considered a possible case for the development of laryngeal complications. Regular, routine laryngeal examinations should be made in all cases, as it is most important to make a diagnosis early. The diagnosis should be made by objective ex-

(7) Ann. Otol. Rhin. & Laryng., December, 1926.

amination, as it is a mistake to wait for subjective symptoms to develop before giving attention to the larynx. If a diagnosis is made early the case can be easily cured. If delayed the prognosis is serious.

Treatment of the local lesion with the electric cautery has given the author excellent results. He now uses it in preference to all other methods of treatment. The prognosis of laryngeal tuberculosis is encouraging and cures are to be expected, if recognized early and active cauterization is employed.

The author presents a large number of cuts showing the various tuberculous lesions as they are found in the larynx.

On the Light Treatment of Laryngeal Tuberculosis. Strandberg, in 1914, first used general light baths in treatment of laryngeal tuberculosis. Blegvad used it a few years later. Strandberg reported (1924) 53 per cent. of recoveries and Blegvad (1922) 40 per cent. An arc lamp was used, the spectrum of which is especially rich in the long wave lengths, violet and ultra violet.

Cemach and Wessely, among others, have reported the use of light directly on the larynx. Cemach used rays from a Kromayer lamp, which he directed through a tube. Wessely used concentrated rays from a special arc lamp reflected by a mirror into the larynx.

A. Plum[8] discusses the nature of light therapy and the properties of different types of rays. The sunlight presents a continuous spectrum with ultravisible rays at both extremities. The visible spectrum lies between 397 and 760. It is the short wave lengths that have therapeutic value. In high altitudes (mountains) rays as short as 290 are found. The atmosphere filters these, and at sea level the shortest rays are about 313. The spectrum of the arc light is also a continuous spectrum which reaches from 290 far into the ultra-red, with its most active rays between 359 and 388. The mercury

(8) Selskabs Forhandl. Hospitalstid., 35:93, 1926.

quartz light gives an interrupted spectrum with its active rays between 200 and 300.

Although the shortest ultraviolet rays are the most active in destroying bacteria, they have the least power of penetration (Finsen). Various experiments are cited which determine the penetration power of different wave lengths, and their action on the tissues and the reaction of the latter. Penetration is greater in tissue which has been rendered anemic by pressure.

The final conclusion is that the most valuable rays are the "inner" ultra-violet and the blue violet rays.

Local treatment of tuberculous lesions of the mucous membranes at the Finsen Lysiinstitut has been successful on the gums and lips but not in the larynx.

Sorgo (1904) reported a case of tuberculosis of the larynx healed under local treatment. He reflected the sunlight into the larynx. He later treated a number of patients in a similar manner.

Brünings and Albrecht treated experimental laryngeal tuberculosis by different types of light but found no microscope changes due to the light.

Blumenthal and Schroeder failed to secure benefit from local treatment.

The author suggests a number of factors besides the feeble power of penetration of the rays which may account for failure of local light treatment in the larynx. Among these are the comparatively long distance into the larynx; the loss of rays by reflection; the loss of intensity because of the angle at which the light falls on the mucous membrane (the intensity is proportionate to the cosine of the angle of incidence); the hyperemia of the tissues, which is usually present and which decreases penetration.

The author concludes that the beneficial action of light in tuberculous lesions is a general reaction and can be obtained by general light baths.

Membranous Laryngitis and Tracheobronchitis (Non-diphtheritic). Fourteen cases of laryngitis and tracheo-

bronchitis, nondiphtheric in origin, are reported by T. R. Gittins[9]. The early symptoms simulated the onset of laryngeal diphtheria, but following tracheotomy and administration of antitoxin, there was a tendency for thick, tenacious secretions to form in the air passages, and to bring on at times serious dyspnea and cyanosis unless removed by mechanical means. Four of the fourteen cases were of a mild type, did not need cannulation, and recovered without sequelæ.

Bacteriology.—In eleven of the cases the laboratory report was negative for diphtheria bacilli, and positive for streptococci or staphylococci in pure or mixed culture. In three instances a few diphtheria bacilli were reported, but streptococci were found as the predominating organisms. These latter cases are included because the clinical course in each was very similar to that encountered where no diphtheria bacilli were reported. Streptococci were reported from the laboratory as predominating in all cases, though staphylococci were practically always named as present. Detailed report of the type of streptococcus were obtained only in a few cases, but in these the streptococcus hemolyticus was the main offender. In one instance contact infection was suggested by the report of the streptococcus hemolyticus of the Beta type in culture from the patient, and the mother, who was also suffering with a laryngitis.

Treatment.—Tracheotomy was found to be essential in the severe cases; intubation proved unsatisfactory. The use of the suction catheter through the tracheal cannula, early and often, supplemented by instillation of adrenalin, proved most satisfactory in removing the sticky secretions from the air passages. The bronchoscope was of value as an emergency measure to remove the semisolid masses from the trachea and bronchi when suction failed to relieve the dyspnea. Cough incited by use of a feather or pipe cleaner through the cannula, or the introduction of adrenalin, proved of value at times

(9) Ann. Otol., Rhin. & Laryng., December, 1926.

in helping to rid the trachea and bronchi of the thick secretions. Diphtheria antitoxin was apparently of no value.

Results.—Of the fourteen nondiphtheritic cases treated, ten had tracheotomy. Of these ten, four recovered and six died. The four which were not cannulized recovered. Thus, considering the entire group, eight recovered and six died. It is the author's opinion that the fatalities were due mainly to the mechanical obstruction of the trachea, bronchi and bronchioles by the secretions rather than to the severity of the infection.

Incidence.—In the author's practice fourteen nondiphtheritic cases have been encountered in the past six years. During this same time he has treated twelve cases of true laryngeal diphtheria. Since 1923, only one case of laryngeal diphtheria has come under his care, while there have been eight of the nondiphtheritic type.

From a partial review of the literature and from personal communications, evidence is at hand that these nondiphtheritic infections have been recognized and reported for many years, though it seems very likely that a considerable number of similar cases have been treated as diphtheria, with their true nature unrecognized.

It seems that the recognition of such conditions simulating laryngeal diphtheria is of some importance clinically and from the standpoint of epidemiology. Clinically, if such cases as are described here are treated as diphtheria and antitoxin is relied upon, other more appropriate treatment may be delayed or neglected entirely, and the result in some instances may be a fatality which might have been avoided. From the standpoint of epidemiology, the statistics as to the prevalence of laryngeal diphtheria, and its mortality rate; the importance of the Schick test; the efficacy of toxin antitoxin as a preventive; and of antitoxin as a curative agent, may be affected in a small way at least.

Is Radium a Cure for Cancer of the Larynx? An Inquiry Based on a Study of the End-Results. T. J. Harris[1] reviews the views of various writers on this subject. The author states that the staff at the New York Post-Graduate Hospital was among the first to employ radium in the larynx, at the outset, only for benign growths. The results secured in the removal of these were so encouraging as to lead to the use of it for malignant neoplasms. For a time it was believed that a remedy had been found to take the place of the knife or to be used effectively when surgical intervention was contraindicated; however, this belief was not justified, as a number of patients died.

Radium was still used, however, at it was thought that the failures were due to improper dosage and to faulty technic in introduction.

Gradually, as not merely failures resulted, but as the suffering apparently was increased under the treatment and death was hastened, the conclusion was that radium in the treatment of malignant disease of the larynx up to date has been harmful.

Personally, the author has ceased to use radium unless for some exceptional reason. If the case has reached the stage in which operation is ruled out, such measures are used as will make the patient as comfortable as possible without adding to his suffering, by increasing the obstruction in the larynx, as radium often has seemed to do. For such obstruction a simple tracheotomy has been seen to give the desired relief in more than one case.

If operation is indicated, radium is not substituted. In case operation is refused, radium would not be advised until other measures had been carefully considered.

The author states that if he had cancer and condition was too far advanced for an operation he would prefer to endure the disease rather than to risk the uncertain results of radium treatment.

(1) Arch. Otolaryng., April, 1927.

Laryngography. D. H. Jones[2] has endeavored to find a vehicle which would combine with the iodized oil, and would remain on the mucous membrane and enable one to outline the interior of the larynx.

After considerable experimentation he found mucilage acacia, using it in the proportion of half and half, would combine with the iodized oil and form an emulsion; and after thorough cocainization of the larynx, it was possible to secure excellent photographs of the larynx (Fig. 35).

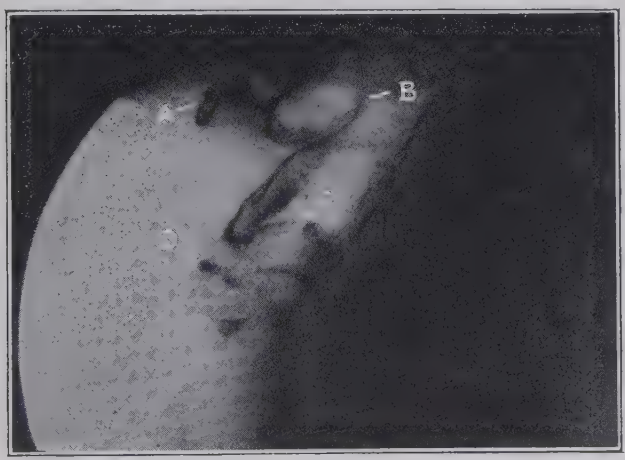

Fig. 35.—Laryngography: *a*, hyoid; *b*, epiglottis; *c*, arytenoids; *d*, vocal cords.

The patient should be given a hypodermic of morphine, 1/6 to 1/4 gr., one hour before, and larynx cocainized with 10 per cent. cocain, preferably by the drop method.

After complete cocainization the emulsion of iodized oil and mucilage acacia is instilled very carefully, drop by drop, on the epiglottis, allowing it to spread over the mucous membrane as a grayish film, using sixty minims,

(2) M. J. & Record, Apr. 20, 1927.

cautioning the patient to breathe very quietly and using every means to control the cough reflex. As soon as the emulsion has been introduced stereograms should be made in lateral position.

The author was enabled to obtain very clear photographs of the epiglottis, cords, arytenoids, and also to outline both walls of the trachea below the cords.

As a diagnostic aid this method of localization presents many possibilities and it is rather difficult in this preliminary paper to set forth definite indications for its use. Using this small amount one does not fear symptoms of acute iodism.

Operative Relief of Laryngostenosis. A. Schwyzer[3] reports a case of laryngostenosis in the treatment of which a special operative procedure was adopted.

The patient, a woman about 40 years of age, had been treated for one year for asthma. The laryngoscope showed great destruction of the epiglottis; the larynx looked like an ulcerating crater. It was impossible to see into the trachea, the larynx having a very narrow and tortuous lumen and presenting on all sides a bulky thickening with an irregular ulcerated surface partly covered by a dirty looking material. A Wassermann test proved to be 4 plus.

Under salvarsan treatment, a cicatricial stenosing change seemed to occur with the healing and was undoubtedly the cause of an increase in the severity of the dyspnea. The appearance of the larynx, however, improved. On account of the dyspnea, operation was necessary.

The thyroid cartilage was divided in a zig-zag manner and the two sides of the thyroid cartilage were pulled apart until the tips of the corresponding projections rested upon each other. These were then fastened by a silk suture so that their tips met firmly (Fig. 36-A, B).

(3) Ann. Surg., January, 1927.

If the larynx is not severely stenosed and does not require an intralaryngeal operation, as for instance in asphyxia from paralysis of the posterior cricoarytenoid muscles, the mucosa need not be opened. The stenosis may be relieved by a comparatively simple operation and the indefinitely prolonged wearing of a tracheotomy cannula avoided. The described method of widening the larynx was satisfactory. In reality this is a laryngoplasty.

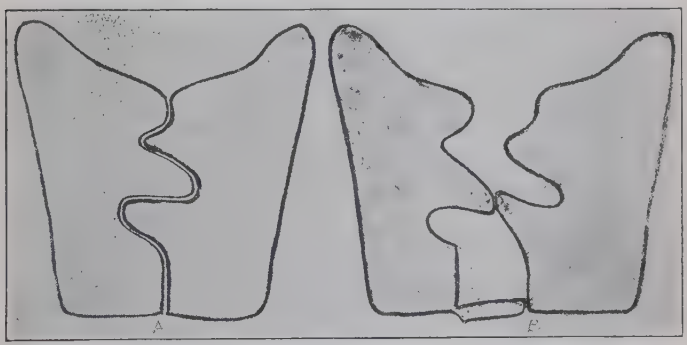

Fig. 36.—A. Incision made into thyroid cartilage. B. Incision, spread apart.

A Mechanical Larynx. E. I. McKesson[4] presents an instrument which enables a patient whose larynx has been removed because of carcinoma to speak with a voice approaching the normal in volume and quality. A neck piece is held in place by means of the collar, to which it is attached by an ordinary collar button. A rubber tube connects the neck piece with the trumpet, and a tube from the trumpet conducts the sound into the mouth. To speak, the neck piece is pressed gently against the neck, and air is blown through the trumpet, setting up a sound resembling the normal voice. This sound is conducted into the mouth, where it is formed into words. Some training and practice are required

(4) J. A. M. A., Feb. 26, 1927.

to produce the consonants, while the vowels are easily elicited at once. Practice is required to obtain inflection.

The general idea is old, but this instrument embodies several new principles which have resulted in a more perfect reproduction of the human voice. Intratracheal tubes which irritate the trachea have been eliminated. A valve permits free inspiration with the instrument in place and reduces the "dead space" containing exhaled gases and carbon dioxide, which, together with restricted passages of an instrument, have been factors in producing dyspnea with previous appliances.

The trumpet embodies an effective method of voice production and amplification by means of a reed which operates easily, requiring little air pressure and volume. The reed is a standardized inexpensive article and may be replaced almost instantly. (Fig. 37.)

Fig. 37.—Patient using mechanical larynx.

When not in use, the trumpet is carried on the inside coat pocket. The fresh, cool air entering the trachea at the neck is tempered with a certain amount of warm air from the pocket, preventing the cough that results from the inspiration of cold air directly into the trachea.

The illustration is of a patient whose larynx was removed about three years ago by Dr. John E. MacKenty of New York. There has been no recurrence; the patient transacts his business as a wholesale jeweler and has also given public addresses with the instrument.

The Permanent Use of the Tracheotomy Tube. In many instances the laryngeal condition calling for tracheotomy can be removed, or a resulting stenosis of the glottis cured; in such cases the tracheotomy tube can be abandoned with saftey. This is possible in such conditions as impacted foreign bodies, acute laryngitis, edema of the larynx, diphtheria, typhoid ulceration, syphilis, and tubercle. On the other hand, there are many cases in which a laryngeal stenosis is permanent, and it is to the principles of treatment to be recommended in such cases that StClair Thomson[9] particularly calls attention.

In the first place an attempt to cure the stenosis itself is liable to fail and entail further damage or complete loss of voice; or again, surgical intervention might merely scar the neck, stimulate to further stenosis, or encourage recurrence of arrested disease. Moreover, many of the methods employed for overcoming a laryngeal stenosis are tedious, painful, often unsatisfactory, and not free from danger.

In the second place the permanent wearing of a cannula in a well executed opening just above the sternum is, in adults, by no means the disaster it is often represented to be; and it is not incompatible with a long healthy, and useful life. In the third place the wearing of a tracheotomy tube will, in many cases, preserve a

(9) Brit. M. J., June 11, 1927.

useful voice, while avoiding the alternative of a mutilating excision of the larynx.

The author presents some permanent "canulards," including cases of complete bilateral laryngeal paralysis, lupus, stenosis from surgical trauma, syphilis, tuberculosis, enchondroma, and carcinoma.

Voice and Speech Disorders

Stuttering: The Cause and the Cure. J. A. Glassburg[5] states that stuttering is a spastic coordination neurosis based on a mental conflict. The causes are a predisposing neuropathic constitution and an exciting factor in the form of a nervous shock or psychic insult.

The treatment is threefold: surgical, psychotherapeutic and reeducational. The surgical treatment is directed toward the correction or removal of abnormal physical conditions in the vocal passages. Psychotherapy, in the form of hypnosis, psychanalysis, autosuggestion, heterosuggestion and distraction, is directed toward unearthing the basic mental conflict and readjusting the personality.

The reeducational treatment consists of a series of exercises under four different headings: relaxation, breathing, vocal gymnastics and phonetics. Stuttering is a curable condition, but it requires the combined efforts of the patient, the teacher and the physician to cure it.

Stammering as a Psychoneurosis: A Plea for Corrective Measures. It is the belief of T. G. Leary[6] that a child does not usually stammer because he is nervous, but is nervous because he stammers. The rational treatment of stammering may be understood upon the basis of the underlying causative factors. The careful preliminary general medical examination with elimination of hyperthyroidism, septic tonsils and masturbation, the

(5) Arch. Otolaryng., February, 1927.
(6) M. J. Australia, Feb. 26, 1927.

adoption of suitable sympathetic surroundings may be taken as granted. The special measures fall under two heads, the first directed to the psychic complex and the second to the endeavor to reestablish a harmonious interaction of the muscles of articulation and respiration. The whole success of treatment depends upon creating in the patient's mind a feeling of confidence and self-reliance and when possible especially explaining the methods with autosuggestion. The endeavor must be in this direction to overcome all sensitiveness and bring about a smoothness of mental balance. The family circle and friends should comprehend that their help is needed, when they are made fully conversant with the technic. Personality is an invaluable factor in helping to encourage and to allay natural emotion of fear. Any repressed complex likely to instil or perpetuate nervousness should be patiently sought. It may be necessary in severe cases to begin with isolation from friends and relatives and to allow the sufferer to test progress with strangers. Irritability and misplaced sympathy will militate against a successful issue. A sympathetic knowledge of child nature will on the other hand be an asset of the most powerful assistance.

In an attempt to overcome stammering from any cause rhythmic breathing is first practised as in yawning, then sound is added as in sighing. The sound of all the vowels is then produced in an intentionally careless drawl. This drawl or relaxation is important and should resemble the slurring careless speech of alcoholics. Only the vowel sounds should first be permitted, later on articulated words may be used, each vowel should be definitely extended and one or two syllables should at first be used. This rhythmic sound can be modulated from soft to loud and altered in musical pitch, time being kept by the hands or the feet or by slow walking and in perfect relaxation (swaying). Sometimes the piano scale is used.

For vocalization purposes the letters of the alphabet

followed by counting are practised after the method of the vowels and the consonants which cause the stutter are noted. These troublesome letters are practised with the vowels alone and with simple nursery rhymes in which the prolongation of the final part of the word into the beginning of the next is an all-important feature. At first this sing-song utterance or montonous drawl or lalling breaks down the barrier of want of confidence and barrenness of hope, the frustration of normal activity by fear in possession.

In conclusion it is necessary that all self-consciousness and reserve should be absent and the voice and vision aimed at the person addressed. Fear of ridicule must be removed as much as possible and special stress laid on the fact that stammerers must not try to conceal the painful defect nor attempt to speak with their mind on their affliction. This self-negation intensifies the strained effort and brings about grimaces tantamount to a storm. They should know and it should be instilled into their minds, that their bondage of fear is not hidden and their misfortune is well recognized. It is obvious to all their associations and those living within the orbit that they are suffering mental pain besides exhibiting physical distress. They will find that by speaking slowly, softly and deliberately their stammering will be impossible and their controlling influence will be strengthened beyond their expectations.

Preliminary Paper on Improvement of Speech in Cleft Palate Cases. The reasons heretofore given and generally accepted for poor speech following palate operations are, first, that the reconstructed palate is usually too short to extend back and shut off the nasopharynx, or second, that the musculature has been so much interfered with that the soft palate cannot be retracted. However, one repeatedly finds that patients with palates which are extremely short have reasonably good speech, and vice versa that patients with palates which are long and pliable have poor speech. It is

also true that the severing of muscles of the palate does not have any marked effect upon the pliability of the palate. Again in a certain proportion of patients otherwise normal who have experienced tonsillectomy and removal of adenoids one finds a temporary development of speech closely resembling the speech of a cleft palate patient. In such patients the palate certainly has not been shortened or its musculature interfered with enough to account for the speech. The facts mentioned led H. L. Kirkham[7] to the conclusion that, while a long palate is ideal and is a large factor in improving speech, there must be some important factor which is being overlooked. For some time the author has observed that in a large majority of cleft palate cases, especially in older children, there is an abnormal development of the superior constrictor muscle of the pharynx. At first no particular significance was attached to this fact.

Recently, however, the writer had the opportunity of measuring the anatomical landmarks in normal palates at different ages and was able to determine the normal palate as far as that could be done. By checking these measurements on cleft palate cases of approximately the same ages, it was found that the hamular processes were distinctly wider in palate cases than in the estimated normal, depending upon the width of the cleft. This, together with the overdevelopment of the superior constrictor which has its origin from the pterygoid processes of the sphenoid, led the author to the conviction that the superior constrictor muscle has far more bearing than has heretofore been thought on the production of speech, or rather voice tone.

With the above facts, observations, and deductions, the author became convinced that if a method could be devised by which the superior constrictor could be shortened, preferably allowing it to act upon the posterior part of the palate, the closure of the nasopharynx would be very much facilitated, and consequently speech should

(7) Surg. Gynec. Obst., February, 1927.

be improved. A short time ago he operated again on a child 6 years old upon whom he had previously repaired a palate, and had obtained a rather short palate.

He freed the upper border of the superior constrictor on each side of the pharynx and sutured it to the posterior surface of the palate and palatopharyngeus which, of course, were denuded. Thereby the nasopharynx was made narrower, and the action of the superior constrictor was upon the posterior surface of the palate with a consequent tendency to retract it and close off the nasopharynx still more. The immediate result in this case, the next few days, was a striking improvement in voice tone. On the fourth day, however, the child spoke just as badly as before the operation. However, on examination it was found that the sutures had pulled out during the night.

The immediate results in this case still further convinced the author that some method of shortening the superior constrictor along its upper border will be the keynote to improvement in speech in palate cases. It remains to be determined at what point it is best to free the constrictor so that it can be shortened without tension, also how far it is desirable to free it.

Postadenoidal Speech. Normally, the uvula and soft palate are sufficiently large to close up the nasopharyngeal space, but when huge adenoids are present for a long time, the nasopharyngeal space becomes widened to accommodate the adenoid masses and at the same time to permit the passage of some air. This may be considered as a compensatory widening of the nasopharyngeal space.

When the adenoids are removed, the uvula and soft palate are insufficient in size to span across the space, and instead of too little air through the nose there is a gush of too much air.

In most cases, after the removal of the adenoids the compensatory widening of the nasopharyngeal space gradually comes down, and the soft palate and uvula by

increased exertion and practice learn to occlude the space. In those cases, when due to either too great a widening or too short a soft palate and uvula, the failure to close up the space remains and a speech disorder develops, the chief characteristic of which is hypernasality.

The existence of a true hypernasality can be determined in several ways. In listening to the speech it will be found that sounds other than *n*, *ng*, and *m* are nasalized. If the patient is told to repeat a test sentence free of nasal sounds, it will be found that the speech is muffled and many sound tones are impregnated with the *n* element.

To make certain that the hypernasality is due to a short velum, the patient is told to tilt his head back and repeat slowly with emphasis on the *a*, the word *rah*. The velum should rise and occlude the post-pharyngeal space on the *a*.

The treatment advocated by J. A. Glassburg[8] consists of electricity and massage, which are more theoretical than practical, and special exercises directed to the uvula, palate, tongue and lips. As a prophylactic measure, every patient with an operation for adenoids in prospect should have the palate inspected to determine any unusual shortness.

The author recommends the following tongue exercises:

1. Push the tongue out of the mouth and downward toward the chin.
2. Push the tongue outward and upward as far as possible, even touching the nose.
3. Point the tip of the tongue upward and downward alternately for a count of 10.
4. Rotate the tongue to the right, then down, then to the left, then up.
5. Protrude the tongue, grooving it at the same time by raising the sides.

(8) Arch. Otolaryng., October, 1926.

6. With the mouth kept open, curl the tip of the tongue back of the front teeth.

7. Press the tip of the tongue to the back of the front lower teeth; then relax.

Lip exercises consist of:

1. Pucker the lips and protrude them.
2. Raise the upper lip, exposing the upper teeth.
3. Wrinkle the nose so as to expose the upper teeth.
4. Raise the right side of the upper lip.
5. Raise the left side of the upper lip.
6. Pull down the lower lip, exposing the lower teeth.

For the soft palate and uvula the patient should:

1. With mouth wide open, say *ah-ah*, and watch the palate rise.

2. Yawn and watch the palate rise.

A New Auxiliary Measure to Create Head Resonance in Singers and Speakers. E. Froeschels[9] states that the so-called "voix mixte" is considered desirable. Each tone should contain chest and head resonance. The production and increase of head resonance is difficult for many pupils, and even for well trained artists. Closing the outer canals of the ear increases the sound, which is helpful. If a singer places a finger airtight in the ear canals and sings or enunciates "M," a humming is noticed. If the pupil is told that a similarly strong humming occurs while singing or enunciating other sounds, if nasal resonance is present, he can find out whether the tone (sung or enunciated), contains nasal resonance. The method proved effective. Some persons cannot produce the humming if they place the lower jaw too low. In such cases by bending forward and opening the mouth less wide, the head resonance can be noticed. Advanced pupils are able to establish by this method whether the voice is mixed correctly. The procedure is not a panacea, but only an auxiliary measure.

(9) Ztschr. f. Hals—, Nasen—, u. Ohrenh., Nov. 8, 1926.

Dysphonia, Its Significance and Management. Hoarseness is classified by G. D. Wolf[7] as either functional or organic. The diagnosis of functional hoarseness should only be made when organic disease can be excluded with a fair degree of certainty. The hoarseness due to organic disease may be classified according to etiology somewhat as follows: 1, inflammatory; 2, noninflammatory; 3, cerebrospinal, and 4, toxic.

Inflammatory—a, acute laryngitis; b, perichondritis following quinsy, typhoid, variola, scarlet fever, rheumatism, or any acute infectious disease; c, ankylosis or arthritis of crycoarytenoid joints; d, tuberculosis; e, syphilis; f, laryngitis sicca; g, sinus disease; h, dental origin—probably a focal infection.

Noninflammatory—a, benign or malignant neoplasms; b, serous infiltration; c, pressure of tumor on trachea; d, pressure on recurrent laryngeal nerve or the vagi; e, damage to crycoarytenoid muscle or arytenoid itself; f, foreign body in the larynx; g, prolapse of ventricle; h, stenosis or web of larynx—congenital or acquired; i, abuse of voice—failing to bring cords together; j, general anemia; k, cardiac origin; l, spasm of laryngeal muscles, as in laryngismus stridulus.

Cerebrospinal—a, bulbar paralysis; b, brain tumor; c, syringomyelia; d, bilateral paralysis of adductor or abductor muscles.

Toxic—a, alcohol; b, tobacco.

Diagnosis of hoarseness is often established by mere laryngoscopy. But at other times, even with present day laboratory methods, such as biopsy, blood examination, bronchoscopy and *x*-ray, it is exceedingly difficult and at times impossible.

The author cautions especially regarding the acute onset of hoarseness in children where even with trivial symptoms the results are sometimes disastrous. Differential diagnosis here is to be made from diphtheria, perichondritis, pseudomembranous croup, foreign body in

(7) M. J. and Record, May 18, 1927.

larynx, laryngismus stridulus, thymus (status thymicolymphaticus).

Hoarseness in adults lasting over three weeks should never be ascribed as due to chronic laryngitis unless everything else had been ruled out. The following conditions are to be differentiated: Chronic laryngitis, tuberculosis, benign growths and malignant growths.

As to treatment the author discounts the prevailing pessimistic view that all cases of laryngeal tuberculosis are fatal. This is not true. The prognosis depends primarily on tuberculous involvement of the lungs, and, secondly, on character and involvement of the larynx.

Benign growths should be removed by either direct or indirect methods. Malignant growths, when intrinsic, should be subjected to early surgical interference. The extrinsic type should be treated either with radium or *x*-ray, or other palliative procedures. Chronic laryngitis was best treated by rest and by elimination of the original causative factor, which is most often the nose.

Relation of Oral Articulative Movements of Speech and of Extrinsic Laryngeal Musculature in General to Function of Vocal Cords. The following conclusions are reached by E. L. Kenyon[8].

1. The larynx, hyoid bone, lower jaw, tongue, soft palate and pharynx, together with their combined intrinsic and extrinsic laryngeal musculature, constitute one united system of organs and muscles for all functions that involve the larynx. Their functions are primarily those of animal life; secondarily, in man, they are employed also as organs of speech. The intrinsic and extrinsic musculature can act, whether for animal functions or for speech, only as one united muscular system. No other psychoneurologic means of action is provided.

2. The peripheral physiology of speech is immediately based on the corresponding basal physiology of the animal functions of the same organs. That the psychology

(8) Arch. Otolaryng., June, 1927

of the peripheral function of speech is based largely on that of certain corresponding animal functions of these organs is probably also true.

3. The extrinsic musculature is attached to the larynx almost exclusively by way of the thyroid cartilage, and thus may apply its laryngeal influence directly to the vocal cords. Through co-operation of the thyro-arytenoid muscles, it may presumably alter the details of vocal cord approximation.

4. Studies of laryngeal function, apart from observation within the larynx itself, have been carried out on a wrong principle. Attempts to understand the action of so complex and co-operative a musculature by first studying the anatomy and then speculating as to how the muscles probably act, lead to inadequacy of result, as well as to error. It is possible to know the actual performance of such a musculature only by observation of what it actually accomplishes.

5. The present study of the extrinsic musculature in actual action, by palpation of the upper anterior tip of the thyroid cartilage and adjacent structures, including the trachea, has yielded important physiologic information, as to both normal and abnormal speech.

6. One important error in physiologic observation, that regarding the manner in which the vocal cords are stretched for purposes of elevating the pitch of the voice, has pervaded the textbooks of laryngology for at least seventy-five years. Actual observation of the action of the thyroid cartilage by palpation shows clearly and definitely that elevation of the vocal pitch is produced, not by tilting the thyroid cartilage downward as has been supposed, but by tilting it upward. This is an act of the extrinsic musculature.

7. By similar observation of the actual action of the extrinsic muscles, the whispered voice is found to be produced by joint action of the entire intrinsic and extrinsic musculature, but with certain important differences from their action in the production of the loud

voice. Ceberal excitation for the loud voice, as compared with that for the whispered voice, may possibly differ, not merely in degree but also in kind.

8. The interrelation between the movements of the organs of the mouth that determine the elemental sound of speech and the approximation of the vocal cords for the production of voice are so immediately related as to constitute one complex physiologic act.

9. The natural pitch of each elemental English sound is dependent chiefly on the effect of the articulative placement of the body of the tongue on the position of the hyoid bone, and secondarily, on the consequent position of the thyroid cartilage with reference to the cricoid.

The Surgical Treatment of Paralysis of the Vocal Cord and of Paralysis of the Diaphragm. Experiments performed by L. Colledge and C. Ballance[9] on the monkey and the dog show that end-to-end, or end-to-side, anastomosis of the recurrent laryngeal nerve to the phrenic nerve is successful in restoring, after a certain lapse of time, movements of abduction and adduction of the vocal cord comparable to those of the opposite or normally moving cord. After section of the recurrent laryngeal nerve the vocal cord assumes a typical cadaveric position and the inner border is concave and flaccid. After six or eight weeks from the date of operation the inner border of the immobile cord becomes straight and tense. There is, in fact, a tension about the previously paralysed cord which had not been present before. Four months after the first experiment of recurrent laryngeal-phrenic end-to-end anastomosis was carried out both vocal cords were moving equally in tranquil respiration. Six months after the experiment was done the previously paralysed cord moved more strongly than the other, and seven months after the experiment there was excessive, almost violent, movement as compared with the vocal cord on the normal side. This result was hardly a surprise, because the nerve current required to cause contraction of one half

(9) Brit. M. J., Mar. 26, 1927.

of the muscle of the diaphragm must be considerably stronger than that required to energize the small intrinsic muscles of the larynx.

The best method of anastomosis of the recurrent laryngeal nerve to the phrenic nerve so as to obtain recovery of movement of the paralysed vocal cord in rhythm with the movement of the normal cord remains to be determined.

In certain experiments in the monkey the root of the phrenic nerve from the third cervical nerve, or the root of the phrenic nerve from the fourth cervical nerve, was united side-to-end to the recurrent laryngeal nerve; and in others the root was divided and united end-to-end to the divided recurrent laryngeal nerve. In other experiments the divided recurrent laryngeal nerve was united end-to-end to the proximal segment of the divided main trunk of the phrenic nerve; and in yet others the end of the divided recurrent laryngeal nerve was anastomosed end-to-side to a small lateral incision made in the side of the main trunk of the phrenic nerve.

In some cases the end-to-side anastomosis of the recurrent laryngeal nerve to a root of the phrenic nerve or to the main trunk of the phrenic nerve was effected by making a small longitudinal median incision into the part of the phrenic nerve selected for the site of anastomosis and attaching the cut end of the recurrent laryngeal nerve to it. The end-to-side operation is the operation of choice—that is, if there is sufficient length of the recurrent laryngeal nerve to bring across the carotid sheath to the side of the phrenic nerve without tension on the anastomosis. If, however, the available length of the recurrent laryngeal nerve is insufficient to reach the phrenic nerve, then the phrenic nerve must be divided and the proximal end brought across to meet the divided distal end of the recurrent laryngeal nerve. The actual method of anastomosis, whether by lateral incision or longitudinal median incision, did not seem to affect the final result. The authors believe, however, that the plan

of lateral incision is the plan to adopt when end-to-side anastomosis is performed, as there is a definite and immediate approximation of divided nerve fibres. In such cases a partial or complete paralysis of one half of the diaphragm follows, but in a few weeks the paralysis passes away.

In man, therefore, the operation of choice is recurrent laryngeal-phrenic anastomosis, end-to-side, the lateral incision of the main trunk of the phrenic being carried out in order to obtain a raw surface of cut nerve fibres to which the distal end of the cut recurrent laryngeal nerve is attached.

This decision is based not only on the recurrent laryngeal-phrenic nerve anastomosis experiments, but on the results of a large number of experiments in which the two ends of a divided nerve were implanted at varying distances apart into the side of, or into median incisions in, a neighboring nerve. These experiments have been reported, and they seem to prove that the lateral incision method leads to more rapid and satisfactory recovery of the muscles supplied by the divided nerve than when its two ends are implanted into median longitudinal incisions made in the neighboring nerve.

There is also no advantage in attaching the recurrent laryngeal nerve to one of the roots of the phrenic. When the root is divided and its proximal end sutured end-to-end to the recurrent laryngeal nerve the distal end of the root has sometimes been left without being joined to another nerve, and sometimes it has been joined end-to-end to the divided proximal end of the descendens noni nerve. In either case, even when the vocal cord muscles function again, there seems to be some delay in the recovery of the normal contractions of the whole muscle of the diaphragm. It is curious to note that the quickest return of function of the vocal cord follows end-to-end anastomosis of the recurrent laryngeal to the proximal cut end of the main trunk of the phrenic nerve, and the most rapid recovery of the whole diaphragmatic muscle

has followed end-to-end anastomosis of the distal cut end of the phrenic nerve to the proximal cut end of the descendens noni nerve. This latter result is in itself surprising, as the authors have not been able to obtain return of movement in the vocal cords during tranquil respiration by means of descendens noni-recurrent laryngeal end-to-end anastomosis. They do not suggest any explanation of this experimental finding.

There is another point about end-to-side recurrent laryngeal-phrenic anastomosis. In some cases there seems to be delay or arrest in the complete recovery of the movements of the vocal cord, or there may be delay in the complete recovery of the diaphragm, or there may be delay in the complete recovery of both vocal cord and diaphragm. The cause of these variations would seem to be that the nervous energy traveling through the phrenic nerve is overtaxed. While before the operation the nerve current of the phrenic nerve had to cause only contraction of one half of the diaphragm, after the operation it has now also to excite contraction in the intrinsic muscles of the larynx.

The end-to-side and end-to-end anastomoses of the distal end of the divided recurrent laryngeal nerve to the main trunk of the phrenic nerve on one side of the neck have been invariably successful, in that they are followed by apparently normal movements of the corresponding vocal cord; but when such an operation has been carried out on both sides of the neck, the movements of the vocal cords, thus energized through union with the corresponding phrenic nerves, have shown in a few instances an inco-ordination or false timing of the movements of the vocal cords, indicating that though the respiratory centre is working yet it has not regained normal control. This paradoxical result affects the vocal cord on the side which was first operated on, though previous to the second operation this vocal cord was moving equally and synchronously with the opposite or normally moving vocal cord.

Bronchoscopy and Esophagoscopy

Contributions to the Study of Foreign Bodies in the Respiratory Tract. B. Wiskovsky[1] reviews twenty cases in which foreign bodies were successfully extracted from the air passages, with one mortality. Fourteen of the patients were under 10 years of age. In sixteen instances the foreign bodies were organic. The one autopsy revealed status lymphaticus. Lymphatic children, on account of the inferior physique, the tendency to exudation and the difficulty of respiration, should be regarded with apprehension. The tendency to aspiration is increased in these children on account of mouth breathing, reduced sensibility of the pharyngeal mucosa and the functional insufficiency of the epiglottis. The author cites Brdlik, who found that in 90 per cent. of the autopsies he observed following bronchoscopies frank status lymphaticus was present. Aspiration of foreign bodies should also be included among the accidents of dentition.

"When bronchostenosis predominated, our observations were in brief: A marked difference in the two sides of the thorax was observed in two of thirteen cases. Modification of the respiratory tone in seven of fourteen, auscultatory findings in twelve of fourteen cases, but these are evidently not always due to bronchostenosis. Thirteen cases were examined by the roentgen ray; results were negative in three cases, in eight there was a modification of the transparency, in four the motility of the diaphragm was limited on the side of the stenosis, in two there was a permanent displacement of the mediastinum to the sound side, and in two others the deviation was to the injured side on inspiration."

Exception was taken to the opinion of some authorities that a certain degree of pulmonary emphysema is due to a tracheobronchitis of inflammatory origin. The author believes that the entrance of the foreign body into

(1) Arch. Internat. de Laryngol. Otol. Rhinol., Nov. 1926.

the air passages produces a spasm of the musculature of the trachea and bronchus, determining an asthmatoid condition. He cites the absence of an elevation of temperature and the disappearance of the symptoms on removal of the foreign body to support his contention. However, should the intervention be delayed, the inflammatory changes may supervene, and the patient may die.

In two cases in which the obstruction had remained for days the emphysema persisted. This might have been due to the limitation of the blood circulation by the greatly dilatated alveoli or to an inflammatory change which affected resorption. It might also be explained by the fact that air retained in the alveoli soon attains a pressure of oxygen and carbonic acid equivalent to that of the venous blood. Two cases were cited to show that the emphysema is not always due to the valvelike mechanism of the foreign body, typified by an inspiratory dilatation permitting the entrance of air about the foreign body, and the expiratory contraction preventing its escape. In one case a fragment of a cigaret holder with a patent lumen was aspirated, and in another case a flat blade of bone. The obstructed bronchus, on account of its reflex spasm, does not function in its normal manner.

The author observed a case of postendoscopic stenosis by direct laryngoscopy. He noted that the stenosis was not the result of subglottic edema, but was due to a fibrinous membrane. Bacteriologic examination did not show the predominance of any organism responsible for a primary fibrinous laryngitis. The author believed that the membrane was the result of the traumatism incident to the bronchoscopy. In such cases he prefers intubation to tracheotomy. While direct laryngoscopy in dangerously dyspneic patients is not practical, he does not hesitate to intubate. If the patient breathes freely after removal of the tube, and after some hours has a recurrence of the dyspnea, he reintubates. However, if

the patient's dyspnea is not relieved after removal of the tube, he believes that tracheotomy should not be delayed. According to the author, intubation should be a valuable procedure in postendoscopic stenosis.

Peroral Endoscopy; Its Use in Complications Following Operations on the Nose and Throat. According to G. Tucker[2] peroral endoscopy, including direct laryngoscopy, bronchoscopy, esophagoscopy and gastroscopy, constitutes a special field in medicine, and requires for its safe and efficient performance special training and the skill that comes from long practice in working through a tube, using only one eye. The otolaryngologist is accustomed to monocular vision, and quickly acquires the ability to interpret correctly the picture seen through the endoscopic tube. He is also familiar with the landmarks of the pharynx and larynx, and is accustomed to operative work and the special technic that is required in the upper air and food passages. The first requisite in the work is an adequate instrumentarium. Small tubes are required for infants and longer tubes for adults. In short, the tube must be adapted to the size of the passage to be examined, and the accessory instrumentarium must be proportionate to the size of the tube. There is no universal endoscopic tube. The instrument for adults will kill an infant. The length of instrument used in an infant will not accomplish the desired result in an adult. Tubes of small diameter are required to enter the peripheral bronchi in the adult. but the length must be adequate to reach the periphery of the adult lung. Notwithstanding these well known facts, a number of cases have been reported in the past in which attempted examination of the child with an adult tube has been followed by fatal results.

Endoscopy is most safely and most successfully performed without an anesthetic or with only a local anesthetic; to carry it out with safety and precision, an endoscopic team, thoroughly drilled in the technic of

(2) Arch. Otolaryng., April, 1927.

the work, is necessary. This is accomplished best by two or more endoscopists working together.

It would seem necessary that every laryngologist should be prepared to examine the larynx of patients of any age. In young children the mirror is useless for this purpose. The diagnosis of laryngeal diphtheria may depend on the taking of a swab, for smear and culture, directly from the larynx, and direct laryngoscopy is the only means by which the larynx of infants and young children may be examined. Again, differential diagnosis of an ulcerative lesion of the larynx may necessiate biopsy. This can be most accurately done by direct laryngoscopy.

The diagnosis of laryngeal stenosis may call urgently for bronchoscopy. Whether or not the otolaryngologist shall prepare himself to use bronchoscopy in cases of foreign body obstruction and esophageal disease is a question that each one must decide for himself. Foreign bodies in the larynx may easily fall into the bronchus or esophagus during attempts at removal and so require bronchoscopy or esophagoscopy. Internists and thoracic surgeons have come to regard blind methods in the diagnosis of esophageal disease as obsolete, because at best such methods can only be inferential and are always extremely dangerous. For consultation and direct inspection of the esophagus, they naturally turn to the otolaryngologist for esophagoscopy.

An infective postoperative pulmonary condition may call urgently for a bronchoscopy, or a foreign body accident occurring during an otolaryngological operation may demand a bronchoscopy or an esophagoscopy. The otolaryngologist who is trained and expert in peroral endoscopy will be able to care for the postoperative complications that may occur in his own practice, although under these circumstances he may prefer to have the responsibility taken by a confrère.

The author presents a group of cases in which foreign body accidents occurred during otolaryngologic pro-

cedures. In over 1,750 foreign body cases that have come to this clinic there have been fourteen cases due to accidents during otolaryngologic operations (Fig. 38). When the enormous number of operations that are performed on the nose and throat every year is considered, it is a great tribute to the careful technic and skill of otolaryngologists that these accidents do not occur more frequently.

The author records each case in detail and summarizes his experience as follows:

"In the first two cases of the group, the infection occurred through the embolic route, and in the last two, the infection was probably inspiratory in origin. These cases illustrate the value of endoscopic procedure in this type of postoperative complication.

"It is peculiar that of these fourteen cases of foreign body accident, occurring during otolaryngologic operations, and referred to the clinic over a period of ten years, eleven were referred during the past year. Is this sudden increase in the number of such cases due to a real increase in the number of these accidents or to the awakened interest of the medical profession in the presence of foreign bodies as a cause of postoperative pulmonary complications? I feel that the apparent increase is due to the recognition by physicians of the true nature of the complication, and that probably during the past many cases were overlooked.

"The enormous demand for careful and safe bronchoscopy for the diagnosis and treatment of pulmonary disease is making serious inroads on the time of the otolaryngologist. There seems to be an increasing need in the large hospitals of the great medical centers for a full equipped bronchoscopic clinic prepared to render safe assistance in the diagnosis and treatment of diseases of the lungs, esophagus and stomach. The logical man for this work is the otolaryngologist, if he has the time."

The Advantages and Disadvantages of the Proximally Illuminated Bronchoscope. In regard to the

Fig. 38.—Foreign bodies inspirated during otolaryngologic operations and removed bronchioscopically: *1*, Whitehead mouth gag lamp removed from right main bronchus; *2*, catch from tonsil forceps and *3*, deciduous tooth, removed from bronchus of rt. lower lobe; *4*, *5*, gold tooth crown and deciduous tooth removed from rt. m. br.; *6*, *7*, *8*, deciduous teeth removed from rt. and l. bronchi; *9*, portion of nasal rasp inspirated during frontal sinus operation, removed from bronchus of l. lower lobe; *10*, tonsil spooge removed from l. m. br.; *11*, tonsil snare wire removed from rt. m. br.; *12*, intubation tube inspirated during intubation, removed from l. m. br.; *13*, wooden applicator and swab inspirated during the taking of a specimen from throat for culture, removed from rt. m. br.; *14*, radium capsule dislodged from antrum and swallowed, removed by gastroscopy from stomach.

technical part of the work—the use of a proximally illuminated bronchoscope which would be employed in a given case, compared with a distally illuminated instrument for the same case—the proximal is larger internally and smaller externally, on account of the absence of the light carrying attachment. In the 4 mm. tube the light carrying channel is over 3 mm. There is no difficulty in illuminating a tube of 5 mm. external diameter. It can be passed into a little child. In the case of a tracheobronchial diverticulum, S. Yankauer[3] cleared out the membrane through that tube.

The illumination with the distally illuminated instrument is in every instance close to the end of the bronchoscope, so that for all work located at the end of the bronchoscope the distal illumination is more than desirable, and it is efficient. It would be absurd to attempt to dispute the efficiency of distal illumination for work situated at the end of the tube, but the point is that the main work of bronchoscopy is in the diagnosis of thoracic diseases. One can do many bronchoscopies if he educates internists to let him make diagnosis for them in obscure thoracic conditions. Thus one may see many things that cannot be seen with distal illumination, because of the comprehensive view of the bronchi. The distal work is like examining a room with a lighted match, whereas proximal illumination is like flooding the whole room with light so that it can be seen at once.

There is no question as to the difference in the tube and the view of the broncial tree in the two methods of illumination. Each method has its particular use, wherein it is more successful than the other method. The difference is in the depth of the illumination. One can see into branches not more than 2 mm. in diameter that are in line with the bronchoscope. With the distal light one cannot see into the same bronchi, no matter how they are situated, because the light is too oblique

(3) Ann. Otol. Rhin. & Laryng., March, 1927.

to get into the bronchi. Benefit can be given to a large number of patients by doing bronchoscopies for diagnostic work. Often one gets foreign body cases in patients where there is no history or *x*-ray findings, and where the case is brought in with other diagnoses. In one particular case the patient was brought in as a case of lung abscess with possible tuberculosis. It was referred for diagnosis and at bronchoscopy a foreign body was found. The ability of the bronchoscopist to make diagnoses well will depend on his experience in doing the work. He can only gain his experience by co-operation with the internist.

Beads as Foreign Bodies in the Bronchi; Mechanical Problems and Their Solution. A glass bead causes little or no pathologic change in the lung other than obstruction. It may be of amber, wood, ivory, bone, glass, metal or composition. In shape it may be spherical, pyriform, conoidal, oval, rectangular, or a combination of two forms.

According to E. J. Patterson[4], there are several mechanical problems involved.

The problem of removal of the bead from a bronchus varies greatly with the size, shape, surface qualities, as well as with the degree of impaction and duration of sojourn.

To get a secure grasp on a spherical or spheroid bead, whether rough or smooth, the forceps blades must be applied beyond the equator.

Pyriform, oval, squared or conoidal beads must have the forceps blades applied beyond the minor axis of the ellipsoid or base of the conoid, as the case may be, to get a secure grasp. The long proximal taper on a pyriform bead is particularly difficult to hold, unless the just mentioned advice be followed.

The hole in the bead, especially when visible endoscopically, presents a great temptation to use it as a means of extraction. It has been so used by a number

(4) Ann. Otol. Rhin. & Laryng., December, 1926.

of bronchoscopists, and the author has tried it on one case. An instrument to slip through the hole in the bead and open on the distal end, with teeth to prevent the bead slipping off, works perfectly in theory, but practically it is disappointing, as the holes in beads are not uniform, and it may be dangerous unless used with the utmost care.

A study of the presentation from the radiograms and endoscopically is important, though in the case of a square sided oval bead it is not always possible to determine endoscopically from the presenting part the position of the flattened sides.

Fundamental in the endoscopic removal of this class of foreign bodies is the forceps spaces, which is the name Jackson has given to the spaces between the foreign body and the wall of the invaded bronchus, into which the jaws of the forceps must go before they can grasp the bead.

The correctly constructed forceps to grasp a bead must have the planes of the grasping forceps parallel instead of divergent, otherwise the grasp is insufficient and the bead will be stripped out of the forceps, and it is better if the distal ends bend slightly toward each other. Serrations in the cups and properly canted are essential. This correct type of forceps is found in the Tucker bead forceps.

The author reports an illustrative case and presents the difficulties encountered in its solution.

A Method of Removing a Bead from a Bronchus. Smooth, round or oval foreign bodies in a bronchus present a peculiar problem. Such objects tend to descend as far as possible, dilating the air tubes and permitting a partial collapse of the lumen above the body. Such a body, if of a hard and smooth character, is almost impossible to engage with any usual grasping instrument, especially if the body is impacted there is insufficient room between it and the walls of the bronchus to permit the passing of an instrument around it. The problem

is further complicated by the fact that even the slightest pressure pushes the foreign body deeper and impacts it more tightly.

In the case of foreign body containing a hole, for an example a bead, the sides of the hole can be used as a grasping surface. If, however, the hole is small, it is difficult to pass into it a probe, or grasping forceps which will be sufficiently strong to be safe.

The method described by S. Jesberg[5] was devised with the aid of J. Cantor in the Bronchoscopic Clinic of the Eye and Ear Hospital, Los Angeles, Cal. The device consists of a steel stylet or probe, the distal end of which contains an eye through which a thin rubber band can be threaded. The probe with the stretched rubber band is made just small enough to pass through the hole in the head. When this is accomplished the tension on the rubber band is released and the expansion of the rubber band locks the bead on the stylet.

A Bronchoscopic Bead Forceps. The removal of an impacted bead from the bronchus offers one of the most difficult problems that confronts the bronchoscopist. Many instruments have been devised for its solution. A number of the instruments are constructed for insertion through the hole in the bead, and in some types of beads these instruments have been successfully used. The disadvantages, however, are the difficulty in getting into the hole of the bead, involving risks of pushing it downward, and, in thin glass beads, of breaking. (Fig. 39.)

The principle of the forceps which G. Tucker[6] presents is that of the heavy model standard Jackson stylet and cannula type that is universally used in bronchoscopic work. The bead forceps are intended to grasp over and distal to the greatest circumference of the bead in cross section as it presents in the bronchus. The forceps are provided with a stiff, expanding spring to enable the blades to repress the bronchial mucous membrane and

(5) Laryngoscope, December, 1926.
(6) Ann. Otol. Rhin. & Laryng., March, 1927.

find their way between the bead and the bronchial wall. The blades are tipped slightly toward each other so that when the forceps are fully opened the blades are parallel. The points are turned slightly inward at the tip, like a parrot's beak, and the width of the blade is cupped deeply to prevent lateral slipping; the cupped surface

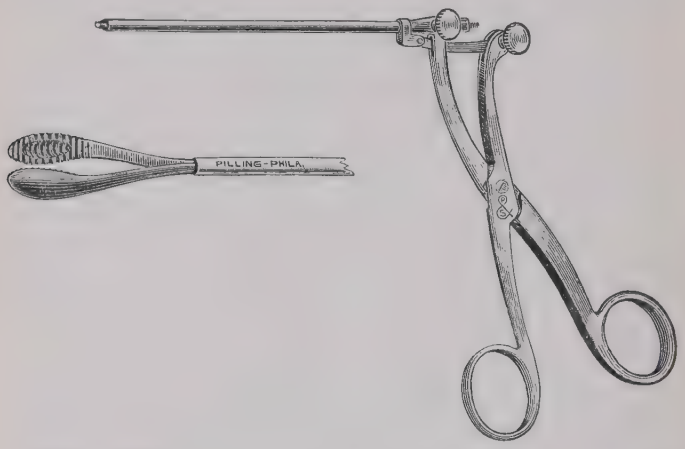

Fig. 39.—Bronchoscopic Bead Forceps: large, 50 cm. in length; small, 40 cm., for use through 4 m.m. tube.

is provided with sharp teeth canted backward, as in the standard Jackson forceps, but the serrations extend down into and across the cup, to provide a firm grasp. This feature, along with the shape, enables the forceps to exert traction at a point distal to the greatest diameter of cross section.

In applying the forceps, it is introduced through the bronchoscope, by sight and sense of touch, until it is in contact with the presenting circumference of the bead. It is then opened and advanced, the tips of the blades follow the surface of the bead, and the stiff spring presses back the mucous membrane until the greatest diameter of the cross section of the bead, as it presents, is in the center of the deeply cupped blades. The forceps are

then closed firmly. The bead is drawn gently out of the bronchus into the trachea, then held firmly against the end of the bronchoscope, and the bronchoscope, forceps and bead are held together and brought out through the glottis as one piece, thus preventing stripping off at the glottis.

The forceps are constructed in two sizes, the smaller to go through a 4 mm. bronchoscope.

Bronchoscopic Lipiodol Instillation Tubes. When lipiodol is to be introduced for pneumonography, it is very desirable first, to have the portion of lung that it is decided to study as free of secretions as possible, so that the liquid can enter. Second, that the lipiodol be introduced into the main bronchi of the portion of lung under study and be allowed to find its way into the deeper portion of the lung without being forced in under pressure. The lung can best be freed of secretions by bronchoscopic aspiration. Following this, thorough cocainization is carried out; and, most important, the excess of solution is aspirated.

The instruments which G. Tucker[7] presents are large caliber tubes with Lynah spiral tips, one with a straight Lynah spiral tip, and the other with an angular Lynah spiral tip, for getting around the corner in the upper and middle lobe bronchi. The lumen of the injecting tube is large, so that the heavy oil will pass readily through; and the proximal end is marked at 5 cm. intervals, so that the distance of the tip carried into the bronchus beyond the tip of the bronchoscope can be determined. The angular tip corresponds in direction to the handle end of the tube.

Rubber tubing is provided for the proximal end, with a metal connection for the standard Luer syringe. The tube is moved slighty in and out as the lipiodol is introduced, the patient being placed in the proper position for gravitation of the oil into the desired area of the

(7) Ann. Otol. Rhin. & Laryng., March, 1927.

lung. Thus the lipiodol goes into the deeper portions of the lung freely but not under pressure.

It is important to have a flexible connection between the instillation tube, which is held by the surgeon, and the syringe, which is in the hands of the nurse. This is provided in this outfit by connecting the tube and syringe with rubber tubing.

False Lung Abscess and Lipiodol. At the present time, according to H. P. Mosher[8], there is great activity in the use of lipiodol for determining the nature of pathologic conditions in the lungs, especially lung abscess and bronchiectasis. So many apparent lung abscesses have been found in the cases referred from the Thoracic Service of the Massachusetts General Hospital to the Throat Department for diagnostic bronchoscopy and the injection of lipiodol that the suspicion has been growing that the shadow which so perfectly simulated an abscess in most cases was an area of "drowned lung"—that is, drowned in lipiodol.

Experiments on dogs have proved that this suspicion is correct. It has been our custom to use 40 per cent. lipiodol. A bronchoscope was passed to the pathologic bronchus and then by means of a cannula inserted through the bronchoscope and into the mouth of the diseased bronchus the solution was injected.

The intact lungs of a dead dog were inflated and kept in this condition. Through a window in the side of the trachea a bronchoscope was introduced and through this the cannula for the lipiodol. A terminal bronchus of the right inferior lobe was injected. The oil was carried by gravity also to the left upper lobe. Typical pictures of lung abscesses were obtained in both places. An attempt was made to evacuate the lipiodol from one of the injected areas. Watching the attempt through the fluoroscope showed that this could not be done. Even after the main bronchus to the injected area was slit open, pressure would not clear the lung of the oil.

(8) Laryngoscope, February, 1927.

The same experiment was tried on a living dog—minus, of course, actual pressure on the injected area, with the same result.

These experiments proved that 40 per cent. lipiodol injected into the terminal bronchus of normal lung will give the picture of a lung abscess. In order not to draw false conclusions, therefore, weaker solutions of lipiodol must be used. Experiments are now being carried on to determine what strength of lipiodol must be used in order to avoid a misleading picture. It is felt that the oil if it is to be of real service must be introduced with a nebulizer, and experiments along this line have been started.

The purpose of this preliminary notice is to call attention to the unfortunate drawback connected with the use of lipiodol, namely, that the saturation of a given area of normal lung with lipiodol will give the *x*-ray picture of a lung abscess.

Bronchiectasis Associated with Disease of the Nasal Accessory Sinus. L. H. Clerf[1] finds that:

1. Abundant clinical observations supported by experimental studies indicate that chronic disease of the nasal accessory sinus is a factor in the production of bronchiectasis. The inhalation route of infection plays an important part in cases of chronic bronchitis; in children, the peribronchitis associated with peritracheobronchial glandular involvement undoubtedly plays an important role.

2. Examination of a patient complaining of chronic cough, with or without expectoration, is never complete until a careful study of the nasal accessory sinuses has been carried out; a negative opinion on sinus disease should not be given until every necessary diagnostic means has been utilized.

3. The unfavorable effect of chronic sinusitis on the bronchial infection in cases of chronic bronchitis sug-

(1) Arch. Otolaryng., July, 1927.

gests a similar influence in cases of associated bronchiectasis.

4. Every patient complaining of unexplainable chronic cough or in whom a questionable diagnosis of bronchiectasis has been made, should receive the benefit of diagnostic bronchoscopic and pneumographic studies, if considered advisable.

5. Irrespective of their etiologic relationship, treatment for a coexisting bronchiectasis and suppurative sinusitis is not complete until the proper treatment is given for diseased nasal accessory sinuses and the bronchial condition.

[We have seen cases of purulent sinusitis associated with bronchiectasis with purulent secretion. We have also seen cases of chronic sinusitis associated with chronic bronchitis, but these have been rather exceptional findings, which are by no means the rule. To examine the problem from the other aspect in cases where a bronchiectasis exists, a search for possible chronic sinusitis, perhaps, would be more to the point. In the eagerness, however, to diagnose the presence of a sinusitis where bronchitis exists, we have seen the tendency to diagnose as sinusitis, conditions which are quite other than the purulent conditions and which will not seem to be a possible factor in producing bronchiectasis.—Ed.]

Bronchoscopy as an Aid in Diagnosis and Treatment of Bronchial Asthma. It is assumed by L. Clerf[3] that cases of asthma referred to the bronchoscopist for treatment have been carefully studied from every standpoint, and that either etiologic factors could not be discovered or the patient did not respond to treatment based on apparent causative factors.

All bronchoscopists are agreed that certain patients with asthmatic symptoms are benefited by bronchoscopic treatments, unaided by other measures. The relief may be temporary or may extend over a period of many

(3) J. A. M. A., Sept. 10, 1927.

months. Although cures have been ascribed to bronchoscopy, time alone can determine the permanence of the benefits obtained; in a majority of instances they will be temporary.

The best results by bronchoscopy are obtained in the treatment of patients who have a chronic tracheobronchitis with increased secretion, either mucoid or purulent in character. Little, if any, improvement can be expected in those cases of asthma which present a chronic tracheobronchitis with cyanotic swollen mucosa and practically no secretion.

Bronchoscopic treatments consist of removal of secretion and the endobronchial introduction of some form of medication. There is an advantage in employing the small flexible-tipped Lynah aspiration tube. This can be carried into the smaller bronchial subdivisions beyond the tip of the bronchoscope. Medication can be introduced by topical applications, or a small quantity can be instilled. Its value is questionable. The endobronchial introduction of cocain and epinephrin (Lukens and Moore) during an asthmatic attack will nearly always give immediate relief. In the author's experience, the use of a preparation of oil of cajuput, monochlorphenol, menthol, mercurochrome-220 soluble and silver nitrate after aspiration has given results which were practically identical with those obtained by simple aspiration of secretion.

Immediately after bronchoscopy there usually occurs more frequent cough, with an increase in the quantity of secretion. The breathing is easier, secretions are expelled with less effort, and the patient is more comfortable. This improvement may be of brief duration or it may continue for weeks or even months.

Primary Carcinoma of the Bronchi. T. McCrae, E. H. Funk, and C. Jackson[2] find evidence suggesting that carcinoma of the lung, which in the great majority of cases originates in a bronchus, is increasing in frequency.

(2) J. A. M. A., Oct. 1, 1927.

These bronchial tumors appear to have a relatively low malignancy, and hence the hope that early diagnosis and intensive roentgen ray therapy may be effectual in at least prolonging life.

Early diagnosis should be made if the possibility of bronchial neoplasm is considered and careful studies are made. The early symptoms are usually those of bronchial irritation and the early signs those of bronchial obstruction.

By bronchoscopy a positive diagnosis can almost always be made promptly and proper treatment instituted. Patients who present obscure pulmonary and bronchial symptoms have a right to the benefit to be derived from bronchoscopy.

Bronchoscopic and Esophagoscopic Observations in Tonsillectomies. This series of cases by L. Daily and R. Daily[1] consisted of:

Deep anesthesia, 30 cases, bronchoscopy only. Blood was found in the tracheobronchial tree in all cases.

Deep anesthesia, 37 cases, bronchoscopy and esophagoscopy. Blood in tracheobronchial tree, and none in the stomach, in 33 cases. Blood in both in two cases. Blood in neither in two cases (bloodless operation).

Attempted light anesthesia, 33 cases, bronchoscopy and esophagoscopy. In 21 cases the entire operation was performed under light anesthesia. Blood in the stomach and not in the lungs in 17 cases. Blood in both in two cases. Blood in the lungs and not in the stomach in two cases.

In the other 12 cases the anesthesia was moderately deep. In three cases there was no blood in the lungs nor in the stomach (bloodless operation). In nine cases there was blood in the lungs and none in the stomach.

The authors believe that the greatest percentage of tonsillectomy cases operated upon in the usual way contain blood in the tracheobronchial tree. The pharyngeal and swallowing reflexes have a more determining effect

(1) Texas State J. Med., August, 1927.

than the laryngeal reflex upon the absence or presence of blood in the lungs.

There is a relation between the presence of blood in the tracheobronchial tree and in the stomach. Usually, when there is blood in the one, there is none in the other, and *vice versa*. Anesthesia, in which the pharyngeal and swallowing reflexes are not abolished, should be the one of choice to prevent blood from entering the tracheobronchial tree.

The tonsils should be removed under light anesthesia, and the anesthesia deepened afterwards if necessary to check bleeding.

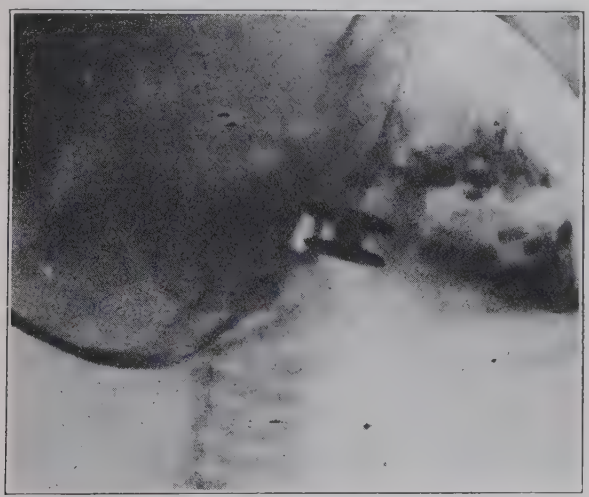

Fig. 40.—Roentgenogram showing a machine bobbin in the nasopharynx of a child 16 months of age. Because of the high position of the foreign body it might readily have been overlooked had the roentgenologist included only the neck and chest in the routine examination. (Films by Dr. W. F. Manges.)

Foreign Bodies in the Esophagus. L. H. Clerf[9] reports twelve cases, selected from a personal series numbering over two hundred. These cases illustrate the

(9) Ann. Otol., Rhin. & Laryng., December, 1926.

commoner causes for the overlooking of foreign bodies in the esophagus (Figs. 40 and 41).

Fig. 41.—Roentgenogram made by Dr. W. F. Manges reveals the bismuth mixture surmounting, in caplike fashion, a non-opaque, ovoid object at the level of the suprasternal notch. No bismuth passed beyond this point, indicating that the obstruction to the esophageal lumen was complete. The foreign body proved to be a pecan nut, which was non-opaque to the roentgen ray.

Summarizing his experience the author gives the following:

1. Initial symptoms of choking and gagging should always indicate the possibility of foreign body and call for its exclusion.

2. Roentgen ray studies for foreign body in the alimentary canal should include the entire food passages from the nasopharynx to the terminal portion of the rectum, inclusive.

3. In cases of nonopaque foreign bodies in the esophagus the roentgenologist cannot give a definite opinion until he has used a radiopaque material, either in capsule or as a mixture.

4. To be of value in solving mechanical problems radiograms should be made in the anteroposterior and in the lateral position (the latter at the right angles to the former). In addition to these, the roentgenologist should make films which show the greatest plane of the foreign body.

5. Every patient suffering with dyspnea of unknown etiology should be examined with the roentgen ray to rule out, among other things, the presence of an esophageal foreign body.

6. Persistence of symptoms referable to the esophagus in the presence of negative roentgen ray findings calls for a diagnostic esophagoscopy.

Cicatricial (Benign) Stricture of the Esophagus; Tabulated Report of 186 Cases. In this series of cases reported by P. P. Vinson[1], lye ingestion was the cause of the stricture in 102 of the 186 cases. Eighteen were of unknown etiology, 14 followed typhoid, 13 gave a history of vomiting of pregnancy and 7 were congenital. The remaining cases gave a variety of conditions which led to the stricture.

The youngest patient was 17 months, the oldest, 75 years. There were 87 cases, 15 years and younger, and 99 cases, 16 years and older. The location of the stricture was located as follows: Upper third, 75 cases; middle third, 46 cases; lower third, 43 cases, and not stated, 22 cases.

In the treatment the author recommends giving olive oil immediately after the burn as an antidote and first-aid treatment. If, during the acute stage, the closure is complete, fluids should be given per rectum or subcutaneously. As soon as the acute reaction is over, usually in about four days, the patient should

(1) Ann. Otol., Rhin. & Laryng., March, 1927.

swallow a twisted silk thread. This can then be used later for guiding sounds through the stricture. The use of the thread made gastrostomy unnecessary in all save twelve cases.

Secondary closure from contraction of scar tissue usually reduces the lumen of the esophagus in six weeks to a size that will not permit the free passage of liquids, and at this time it is necessary to begin dilatations. At first a 30 F. sound is passed through the stricture, using the thread as a guide. By passing increasingly larger sounds at intervals it is possible to use the 45 F. sound by the end of the third or fourth month. Following this dilatations are carried out as indicated.

If no progress is made in ingesting the thread, there are two alternatives: gastrostomy or esophagoscopy, with the introduction of a ball tipped piano wire through the stricture, followed by the dilating sounds. Esophagoscopy was employed in 31 cases, with 3 fatal results. Gastrostomy in 12 cases was followed by 3 deaths. Five deaths followed the first dilatations, and 10 other cases died from other causes. The remaining cases have been successfully treated, although prolonged observation and treatment have been frequently required.

Treatment of Carcinoma of the Esophagus: Based on 100 Personal Cases and 18 Post-Mortem Reports. H. S. Souttar[2] finds carcinoma of the esophagus four times as frequent in men as in women. The condition is found at the upper end of the esophagus in more than 80 per cent of cases. The most usual histological type of carcinoma is the squamous epithelioma. The malignant tumor spreads by way of the lymphatics and tends to grow around the esophagus and to produce stenosis. The commonest termination is perforation of the esophagus into the respiratory system, with the development of acute bronchopneumonia or of gangrene of the lung.

In the examination of these cases the author makes use of the esophagoscope. The best form of treatment

(2) Brit. J. Surg., July, 1927.

consists in introducing an intubation tube by means of the esophagoscope after dilating the strictured area as far as possible with the author's special dilators.

In a large majority of cases the immediate result of intubation is extremely satisfactory. With few exceptions the patients are able next day to swallow liquids and soft foods with perfect facility. In the case of an emaciated man who has been starved for weeks it is necessary to proceed with caution, but the average patient leaves the hospital two days later, having had two poached eggs, fried bread, toast, and coffee for breakfast. As several of the author's patients had for some days been unable to swallow even the smallest drop of fluid, the change was a very remarkable one, and in most cases the relief lasted for the lifetime of the patient.

In a series of 98 cases the author has performed intubation on 50 occasions, and the statistical results are as follows: seven patients died soon after the operation, but in only two of these was there any reason to suppose that death was due to the manipulations involved. In one of these, a case with extreme emaciation, it was thought that the esophagus was torn in inserting the tube; in the other, the end of the tube had perforated the base of a large carcinomatous ulcer. In the remaining 5 cases, one death was due to exhaustion, one to mediastinal suppuration, one to subphrenic abscess, one to perforation of the lung, and one to perforation and gangrene of the lung. In each case it was ascertained that the cause of death was not the result of the intubation, but occurred in the natural course of the disease. The true operation mortality of this series is therefore 4 per cent., and one may hope to avoid even this by greater experience.

As to the duration of life after intubation or dilatation followed by intubation, in 26 cases followed to a conclusion, this varied between 2 weeks and 23 months, the average being 5.3 months. Of the other cases, some have been lost sight of, but many are still alive, in good

health after periods up to 7 months. In those who have died, death has resulted from pure exhaustion or from one of the complications. In some dysphagia recurs, and in these the author has on several occasions demonstrated an extension of the growth above the level of the tube. But most of the patients had swallowed satisfactorily till near the end.

As compared with these figures, gastrostomy was performed in 20 cases with 7 deaths, in each case with some complication unconnected with operative technic. The average duration of life of the survivors in 10 cases followed up was 3.6 months.

Without unduly stressing these figures, the author thinks they prove that intubation is far safer than gastrostomy, and that it affords a longer expectation of life. From the patient's point of view, however, two methods could scarcely be in greater contrast. After gastrostomy he is an invalid, kept alive by artificial feeding and debarred from the exercise of a function without which life is not worth living. After a successful intubation by this method he can eat and drink almost like a normal man, he can enjoy a meal with his family, and there is nothing objective to remind either himself or his family of his disease. It is reasonable to hope that with further experience such a result will in most cases be obtainable, and it seems to be all that one can ask in a disease which is entirely beyond the possibility of surgical cure.

INDEX

Abscess, cerebellar, meningitis, sinus thrombosis: recovery after opening cisterna pontis, 261; false lung abscess and lipiodol, 498; of frontal lobe following sinus disease, 380

Acoustic tube, treatment of deafness by auditory re-education with acoustic tube, 304

Adenoids, hemorrhage following removal of tonsils and adenoids, 432; postadenoidal speech, 476

Amebiasis, ocular diseases occurring in the course of nondysenteric amebiasis, 153

Anesthesia, barbitol as a preventive of cocain toxicosis, 336; ephedrin and cocain synergy, 333; epiglottis in respiratory obstruction under anesthesia, 455; local, in external operations on nasal accessory sinuses, 371; stovain in otorhinolaryngology, 334; therapeutic value of ephedrin in rhino-laryngology, 332; tutocain: local anesthetic in rhino-laryngology, 333; unusual effects from the use of cycloplegics in ocular therapeutics, 180; use of ephedrin in bronchial asthma and hay fever, 331; use of ephedrin in rhinology, 332

Aneurysm, carotid, aneurysm of the internal carotid artery, 82

Angina, experimental sore throat, 444; lacunaris, further investigation concerning changes in lymph follicles in angina lacunaris, 419; Vincent's, oral lesions due to, 406

Anomalies, congenital, of eye, 1; hereditary abnormalities, 1; misconceptions in diagnosis of motor anomalies, 57

Antrum (see Sinuses); new antrum and frontal rasps, 354; treatment of antral disease by simple tube drainage, 368

Argyll-Robertson pupil, explanation of, 118

Arteries, carotid, aneurysm of the internal carotid artery, 82

Asthma, bronchoscopy as an aid in diagnosis and treatment of bronchial asthma, 500; diseases of upper respiratory tract in relation to etiology and treatment of bronchial asthma, 320; house dust in etiology of bronchial asthma and of hay fever, 325; indications for surgery in treatment of hay fever and asthma, 327; iodipin in the diagnosis of nasal sinus conditions, 349; nose and throat observations in examination of patients with bronchial asthma, 328; relation of, to nose and throat surgery, 323; rhinologic study of bronchial asthma, 326; tissue hydration and its relation to susceptibility and immunity, as shown by skin tests in asthma, chronic sinusitis and

other infections, 317; use of ephedrin in bronchial asthma and hay fever, 331

Bacillus pyocyaneus, ulceration of the cornea due to b. pyocyaneus, 111
Barbitol (see Anesthesia)
Blepharochalosis, 86
Blood, coagulation test, 418; coagulation time prior to tonsillectomy, 416
Bone conduction, problem of; theoretical considerations, 301; endonasal treatment of an ethmoid-frontal mucocele, 377; experiences with orbito-ethmoidal osteomata having intracranial complications, 378; four years clinical experience in surgical treatment of ozena by implantation of macerated spongy bone of cattle, 386; treatment of obstructing inferior turbinates, 388
Bronchi, beads as foreign bodies in the bronchi: mechanical problems and their solutions, 493; manifestation of uremia in pharynx, larynx, trachea and bronchi, 313; primary carcinoma of the bronchi, 501
Bronchiectasis associated with disease of nasal accessory sinus, 499
Bronchitis, diseases of upper respiratory tract in relation to etiology and treatment of bronchial asthma, 320; house dust in etiology of bronchial asthma and of hay fever, 325; indications for surgery in treatment of hay fever and asthma, 327; infections of accessory nasal sinuses: as cause of chronic nontuberculous bronchitis, 356; iodipin in the diagnosis of nasal sinus conditions, 349; membranous laryngitis and tracheobronchitis (nondiphtheritic), 463; nose and throat observation in examination of patients with bronchial asthma, 328; relation of asthma to nose and throat surgery, 323; rhinologic study of bronchial asthma, 326; tissue hydration and its relation to susceptibility and immunity, as shown by skin tests in asthma, chronic sinusitis and other infections, 317; use of ephedrin in bronchial asthma and hay fever, 331
Bronchoscopy and esophagoscopy, 486; advantages and disadvantages of the proximally illuminated bronchoscope, 490; as an aid in diagnosis and treatment of bronchial asthma, 500; beads as foreign bodies in the bronchi: mechanical problems and their solutions, 493; bronchoscopic and esophagoscopic observations in tonsillectomies, 502; bronchoscopic bead forceps, 495; bronchoscopic lipiodol instillation tubes, 497; contributions to study of foreign bodies in respiratory tract, 486; method of removing a bead from a bronchus, 494; peroral endoscopy: use in complications following operations on nose and throat, 488

Cancer (see Tumor)
Carcinoma (see Tumor), of mouth: types and degrees of malignancy, 409
Cataract, extraction, 127; extraction of lens entire in capsule without iridectomy, 129; facoerisis, 130; lenticular opacities, 121; operation, blocking of main trunk of facial nerve in cataract operations, 133; operation, immunity in, 132
Catarrhal dilatation, endonasal

treatment of an ethmoid-frontal mucocele, 377; inflammation of nasal accessory sinuses and its diagnosis, 351
Cerebral lesions, optic nystagmus and its value in the localization of cerebral lesions, 81
Chancre of nasal septum: three cases, 390
Charts for testing eyes, 204
Children, disturbances of production of rhythm in deaf-mute children, 300; latent influenzal otitis in, 228; ossicles in middle ear suppuration and their comparative size in children and adults, 227; otitis media in infants, 229; strabismus, general practitioner and the child with squint, 79
Coagulation, electro-coagulation as an adjunct in tonsil dissections, 443; technic of tonsil electro-coagulation (diathermy), 440; test, 418; time prior to tonsillectomy, 416
Cocain (see Anesthesia)
Colds, diathermy for common cold, 318
Conjunctiva and cornea, role played by epithelium in infections of the conjunctiva and cornea, 91; phlyctenules, causation of, 96
Cornea, conjunctiva and, role played by epithelium in infections of, 91; inflammation of, keratitis as a complication of Dengue fever, 114; phlyctenules, causation of, 96; plastic repair of perforation of the cornea, 118; translucency of, 116; ulceration of the cornea due to bacillus pyocyaneus, 111
Cough, undiagnosed, 316
Cryptophthalmus, hereditary abnormalities of the eye, 1
Deafness, case of unilateral deafness following radiotherapy, 307; chronic middle ear, 240; diathermy in treatment of, 306; electrophonoide treatment, 304; explanation for symptom of paracusus willisi, 289; fragilitas ossium and deafness, 291; nature of progressive deafness, 291; philosophy of the older tests of hearing, 207; problem of bone conduction: theoretical considerations, 301; progressive, endocrine malfunction as important etiological factor, 296; scientific fundamentals of the correction of defects in hearing, 301; technic for voice test of hearing, 212; three million deafened school children, 209; treatment of, by auditory re-education with an acoustic tube, 304; vertigo and deafness associated with hypothyroidism, 297
Deaf-mute children, disturbances of production of rhythm in, 300
Dengue fever, keratitis as a complication of Dengue fever, 114
Dermatitis, intractable forms of, of external ear in cases of chronic suppurative otitis media, 219
Diagnosis, eye symptoms (see Eyes)
Diathermy for common cold, 318; in treatment of deafness, 306
Diphtheria infection of middle ear and mastoid, 234; primary, of outer ear (case), 217

Ear, case of unilateral deafness following radiotherapy, 307; diathermy in treatment of deafness, 306; disturbances of production of rhythm in deaf-mute children, 300; ear,

nose and throat in relation to general medicine, 298; endocrine hypofunction in ear disease, 293; explanation for symptom of paracusis willisi, 289; fragilitas ossium and deafness, 291; method of removing the organ of hearing from the cadaver without cosmetic defect, 300; microscope for ear, magnifying from ten to fifty times, 285; otitic meningitis, 262; otosclerosis, is there an endocrine factor? 296; problem of bone conduction: theoretical considerations, 301; progressive deafness, endocrine malfunction as important etiological factor, 296; progressive deafness, nature of, 291; scientific fundamentals of the correction of defects in hearing, 301; some neurologic complications of ear, nose and throat, 299; stovain in otorhinolaryngology, 334; systemic otogenous infections, 246; tic douloureux cured by mastoidectomy, 286; training in otolaryngology, 311; treatment of deafness by auditory re-education with an acoustic tube, 304; use of foreign bodies in ear, nose and throat surgery, 345; vaccinotherapy in otolaryngology, 314; vertigo and deafness associated with hypothyroidism, 297

Ear, external, common inflammatory affections of skin of external ear, 220; eczema, protein-body therapy in chronic eczema of ear, 219; intractable forms of dermatitis of the external ear in cases of chronic suppurative otitis media, 219; pre-auricular fistulae, 216; primary diphtheria of outer ear (case), 217

Ear, internal, infections, management of six cases, 285; influence of vision on vestibular turning and after-nystagmus, 280; is the exenteration of the labyrinth justifiable in the absence of labyrinthine suppuration? case report, 274; labyrinthitis, a complication of middle-ear suppuration: a clinical and pathological study, 280; models of the labyrinth, 273; neurolabyrinthitis of focal infection in a case with a plus-four Wassermann, 283; propulsion vertigo, 277; some additional cases of vestibular disturbances, 278

Ear, middle, artificial perforation of drum membrane to improve hearing; new method to create a persistent perforation, 223; chronic middle ear deafness, 240; chronic otitis media in 1911-1921, at University ear clinic in Frankfurt-on-the-Main, 243; chronic otitis media in the tuberculous, 235; diphtheria infection of middle ear and mastoid, 234; erosion of petrous bone by acoustic nerve tumor, 271; malignant tumors of the temporal bone, contributions to clinical signs and histology of, 270; mastoid suction-wiper, 255; otitis, latent influenzal otitis in children, 228; otitis media in infants, 229; ossicles in middle ear suppuration and their comparative size in children and adults, 227; peculiarities and possibilities of surgical removal of neuromas of acoustic nerve, 272; scarlet fever otitis, report of sixty-six cases, 233; significance and value of microscopic investigation of middle ear suppuration in serial

sections, 268; technic of vibratory massage of tympanum through eustachian tube, 224; tuberculosis of middle ear, with especial reference to heliotherapy, 237; visualizing of eustachian tube by roentgen ray, 225
Eczema of ear, protein-body therapy in chronic eczema of ear, 219
Electrophonoide treatment of deafness, 304
Encephalitis lethargica, treatment of, by removal of possible etiological factors, 342
Endoscopy, peroral: its use in complications following operations on nose and throat, 488
Ephedrin (see Anesthesia)
Epinephrin (see Nose)
Epithelium, role played in infections of the conjunctiva and cornea, 91
Esophagoscopy, 486; bronchoscopic and esophagoscopic observations in tonsillectomies, 502; contribution to study of foreign bodies in respiratory tract, 486; peroral endoscopy: use in complications following operations on nose and throat, 488
Esophagus, cicatricial (benign) stricture of the esophagus: tabulated report of 186 cases, 505; foreign bodies in, 503; treatment of carcinoma of esophagus: based on 100 personal cases and 18 postmortem reports, 506
Eustachian tube, technic of vibratory massage of tympanum through eustachian tube, 224; visualizing of, by roentgen ray, 225
Eyelids, abnormalities, hereditary: anomalies affecting the entire eyeball, 1; blepharochalosis, 86; defects, epicanthus distichiasis, 1; ptosis, 1; 86; sarcoma of, 89; utilization of upper eyelid for repair of small facial defects, 346
Eyes, abnormalities, hereditary-anomalies of entire eyeball, 1; accommodation, refractive changes, 44; accommodation, the psychology of refraction, 40; contra-indications in arsenical treatment of syphilis, 188; enucleation of eyeball with implantation of endogenous cartilage, 198; examination, charts for testing eyes, 204; Loewi's Midriatic test for acute pancreatitis, 39; ophthalmoscopic evidence of general circulatory disease, 16; periodical examination, 25; slit-lamp ophthalmoscopy, 33; diagnosis, 37; diagnosis, some misconceptions in the diagnosis of motor anomalies, 59; diseases, use of dionin in ophthalmology, 184; inflammation, foreign protein in treatment of inflammations of eye, 186; injuries and previous condition, 174; injuries, industrial, 175; movement, causes of concomitant strabismus, 68; photography of the fundus, 34; protection, looking at the sun, 137; retinitis pigmentosa, 139; stereophotography of the anterior eyeball, 36; (see Retina, Squint, Strabismus, Trochoma, Vision)

Face, reconstructive surgery: with presentation of cases and lantern slide demonstration, 347; utilization of upper eyelid for repair of small facial defects, 346
Facial nerve, blocking of main

trunk of facial nerve in cataract operations, 133
Facoerisis (see Cataract, Extraction)
Fistulae, pre-auricular, of external ear, 216
Focal infection in its relation to medical problems: its uses and abuses, 319; plea for conservatism in treatment of optic nerve disturbance from focal infections, 338
Follicles (see Glands)
Forceps, mechanical exactness in operating for strabismus, 70
Fragilitas ossium and deafness, 291
Fever, keratitis as a complication of Dengue fever, 114; scarlet fever otitis: report of sixty-six cases, 233

Glands, further investigation concerning changes in lymph follicles in angina lacunaris, 419; lacrimal, mumps of, 109; thymus, 343
Glaucoma, hereditary abnormalities of the eye, 1; inflammatory, a nonoperative treatment, 169; some features of glaucoma important to the general practitioner, 159; without appreciable rise in intra-ocular pressure, 171

Hay fever, house dust in etiology of bronchial asthma and of hay fever, 325; indications for surgery in treatment of hay fever and asthma, 327; use of ephedrin in bronchial asthma and hay fever, 331
Headaches, the nasal aspect of, 347
Hearing, artificial perforation of drum membrane to improve hearing: new method to create a persistent perforation, 223
Hearing tests, philosophy of the older tests of hearing, 207; technic for voice test of hearing, 212; three million deafened school children, 209
Heliotherapy, tuberculosis of middle ear, with especial reference to, 237
Hemorrhage, electro-coagulation as an adjunct in tonsil dissections, 443; hemorrhage following removal of tonsils and adenoids, 432; ligature-carrying tonsillar hemostat, 439; method which insures practical control of hemorrhage in connection with the operation of tonsillectomy, 433; technic of tonsil electro-coagulation (diathermy), 440
Hydrophthalmus, hereditary abnormalities of the eye, 1

Infants (see Children)
Influenzal otitis, latent, in children, 228

Instruments, new, acoustic tube, treatment of deafness by auditory re-education with, 304; antrum and frontal rasps, 354; bronchoscopic bead forceps, 495; bronchoscopic lipiodol installation tubes, 497; folding Beebe loupe, 202; George strabismus forceps, Boynton tucking forceps, scale and use of Stevens tropometer, 70; head mirror, 203; iridocapsulotomy scissors, 198; ligature-carrying tonsillar hemostat, 439; mastoid suction-wiper, 255; mechanical larynx, 469; microscope for ear, magnifying from ten to fifty times, 285; Molt and Storz modification of tonsil guillotine, 443; ophthalmoscope, 200; producing

bloodless tonsillectomy, 437; tracheotomy tube, permanent use of, 471
Iodipin in diagnosis of nasal sinus conditions, 349
Iredectomy, extraction of lens entire in capsule without iridectomy, 129
Iris, Argyll-Robertson pupil, explanation of, 118; recurrence of iritis as influenced by removal of infections, 120; the uveal tract, 149

Keratitis as a complication of Dengue fever, 114

Labyrinth, is the exenteration of the labyrinth justifiable in the absence of labyrinthine suppuration? case report, 274; models of, 273
Labyrinthitis, a complication of middle-ear suppuration: a clinical and pathological study, 280; neurolabyrinthitis of focal infection in a case with a plus-four Wassermann, 283
Lacrimal apparatus, endonasal treatment of an ethmoid-frontal mucocele, 377; mumps of the lacrimal glands, 109
Lagophthalmus, hereditary abnormalities of the eye, 1
Laryngology, stovain in oto-rhinolaryngology, 334; therapeutic value of ephidrin in rhino-laryngology, 332; tutocain: local anesthetic in rhino-laryngology, 333
Larynx, diagnosis and treatment of laryngeal tuberculosis, 461; epiglottis in respiratory obstruction under anesthesia, 455; is radium a cure for cancer of larynx? inquiry based on study of end-results, 466; laryngography, 467; light treatment of laryngeal tuberculosis, 462; manifestation of uremia in pharynx, larynx, trachea and bronchi, 313; mechanical, 469; membranous laryngitis and tracheobronchitis (nondiphtheritic), 463; operative relief of laryngostenosis, 468; relation of oral articulative movements of speech and of extrinsic laryngeal musculature in general to function of vocal cords, 480; training in otolaryngology, 311; trichloracetic acid in treatment of ulcerative laryngeal tuberculosis, 459; tuberculosis of, 460
Leucocytosis, postoperative, and temperature variations following tonsillectomy, 426
Lens, cataract extraction, 127; crystalline, lenticular opacities, 121; extraction of lens entire in capsule without iridectomy, 129; immunity in cataract operation, 132
Lesions, cerebral, optic nystagmus and its value in the localization of cerebral lesions, 81
Lip, chronic (streptococcic) hypertrophy of lower lip, 402; harelip and cleft palate, 399; shortcomings in surgery of cleft lip and palate with suggestions for meeting them, 401; surgery of mouth and face with special reference to cleft palate and cleft lip, 398
Lipiodol, bronchoscopic lipiodol installation tubes, 497; false lung abscess and lipiodol, 498
Lung, false lung abscess and lipiodol, 498

Mastoid, diphtheria infection of middle ear and mastoid, 234; diseased, as source of focal infection, 248; double

pneumatic mastoid, 253; suction-wiper, 255
Mastoid operation, after treatment and results of simple and radical mastoid operations, Schwartze method, 255; Koerner method, 257; new and simple plastic-flap method in radical operation, 258; ultimate treatment of radical mastoid operation, 260
Mastoidectomy, tic douloureux cured by mastoidectomy, 286
Mastoiditis, acute, indications for and technic of early operation in acute mastoiditis, 250; clinical value of roentgenography of temporal bone, 244; incidence of otitis in 15,000 acute exanthemata, with report of method of handling scarlet fever otitis mastoiditis at Philadelphia Hospital for contagious diseases, 252; otitic meningitis, 262; sinus thrombosis; cerebellar abscess, meningitis: recovery after opening cisterna pontis, 261; systemic otogenous infections, 246
Medicine, ear, nose and throat in its relation to general medicine, 298
Meningitis, otitic, 262; sinus thrombosis; cerebellar abscess, meningitis: recovery after opening cisterna pontis, 261
Microphthalmus, hereditary abnormalities of the eye, 1
Microscope for ear, magnifying from ten to fifty times, 285; slit-lamp ophthalmoscopy, 33
Mouth, carcinoma of: types and degrees of malignancy, 409; chronic (streptococcic) hypertrophy of lower lip, 402; lesions of tongue, with special reference to their location, 410; observations on salivary secretions and associated clinical findings, 403; oral lesions due to Vincent's angina, 406; ranula, 404; surgery of mouth and face with special reference to cleft palate and cleft lip, 398
Mucocele, endonasal treatment of an ethmoid-frontal mucocele, 377
Mumps of the lacrimal glands, 109

Nephritis, tonsillectomy in, 423
Neuroma (see Tumor)
Neuritis, retrobulbar, associated with sphenoidal and ethmoidal sinusitis, 143
Neurologic complications of ear, nose and throat, 299
Nose, abscess of frontal lobe following sinus disease, 380; atrophic rhinitis: report of eighty cases, 387; bronchiectasis associated with disease of nasal accessory sinus, 499; catarrhal inflammation of the nasal accessory sinuses and its diagnosis, 351; chancre of nasal septum: three cases, 390; ear, nose and throat in relation to general medicine, 298; effect of camphor, eucalyptol and menthol on the vascular state of the mucous membrane, 312; endonasal treatment of an ethmoid-frontal mucocele, 377; four years' clinical experience in surgical treatment of ozena by implantation of mascerated spongy bone of cattle, 386; influence of negative pressure in the sphenoid on optic nerve, 375; intranasal radium therapy in malignant and benign tumors, 393; iodipin in the diagnosis of nasal sinus conditions, 349; nasal aspect of headaches, 347; nasal infec-

tions, inactivation of epinephrin by certain colloidal silver preparations, 337; nasopharyngeal atresia, 452; observations of nose and throat in examination of patients with bronchial asthma, 328; observations on reaction of normal nasal mucous membrane, 312; osteoma of frontal, maxillary, and sphenoid sinuses, 381; pathologic anatomy of malignant tumors of nasopharynx, 541; peroral endoscopy: use in complications following operations on nose and throat, 488; radium in treatment of nasal polypi, 390; significance of germinal substance in incidence of ozena, 388; some neurologic complications of ear, nose and throat, 299; torula infection of nasopharynx, 448; treatment of atrophic rhinitis by ivory implants, 386; treatment of encephalitis lethargica by removal of possible etiological factors, 342; treatment of obstructing inferior turbinates, 388; tuberculosis of nasal fossae, 394; use of foreign bodies in ear, nose, and throat surgery, 345; vaccinotherapy in otolaryngology, 314

Nose, sinuses, chronic frontal sinusitis: surgical treatment, 363; conservatism in treatment of optic nerve disturbance from focal infection, 338; diagnosis of chronic maxillary sinusitis: comparative value of roentgenographic and physical observations, 360; foreign bodies in the accessory sinuses, 376; indications for radical frontal sinus operation with report on case, 365; infection of accessory nasal sinuses: as cause of chronic nontuberculous bronchitis, 356; injection of iodized oil into sinuses, with special reference to the technic in the sphenoidal sinuses, 351; local administration of bacterial vaccines in treatment of subacute and chronic nasal sinus conditions, 367; nasal accessory sinuses, 349; paranasal sinus infection and swimming, 358; pathologic examination in cavernous sinus thrombosis, 345; relation of inflammation of maxillary sinus to that of nose and other paranasal sinuses, 359; treatment of antral disease by simple tube drainage, 368

Nose, surgery, intranasal ethmoid and frontal sinus operation, 370; local anesthesia in external operations on nasal accessory sinuses, 371; method of choice for correction of saddle nose, 397; relation of asthma to nose and throat surgery, 323; two-stage operation for suppurative frontal sinusitis with external manifestations, 373

Nystagmus, influence of vision on vestibular turning and after-nystagmus, 280; optic, and its value in the localization of cerebral lesions, 81

Ocular disease occurring in the course of nondysenteric amebiasis, 153

Ocular fundus in the acute toxemias, 150.

Ocular inflammation, the prostate as a remote focus of infection in ocular inflammation, 149

Ocular muscles, external, 59; some misconceptions in the diagnosis of motor anomalies, 59

Ocular pressure, glaucoma without appreciable rise in intra-ocular pressure, 171
Ocular therapeutics, contra-indications in arsenical treatment of syphilis, 188; dionin in ophthalmology, 184; enucleation of eyeball with implantation of endogenous cartilage, 198; foreign protein in treatment of inflammations of eye, 186; radium in ophthalmology, 191; radium in some ocular conditions, 193; unusual effects from the use of cyclopegics, 180
Oil, injection of iodized oil into sinuses, with special reference to the technic in the sphenoidal sinuses, 351
Optic nerve, conservatism in treatment of optic nerve disturbance from focal infection, 338; disturbances from focal infection, 140; influence of negative pressure in the sphenoid on optic nerve, 375; retrobulbar neuritis associated with sphenoidal and ethmoidal sinsuitis, 143; rhinological findings and treatments of cases of retrobulbar optic neuritis, 340
Optic nystagmus and its value in the localization of cerebral lesions, 81
Ophthalmology, dionin in, 184; prophylaxis and treatment of ophthalmia neonatorum, 104; radium in, 191
Ophthalmoscope, new, 200
Ophthalmoscopy (see Eyes, examination); slit-lamp ophthalmoscopy, 33
Orbit, hemangioma of, 145
Ossicles in middle ear suppuration and their comparative size in children and adults, 227
Osteomata (see Tumor)
Otitis media, chronic, in 1911-1921, at University ear clinic in Frankfurt-on-Main, 243; chronic, in the tuberculous, 235; chronic middle ear deafness, 240; latent influenzal otitis in children, 228; in infants, 229; intractable forms of dermatitis of external ear in cases of chronic suppurative otitis media, 219; scarlet fever otitis: report of sixty-six cases, 233; tuberculosis of middle ear, with especial reference to heliotherapy, 237
Otolaryngology, training in, 311; vaccinotherapy in, 314
Otosclerosis, is there an endocrine factor in? 296
Ozena (see Nose)

Palate, aids to palatal sufficiency after cleft palate operations, 400; harelip and cleft palate, 399; improvement of speech in cleft palate cases, preliminary paper, 474; shortcomings in surgery of cleft lip and palate with suggestions for meeting them, 401; surgery of mouth and face with special reference to cleft palate and cleft lip, 398
Pancreas, Loewi's midriatic test for acute pancreatitis, 39
Paracusis willisi, explanation for symptom of, 289
Paralysis, surgical treatment of paralysis of vocal cord and of diaphragm, 482; unusual effects from the use of cycloplegics in ocular therapeutics, 180
Pemphigus (see Throat)
Pharynx, manifestation of uremia in pharynx, larynx, trachea and bronchi, 313; nasopharyngeal atresia, 452; pathologic anatomy of malignant tumors of nasopharynx, 451; retropharyngeal (? ton-

sillar) myxosarcoma observed during twenty-two years, 447; torula infection of naso pharynx, 448
Photography, laryngography, 467; of the fundus, 34; stereophotography of the anterior eyeball, 36
Phlyctenules, causation of, 96
Plastic surgery, after treatment and results of simple and radical mastoid operations, Schwartze method, 255; Kcerner method, 257; aids to palatal sufficiency after cleft palate operations, 400; enucleation of eyeball with implantation of endogenous cartilage, 198; facial reconstructive surgery: with presentation of cases and lantern slide demonstration, 347; four years' clinical experience in surgical treatment of ozena by implantation of macerated spongy bone of cattle, 386; mastoiditis, indications for and technic of early operation in acute mastoiditis, 250; method of removing the organ of hearing from the cadaver without cosmetic defect, 300; new and simple plastic-flap method in radical mastoid operation, 258; repair of perforation of the cornea, 118; shortcomings in surgery of cleft lip and palate with suggestions for meeting them, 401; surgical treatment of paralysis of vocal cord and of diaphragm, 482; treatment of atrophic rhinitis by ivory implants, 386; ultimate treatment of radical mastoid operation, 260; use of foreign bodies in ear, nose and throat surgery, 345; utilization of upper eyelid for repair of small facial defects, 346
Practitioner, general, and the child with squint, 79; some features of glaucoma important to the general practitioner, 159
Prophylaxis (see Trachoma)
Ptosis (see Eyelids)
Pupil, Argyll-Robertson pupil, explanation of, 118

Radiotherapy, case of unilateral deafness following, 307
Radium in ophthalmology, 191; intranasal radium therapy in malignant and benign tumors, 393; irradiation of diseased tonsils, 429; is radium a cure for cancer of larynx? inquiry based on study of end-results, 466; radium therapy insome ocular conditions, 193; radium treatment of nasal polypi, 390; treatment of diseased tonsils by means of radium, 430
Ranula, 404
Refraction (see Eyes, accommodation and refraction)
Retina, interpretation of retinal folds, 133; looking at the sun, 137
Retinitis pigmentosa, 139
Rhinitis, atrophic rhinitis: some findings in a series of eighty cases, 378
Rhinology, cerebrospinal rhinorrhea: study of case and reports of twenty, collected from literature since 1900, 396; rhinologic study of bronchial asthma, 326; rhinological findings and treatments of cases of retrobulbar optic neuritis, 340; stovain in otorhinolaryngology, 334; therapeutic value of ephedrin in rhino-laryngology, 332; treatment of atrophic rhinitis by ivory implants, 386; tutocain: local anesthetic in rhino-laryngol-

ogy, 333; uses of ephedrin in, 332
Rhythm, disturbances of production of rhythm in deaf-mute children, 300
Roentgenology, diagnosis of chronic maxillary sinusitis: comparative value of roentgenographic and physical observations, 360
Roentgen ray, clinical value of roentgenography of temporal bone, 244; visualizing of eustachian tube by, 225

Salivary secretions, observations on, and associated clinical findings, 403
Sarcoma of the eyelid, 89
Scarlet fever, otitis mastoiditis, method of handling at Philadelphia Hospital for contagious diseases, 252; otitis: report of sixty-six cases, 233
Sinus thrombosis, cerebellar abscess, meningitis: recovery after opening cisterna pontis, 261
Sinuses, abscess of frontal lobe following sinus disease, 380; bronchiectasis associated with disease of nasal accessory sinus, 499; catarrhal inflammation of nasal accessory sinuses and its diagnosis, 351; chronic focal infection of tonsils and accessory sinuses in adults, 415; endonasal treatment of an ethmoid-frontal mucocele, 377; experience with orbito-ethmoidal osteomata having intracranial complications, 378; foreign bodies in the accessory sinuses, 376; indications for radical frontal sinus operation with report on case, 365; infection of accessory nasal sinuses: as cause of chronic nontuberculous bronchitis, 356; infection of paranasal sinus and swimming, 358; injection of iodized oil into sinuses, with special reference to the technic in the sphenoidal sinuses, 351; intracranial complications of skull fracture, involving frontal sinus, 383; intranasal ethmoid and frontal sinus operation, 370; iodipin in the diagnosis of nasal sinus conditions, 349; local administration of bacterial vaccines in treatment of subacute and chronic nasal sinus conditions, 367; local anesthesia in external operations on nasal accessory sinuses, 371; osteoma of frontal, maxillary and sphenoid sinuses, 381; pathologic examination in cavernous sinus thrombosis, 345; relation of inflammation of maxillary sinus to that of nose and other paranasal sinuses, 359; treatment of antral disease by simple tube drainage, 368
Sinusitis, chronic frontal sinusitis: surgical treatment, 363; diagnosis of chronic maxillary sinusitis: comparative value of roentgenographic and physical observations, 360; retrobulbar neuritis associated with sphenoidal and ethmoidal sinusitis, 143; tissue hydration and its relation to susceptibility and immunity, as shown by skin tests in asthma, chronic sinusitis and other infections, 317; two-stage operation for suppurative frontal sinusitis with external manifestations, 373
Skin, inflammation, intractable forms of dermatitis of external ear in cases of chronic suppurative otitis media, 219; inflammatory affections of skin of external ear, 220; tests, tissue hydration and

its relation to susceptibility and immunity, as shown by skin tests in asthma, chronic sinusitis and other infections, 317; utilization of upper eyelid for repair of small facial defects, 346
Skull fracture, intracranial complications of, involving frontal sinus, 383
Slit-lamp, ophthalmology, 33
Speech and voice disorders, 472; dysphonia, its significance and management, 479; improvement of speech in cleft palate cases, preliminary paper, 474; new auxiliary measure to create head resonance in singers and speakers, 476; postadenoidal, 476; relation or oral articulative movements of speech and of extrinsic laryngeal musculature in general to function of vocal cords, 480; stammering as a psychoneurosis: plea for corrective measures, 472; stuttering: cause and cure, 472; surgical treatment of paralysis of vocal cord and of diaphragm, 482
Squint (see Strabismus)
Stovain (see Anesthesia)
Strabismus, general practitioner and the child with squint, 79; causes of concomitant strabismus, 68; mechanical exactness in operating for strabismus, 70; practical assistance in correcting the commonest type of squint, 78
Streptococcus, chronic hypertrophy of lower lip, 402
Sugar, treatment of tonsilitis with sugar, 431
Swimming, paranasal sinus infection, 358
Syphilis, chancre of nasal septum: three cases, 390; contra-indications in arsenical treatment of syphilis, 188
Therapeutics, protein-body therapy in chronic eczema of ear, 219; tuberculosis of middle ear, with especial reference to heliotherapy, 237
Throat, experimental sore throat, 444; further investigation concerning changes in lymph follicles in angina lacunaris, 419; nasopharyngeal atresia, 452; observations of nose and throat in examination of patients with bronchial asthma, 328; pathologic anatomy of malignant tumors of nasopharynx, 451; pemphigus of, 445; peroral endoscopy: use in complications following operations on nose and throat, 488; relation of asthma to nose and throat surgery, 323; retropharyngeal (tonsillar) myxosarcoma observed during twenty-two years, 447; scirrus carcinoma of throat, 445; some neurologic complications of ear, nose and throat, 299; torula infection of nasopharynx, 448; training in otolaryngology, 311; use of foreign bodies in ear, nose and throat surgery, 345
Thymus gland, 343
Thyroid, vertigo and deafness associated with hypothyroidism, 297
Tic douloureux cured by mastoidectomy, 286
Tongue, lesions of, with special reference to their location, 410
Tonsils, biochemistry of, 412; chronic focal infection of tonsils and accessory sinuses in adults, 415; hemorrhage following removal of tonsils and adenoids, 432; irradiation of diseased tonsils, 429; retropharyngeal (tonsillar) myxosarcoma observed during twenty-two years, 447;

some phases of tonsil problem, 420; treatment of diseased tonsils by means of radium, 430
Tonsilitis, chronic, 413; localization and diagnosis of foci of chronic infection in chronic tonsilitis, 414; treatment of, with sugar, 431
Tonsillectomy, bronchoscopic and esophagoscopic observations in, 502; coagulation time prior to, 416; electrocoagulation as an adjunct in tonsil dissections, 443; injurious results frequently following tonsillectomy, 427; in nephritis, 423; in singers, 424; ligature-carrying tonsillar hemostat, 439; method which insures practical control of hemorrhage in connection with the operation of tonsillectomy, 433; Molt and Storz modification of tonsil guillotine, 443; new instrument producing a bloodless tonsillectomy, 437; postoperative leucocytosis and temperature variations following tonsillectomy, 426; subtotal, 425; technic of tonsil electrocoagulation (diathermy), 440
Torula (see Throat)
Toxemia, acute, ocular fundus in acute toxemias, 150
Trachea, manifestation of uremia in pharynx, larynx, trachea and bronchi, 313; membranous-laryngitis and tracheobronchitis (nondiphtheritic), 463; permanent use of tracheotomy tube, 471
Trochoma, prophylaxis and treatment of ophthalmia neonatorum, 104; treatment of, 94
Tuberculosis, chronic otitis media in the tuberculous, 235; diagnosis and treatment of laryngeal tuberculosis, 461; light treatment of laryngeal tuberculosis, 462; of larynx, 460; of middle ear, with especial reference to heliotherapy, 237; of nasal fossae, 394; trichloracetic acid in treatment of ulcerative laryngeal tuberculosis, 459
Tumor, carcinoma of mouth: types and degrees of malignancy, 409; erosion of petrous bone by acoustic nerve tumor, 271; experience with orbito-ethmoidal osteomata having intracranial complications, 378; hemangioma of orbit, 145; intranasal radium therapy in malignant and benign tumors, 393; is radium a cure for cancer of larynx? inquiry based on study of end-results, 466; of temporal bone, contributions to clinical signs and histology of malignant tumors of temporal bone, 270; osteoma of frontal, maxillary and sphenoid sinuses, 381; pathologic anatomy of malignant tumors of nasopharynx, 451; peculiarities and possibilities of surgical removal of neuromas of acoustic nerve, 279; primary carcinom of the bronchi, 501; ranula, 404; retropharyngeal (tonsillar) myxosarcoma observed during twenty-two years, 447; scirrus carcinoma of throat, 445; sarcoma of the eyelid, 89; treatment of carcinoma of esophagus: based on 100 personal cases and 18 postmortem reports, 506
Turbinates (see Nose)
Tutocain (see Anesthesia)

Ulcers of the cornea due to bacillus pyocyaneus, 111; trichloracetic acid in treatment of ulcerative laryngeal tuberculosis, 459

Uremia, manifestations of uremia in pharynx, larynx, trachea and bronchi, 313
Uveal tract, 149

Vaccines, local administration of bacterial vaccines in treatment of subacute and chronic nasal sinus conditicns, 367
Vaccinotherapy in otolaryngology, 314
Vertigo and deafness associated with hypothyroidism, 297; propulsion, 277
Vision, field of, the recording of perimetric tracings, 57; influence of, on vestibular turning and after-nystagmus, 280
Voice and speech disorders, 472; dysphonia, its significance and management, 479; improvement of speech in cleft palate cases, preliminary paper, 474; new auxiliary measure to create head resonance in singers and speakers, 478; postadenoidal speech, 476; relation of oral articulative movements of speech and of extrinsic laryngeal musculature in general to function of vocal cords, 480; stammering as a psychoneurosis: plea for corrective measures, 472; stuttering: cause and cure, 472; surgical treatment of paralysis of vocal cord and of diaphragm, 482; technic for voice test of hearing, 212

Wound, cicatricial (benign) stricture of the esophagus; tabulated report of 186 cases, 505

INDEX OF AUTHORS

Adkins, G. E., 253
Albrecht, W., 388
Anderson, C. M., 373
Anderson, E. E., 291
Atkins, R. T., 365

Bagley, C. H., 198
Bailey, Hamilton, 39
Ballance, C., 482
Barlow, R. A., 403
Beinhauer, L. G., 402
Bendove, Raphael A., 235
Benedict, W. L., 86
Benési, O., 300
Berens, Conrad, 198
Bishop, V. L., 326
Black, Melville, 127
Blau, 261
Bloodgood, J. C., 406
Bordier, H., 318
Boyce, W. A., 37
Boynton, W. E., 70
Braswell, J. C., 347
Broders, A. C., 409
Brown, Albert I., 150
Brown, E. V. L., 120
Bruenings, 301
Burch, Frank E., 16

Cantor, J., 494
Chapman, S. J., 237
Cheatle, A. H., 273
Clerf, L. H., 499, 500, 503
Coates, G. M., 311
Coelst, M., 306
Colledge, L., 482
Comenge, R., 132
Cordes, Frederick C., 193

Cosgrove, K. W., 111
Costen, J. B., 234
Cunningham, O. D., 333
Curry, G. E., 145
Cushing, H., 378

Daily, L., 502
Daily, R., 502
Daland, J., 314, 415
Daraban, E., 425
Davies, B. C., 459
Dick, G. F., 444
Dick, G. H., 444
Dillinger, G. A., 440
Dintenfass, H., 248, 258
Dixon, Cyril, 139
Dixon, O. J., 345
Drury, D. W., 293
Duane, Alexander, 59
Durham, R., 399

Eagleton, W. P., 262
Eckert, Moebius, 386
Eden, G., 342
Edwards, J. F., 40
Ellett, E. C., 44, 180
Erehart, M. G., 186

Farr, R. E., 401
Faught, F. A., 319
Fergus, Freeland, 57
Fetterolf, G., 320
Finnoff, W. C., 91
Firestone, F., 316
Fisher, W. A., 30
Fitzwilliams, D. C., 404
Fletcher, H., 209
Flynn, J., 143
Foote, J. A., 426
Fowler, E. P., 209
Fox, J. C., 81
Fox, N., 312
Franklin, Walter Scott, 193
Fraser, J. S., 257, 280
Friedenwald, Jonas S., 200
Froeschels, E., 478
Fulton, J. F., 121
Funk, E. H., 501

Garretson, W. T., 381
Gautier, P., 228
Gill, E. G., 363

Gittins, T. R., 463
Glassburg, J. A., 472, 476
Goodyear, H. M., 349
Gottlieb, M. J., 340
Gowen, F. V., 252
Gray, A. M., 220
Greig, D. M., 447
Griessmann, D.
Gyergyay, Von, 300

Harkness, G. F., 202
Harman, Bishop, 96
Harris, M. L., 388
Harris, R., 371
Harris, T. J., 466
Hart, V. K., 79
Hasty, F. E., 358
Hays, H., 367
Heckel, A. B., 204
Heetderks, D. R., 312
Heitger, J. D., 359
Herman, F. P., 437
Herzog, H., 301
Heymann, E., 272
Hirsch, O., 351
Holmes, G., 81
Hoople, G. D., 387
Hunt, W. M., 416
Hurwitz, S. H., 327

Jackson, C., 501
Jenkins, G. J., 255
Jesberg, S., 494
Johnson, H. P., 360
Johnston, W. H., 396
Jones, D. H., 467
Jones, E. Lloyd, 448

Keen, J. A., 227
Kenyon, E. L., 480
Key, S. N., 390
Khanka, Daljang Singh, 129
King, Ossian H., 188
Kingsley, Frederick, 78
Kirkham, H. L., 474
Kistner, F. B., 356
Koenigsberger, E., 431
Kopetzky, S. J., 246, 291

Lane, Laura A., 191
Lawrence, C. H., 296
Lawson, Sir Arnold, 137

Leary, T. G., 472
Lebensohn, J. E., 109
Lefler, A. B., 233
Lemere, H. B., 203
Lenscher, E., 285
Leopold, S. S., 320, 331
Leshure, J., 336
Lewis, F. Park, 169
Lierle, D. M., 229
Lillie, H. I., 373
Lobell, A., 351
Logan, W. H., 398
Looper, E. A., 461
Lowell, W. Holbrook, 25
Luescher, E., 412
Lussmann, Francis J., 235

MacAuliffe, G. B., 260
MacCallan, A. F., 98
McCrae, T., 501
MacFarlan, D., 212
MacKenty, J., 452
Mackenzie, G. W., 274, 283
Macklin, Madge Thurlow, 1
McKesson, E. I., 469
McKinney, R., 418
McNally, W. J., 432
McReynolds, J. O., 159
Magnien, P. L., 244
Magnus, Vilhelm, 82
Maliniak, J., 347
Mandelbaum, M. J., 255
Mann, Ida, 30
Mercer, R. E., 368
Merkel, C. C., 332
Miller, T. G., 331
Mills, Lloyd, 153
Mitchell, L. J. C., 139
Mithoefer, W., 420
Moehlig, R. C., 297
Moeller, J., 307
Molt, W. F., 443
Moore, S. G., 116
Moreau, N., 380
Morgan, A. M., 68
Mosher, H. P., 498
Muecke, F., 334
Mussliner, S., 431
Myerson, M. C., 313

Negus, V. E., 273
Nelson, R. F., 413
Neumann, H., 250
Nippe, L., 171
Nylen, C. O., 278

Ohm, J., 280
Omerod, F. C., 219
Owen, M., 410

Patterson, E. J., 493
de Parrel, G., 304
Pilcher, J. D., 337
Plum, A., 462
Pollock, H. L., 345, 886
Portman, G., 380

Rea, 118
Reaves, R. G., 354
Retrouvey, H., 394
Rice, C. C., 427
Richardson, Shaler, 114
Rockwood, R., 291
Ross, E. L., 333
Rossier, 377
Rowe, A. H., 325
Rowe, A. W., 387
Roy, Dunbar, 89
Roy, J. N., 397
Rubenstein, A. H., 298, 445
Ruf, 414
Ruf, C., 270
Ruff, 268

Scal, J. C., 429, 430
Schirmunsky, M., 223
Schugt, H. P., 460
Schwyzer, A., 468
Seigrist (of Berne), 174
Selinger, M., 426
Shambaugh, G. E., 289
Sheehan, J. E., 346
Shugrue, J. J., 291
Simpson, W. L., 371
Singer, L., 451
Smith, A. J., 439
Smith, J. M., 285
Sonnenschein, R., 207
Souttar, H. S., 506
Spielberg, W., 225, 370
Stammers, F. A. R., 216
Stanford, J. B., 175
Sterling, A., 323
Stern, 243, 424

Sternberg, H., 219
Stevenson, H. M., 296
Stieren, Edward, 184
Stout, P. S., 328

Taylor, S., 332
Taylor, W. H., 443
Teachenor, F. R., 383
Thomson, St. Clair, 471
Törne, F. W., 423
Towne, E. E., 271
Tucker, G., 488, 495, 497
Turner, A. L., 280

Van Meter, E. R., 393
Vasilin, D., 224
Veits, C., 217
Vinson, P. P., 505
Von der Heydt, 34, 36, 133
Voorsanger, W. C., 316

Waldapfel, R., 419
Warwick, H. L., 296
Wasson, W. W., 343
Watson, W. R., 445
Weisenburg, T. H., 299
Weiss, Louis, 104
Wells, W. A., 433
Wharry, H. M., 455
Wherry, W. B., 317
White, Leon E., 140, 338, 375
Whitehead, A. L., 137
Wieder, H. S., 286
Wilkinson, Herbert J., 118
Williamson, G. S., 240
Wilson, M. B., 376
Wiskovsky, B., 486
Wolf, G. D., 479
Woods, R., 400
Wright, R. E., 133

Yankauer, S., 490
Yates, A. L., 342
Yearsley, M., 304

Zeisler, E. P., 390
Zentmayer, 149

616.21 Y39 1927

a39001 007272019b

616.21
39
27

651